



**HAL**  
open science

## Detection of infectious agents in equine pregnancy loss, stillbirth and neonatal death

V. Saey, H. van Loo, A. Gryspeerdt, Stéphane Pronost, F. Gasthuys, K. Rosiers, D. Cassart, J. Govaere

### ► To cite this version:

V. Saey, H. van Loo, A. Gryspeerdt, Stéphane Pronost, F. Gasthuys, et al.. Detection of infectious agents in equine pregnancy loss, stillbirth and neonatal death. *Vlaams dierengeneeskundig tijdschrift*, 2023, 92 (2), 10.21825/vdt.86337 . hal-04295396

**HAL Id: hal-04295396**

**<https://normandie-univ.hal.science/hal-04295396v1>**

Submitted on 20 Nov 2023

**HAL** is a multi-disciplinary open access archive for the deposit and dissemination of scientific research documents, whether they are published or not. The documents may come from teaching and research institutions in France or abroad, or from public or private research centers.

L'archive ouverte pluridisciplinaire **HAL**, est destinée au dépôt et à la diffusion de documents scientifiques de niveau recherche, publiés ou non, émanant des établissements d'enseignement et de recherche français ou étrangers, des laboratoires publics ou privés.

## Detection of infectious agents in equine pregnancy loss, stillbirth and neonatal death

*Detectie van infectieuze agentia bij abortus, doodgeboorte en neonatale sterfte bij het paard*

<sup>1</sup>V. Saey, <sup>2</sup>H. Van Loo, <sup>3</sup>A. Gryspeerdt, <sup>4</sup>S. Pronost, <sup>5</sup>F. Gasthuys, <sup>1</sup>K. Rosiers, <sup>6</sup>D. Cassart, <sup>2</sup>J. Govaere

<sup>1</sup>Animal Health Care Flanders (DGZ), Site Torhout, Industrielaan 29, 8820 Torhout, Belgium

<sup>2</sup>Department of Internal Medicine, Reproduction and Population Medicine, Faculty of Veterinary Medicine, Ghent University, Salisburylaan 133, B-9820 Merelbeke, Belgium

<sup>3</sup>Equi Focus Point Belgium, Diksmuidseweg 105, B-8900 Ieper

<sup>4</sup>LABEO Frank Ducombe, Normandie University, UNICAEN BIOTARGEN, Rue de Saint Contest 1, 1400 Caen, France.

<sup>5</sup>Department of Surgery and anesthesiology of domestic animals, Faculty of Veterinary Medicine, Ghent University, Salisburylaan 133, B-9820 Merelbeke, Belgium

<sup>6</sup>Department of Morphology and Pathology, Faculty of Veterinary Medicine, Université de Liège, Boulevard de Colonster 20, 4000 Liège, Belgium

verosaey@hotmail.com

## ABSTRACT

Equine abortion, stillbirth and neonatal death cause major economic losses to the equine industry worldwide. Both non-infectious and a wide range of infectious causes have been described. However, the relative contribution of pathogens to equine abortion, stillbirth and neonatal death is poorly documented, since available studies involve only a limited number of pathogens. Therefore, the objectives of the present retrospective monitoring study were to determine the prevalence of infectious agents associated with equine abortion and perinatal mortality in Belgium, and to set up a protocol usable under field conditions using polymerase chain reaction targeting. A real-time simple polymerase chain reaction for eight different abortifacient pathogens was conducted leading to the detection of at least one infectious agent in 37% of 105 analyzed cases. In the diagnosed cases, equine herpesvirus-1 was the most detected pathogen (49%), followed by *Streptococcus equi subspecies zooepidemicus* (28%), *Coxiella burnetii* (18%), *Leptospira interrogans* (3%) and *Neospora caninum* (3%). None of the analyzed cases was positive for equine viral arteritis, equine herpesvirus-4 and *Chlamydophila* spp.

In this study, PCR targeting is shown to have its value to detect a (co)-infectious cause in equine abortion, stillbirth and neonatal death, especially in field conditions where autolysis and contamination might preclude a full post-mortem examination protocol based on classical microbiological examination.

## SAMENVATTING

Abortus, doodgeboorte en neonatale sterfte bij de merrie veroorzaken jaarlijks wereldwijde economische verliezen. Zowel infectieuze als niet-infectieuze oorzaken worden beschreven in de literatuur. Het relatieve belang van de verschillende pathogenen bij abortus, doodgeboorte en neonatale sterfte bij het paard is echter onduidelijk, aangezien in de meeste studies slechts een beperkt aantal pathogenen onderzocht werd. Daarom waren de doelstellingen van deze retrospectieve monitorings-

studie om de prevalentie van acht infectieuze oorzaken van abortus en perinatale sterfte bij het paard in België te bepalen en ten tweede om een onder veldomstandigheden bruikbaar “polymerase-chain-reaction” protocol op te stellen. Een “real-time polymerase chain reaction” voor acht pathogenen geassocieerd met abortus/perinatale sterfte bij het paard werd uitgevoerd bij 105 gevallen. In 37% van de gevallen werd tenminste één infectieus agens gedetecteerd, met als koploper equine herpesvirus-1 (49%) gevolgd door *Streptococcus equi subspecies zooepidemicus* (28%), *Coxiella burnetii* (18%), *Leptospira interrogans* (3%) en *Neospora caninum* (3%). Equine viral arteritis, Equine herpesvirus-4 and *Chlamydophila spp.* werden niet gedetecteerd.

In deze studie wordt aangetoond dat PCR nuttig kan zijn om een co(-infectieuze) oorzaak van abortus, doodgeboorte of neonatale sterfte bij het paard te detecteren, vooral in praktijkomstandigheden waarbij autolyse en contaminatie een uitgebreid post-mortemprotocol met klassieke microbiologische analyses kunnen verhinderen.

## INTRODUCTION

Equine abortion, stillbirth and neonatal death (ASND) are major problems in the horse industry as they cause great economical and emotional losses worldwide (Bosh et al., 2009; Parameswaran and Senthil, 2014). Spontaneous abortion in horses is defined as pregnancy loss prior to three hundred days of gestation. Fetuses dying after three hundred days of gestation are conventionally termed as stillbirths, since foals born from that time on may be capable to survive (Acland, 1993). Cases of foals that die within two days after birth are classified as neonatal death.

Both infectious and non-infectious causes involved in equine ASND have been reported worldwide (Bain et al., 1969; Giles et al., 1993; Smith et al., 2003; Léon et al., 2006; Léon et al., 2012), but regional differences highlight the importance of local, systematic monitoring. In Belgium, limited information exists on the prevalence of equine causes of ASND.

Continuous surveillance of ASND in horses is important as some disorders, e.g. equine herpesvirus-1 (EHV-1) infections (Damiani et al., 2014) and the mare reproductive loss syndrome (MRLS) (Sebastian et al., 2008), require immediate preventive measures, encouraging laboratories to focus on specific infectious causes. However, examination is often challenging, especially under field conditions. Cases of ASND often show extensive post-mortal decay or autolysis, which hampers routine bacteriological and histological examination. Moreover, some pathogens are difficult to detect because of an intracellular location, e.g. *N. caninum* and *C. burnetii*, or a strenuous culture protocol (*Leptospira*). This underlines the importance of the use of PCR assays.

The aims of this study were (1) to determine the prevalence of the most important infectious causes of equine abortion, stillbirth and neonatal death in Belgium, and (2) to study the possible value of a panel of real-time polymerase chain reaction tests in the detection of infectious agents in equine abortion, stillbirth and neonatal death.

## MATERIALS AND METHODS

### Sample population

Between February 2015 and June 2017 (time period determined by availability of funding), a total of 133 cases (128 abortions/stillbirths, and 5 neonatal deaths) in different horse breeds (predominantly warmbloods) in Belgium (95 in Flanders, 38 in Wallonia) were declared by the owner. Within 24 hours of case declaration, the fetus and, in the majority of cases, corresponding fetal membranes and umbilical cord, or fetal organs were collected by the veterinarian and transported to the laboratory of Animal Health Services Flanders (DGZ Vlaanderen) or the Faculty of Veterinary Medicine of the University of Liège. The location of referral depended only on the location where the ASND case happened (DGZ Vlaanderen for Flanders; University of Liège for Wallonia).

From the initial 133 cases, 28 cases were excluded because of incompleteness of submitted material, resulting in a final study population of 105 cases (Figure 1).

### Necropsy protocol

Processing of the fetus/foal was performed within 24 hours after arrival at the laboratory facilities. At necropsy, the fetus/foal was weighed, placed in right-sided recumbency and the crown-rump length (cm) was measured. In cases where no gestational length was known, the gestational length was calculated based on fetal crown-rump length, as described by McGeady et al. (2017).

The fetus/foal, umbilical cord and placenta were checked for macroscopic abnormalities. The thoracic and abdominal cavities were cut-opened, followed by tissue sampling of the lung and liver. The skull was disarticulated at the atlantooccipital joint followed by sagittal dissection and tissue sampling of the brain. Finally, the placenta underwent tissue sampling.

All samples were separately packed and sent under

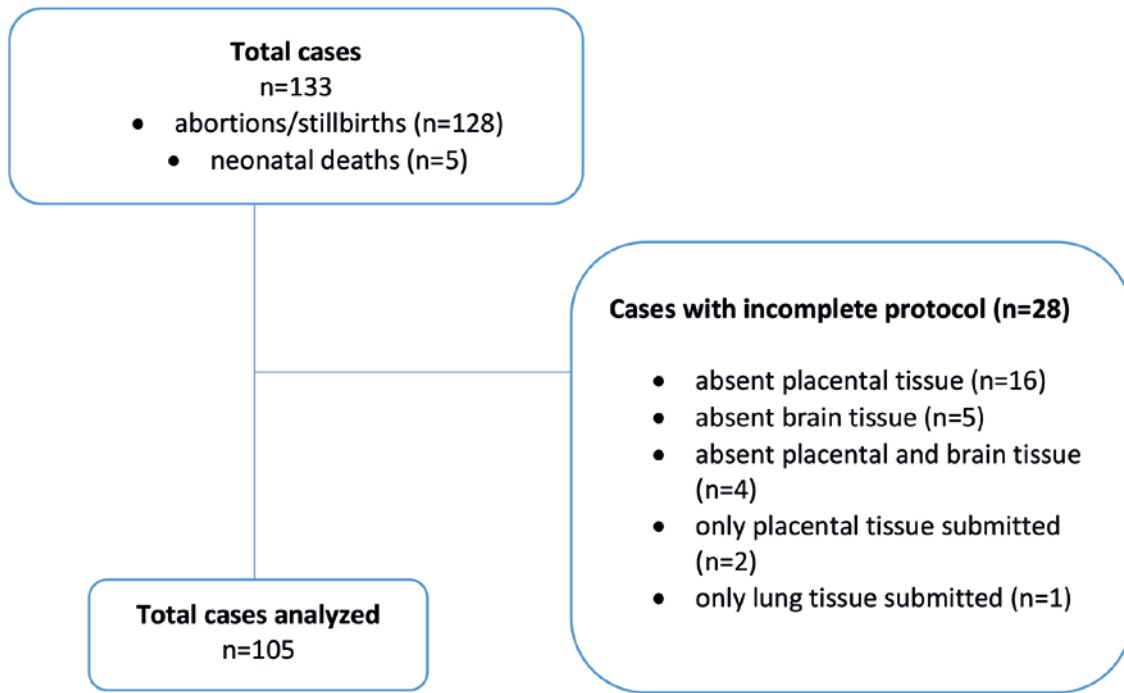


Figure 1. Flow chart showing the initial and final study population and the reasons of exclusion.

cooled conditions (4°C) to LABÉO (Caen, France) for PCR examination.

### Molecular analysis

The presence of EHV-1, equine herpesvirus-4 (EHV-4), equine viral arteritis (EVA), *Lepstospira interrogans* (*L. interrogans*), *Streptococcus equi* subspecies *zooepidemicus* (*S. zooepidemicus*), and *Coxiella burnetii* (*C. burnetii*) was systematically investigated by a simple real-time PCR on a pool sample of liver and lung tissue. The real-time PCR for the detection of *Neospora caninum* (*N. caninum*) and *Chla-*

*mydophila* spp. (*Chlamydophila abortus*, *psittaci* and *pecorum*) was performed on brain and placenta, respectively. Nucleic acids of the collected organs were extracted using the Qiagen (QIAamp DNA/RNeasy mini kits) procedure according to the manufacturer's instructions. The real-time PCR tests were performed according to previously described procedures (Léon et al., 2006; Diallo et al., 2007; Pronost et al., 2010; Léon et al., 2012; Pronost et al., 2012).

### RESULTS

The majority of analyzed cases (66%) happened between the 7<sup>th</sup> and 10<sup>th</sup> month of gestation (range 3-11 months). Forty percent of the analyzed cases were abortions, 57% were stillbirth cases (>300 days of gestation), while 3% of the cases were neonatal deaths.

In 35% of the analyzed cases (37/105), an infectious agent could be detected. In 65% (68/105) of the cases, no infectious agent was detected, nor was there an apparent cause of abortion seen.

### Viral infection

The main infectious agent that could be detected was EHV-1. This virus was present in 49% of the diagnosed cases (19/39). In 58% of the EHV-1 positive cases (11/19), post-mortem examination revealed lesions such as icterus, and an enlarged liver with or without pinpoint necrotic foci was noticed (Figure 2).

No cases were positive for EVA.

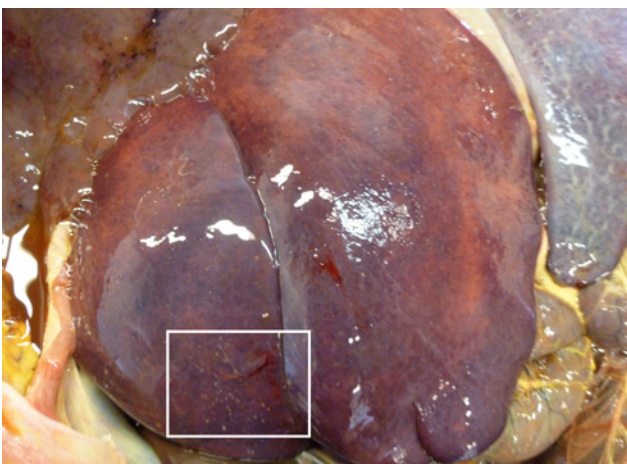


Figure 2. Enlarged liver with white necrotic foci on the capsular surface (rectangular) of an aborted foal diagnosed with EHV-1. These typical lesions were only seen in half of EHV-1 positive cases.

## Bacterial infection

In 28% of the diagnosed cases (11/39), *S. zooepidemicus* was detected. *Coxiella burnetii* was detected in 18% of the diagnosed cases (7/39). In two of these *C. burnetii* positive cases, a co-infection was noticed (one with *S. zooepidemicus*; one with EHV-1). Only one case was positive for *Leptospira interrogans* (3%; 1/39), and no cases were positive for *Chlamydomphila spp.*

## Parasitic infection

Three percent of the diagnosed cases (1/39) was positive for *N. caninum*.

## Non-infectious

In 4% of the analyzed cases (4/105), umbilical cord strangulation was present.

The results of the diagnostic analyses and the sampled tissues are summarized in Table 1.

In 5.7% of the analyzed cases (6/105), a presumptive diagnosis of placentitis was made based on gross abnormalities, such as thickening, edema and discoloration. However, no infectious agents could be detected in these cases.

## DISCUSSION

This is the first overall survey in Belgium with the objective to establish an epidemiologic insight into equine ASND. In 37% of the analyzed cases (39/105), an infectious agent was detected.

In most large-case studies on aborted foals focusing on well-known pathogens causing abortion in horses (EHV-1 and *S. zooepidemicus*), standard microbiological, fungal examination, and viral isolation are used. In these surveys, prevalences of infectious causes of abortion ranging from 12% (Ricketts et al., 2003) to 20% (Smith et al., 2003) have been reported.

Léon et al. (2012) were the first to investigate an extensive panel of abortifacient pathogens (EHV, EVA, *S. zooepidemicus*, *Leptospira*, *C. burnetii*, *N. caninum* and *C. abortus*) in French horses using molecular analysis, resulting in a diagnostic rate of 27%. Szeregi et al. (2008) also used PCR to target EHV-1 and *C. abortus* in aborted foals. The higher diagnostic rate in the present study may be the result of the use of molecular analysis, or the higher prevalence of some of the analyzed pathogens. Additionally, the higher detection of infectious agents may also be caused by submission bias. Horse owners and their veterinarians may be more motivated to submit ASND cases for laboratory analysis when infectious causes are suspected.

In the present study, EHV-1 was the leading cause of equine ASND, similar to reports worldwide throughout all stages of pregnancy (Macleay et al., 2022). Both EHV-1 and EHV-4 are endemic in horses worldwide, but regional differences exist (Allen et al., 1999; Yildirim et al., 2015). In the UK, EHV was detected in 7% of aborted foals (Ricketts et al., 2001; Smith et al., 2003). The large majority of these cases represented an EHV-1 infection (>90%) which corresponds with other studies (Patel and Heldens, 2005). In France, Léon et al. (2012) identified EHV-1 infection in 8.8% of aborted foals. These percentages are low compared to the present study, which suggests a higher circulation of EHV-1 in Belgium than in some other countries. Belgium is known for its important role in equine breeding, and it is also a popular equestrian sports country. Consequently, there is a higher chance of direct contact between animals, which may lead to new outbreaks of EHV-1, as already shown in the past (Carvelli et al., 2022). In other important horse breeding areas, such as the USA and UK, EHV-1 positive cases have declined over time, which was attributed to a combination of vaccination and improved risk reduction (Macleay et al., 2022). The higher number of EHV-1 positive cases in the present study could be the result of the fact that the involved veterinarian might have been more inclined to refer

**Table 1. Results of diagnostic analyses in 105 cases of equine abortion, stillbirth and neonatal death. In 37% of the cases (39/105), at least one infectious abortifacient agent could be detected (= diagnosed cases).**

Pathogen	% positive (n=105)	% positive of diagnosed cases (n=39)	Sample type
EHV-1	18.1	48.7	Fetal/foal liver and lung
<i>S. zooepidemicus</i>	10.5	28.2	Fetal/foal liver and lung
<i>C. burnetii</i>	6.7	17.9	Fetal/foal liver and lung
<i>L. interrogans</i>	1.0	2.6	Fetal/foal liver and lung
<i>N. caninum</i>	1.0	2.6	Fetal/foal brain
<i>Chlamydomphila spp.</i>	0	0	Placenta
EHV-4	0	0	Fetal/foal liver and lung
EVA	0	0	Fetal/foal liver and lung

EHV-1 = equine herpesvirus-1; *S. zooepidemicus* = *Streptococcus equi* subspecies *zooepidemicus*; *C. burnetii* = *Coxiella burnetii*; *L. interrogans* = *Leptospira interrogans*; *N. caninum* = *Neospora caninum*; EHV-4 = equine herpesvirus-4; EVA = equine viral arteritis

only EHV-suspected cases for further investigation. Weber et al. (2018) also used a PCR test to detect infectious causes of abortion, but they found EHV-1/4 in only 9% of abortion cases.

In 7% of the analyzed cases, *C. burnetii* could be detected in liver and lung tissues of the fetus/foal. This prevalence suggests a high circulation of this bacterium in Belgium. Recently, 8.5% of Belgian bovine abortions originating from Wallonia, were tested positive for *C. burnetii* on the basis of a PCR test on a pool of fetal spleen and, if available, placental cotyledons (Saegerman et al., 2022). In Flanders, a percentage of only 1.5 % of bovine cases tested positive for *C. burnetii*. However, in these Flemish cases, only the fetal abomasal content was tested by PCR (Van Loo et al., 2021). Not much literature is available regarding *C. burnetii* infections in horses. A pooled mean seroprevalence of 15.8% has been calculated in horses (Marenzoni et al., 2013). Léon et al. (2012) were the first to report the presence of *C. burnetii* in 1.5% of aborted foals. The placenta is the target organ of *C. burnetii* (Clothier and Anderson, 2016). In the study by Léon et al. (2012), both lung and placental tissues of equine fetuses were tested by PCR. However, it was not specified if there were significant differences in prevalence between both tested organs. In the present study, in 2/7 of the *C. burnetii* positive cases, co-infection was present (one co-infection with EHV-1 and one co-infection with *S. zooepidemicus*). Presuming that this EHV-1 infection was the cause of abortion, the percentage of *C. burnetii* positive ASND cases may be overestimated in the present study. Considering the zoonotic character of *C. burnetii*, extra attention should be paid to this pathogen (Deyell et al., 2006). More studies, including histology and immunohistochemistry, are needed to further unravel the role of this pathogen in equine ASND.

*L. interrogans* is considered to be one of the most widespread zoonosis worldwide (Levett, 2001). Leptospirosis has also been described as a cause of placentitis in horses (Ellis and O'Brien, 1988; Donahue et al., 2000). Moreover, the disease has been documented as the second most common cause of equine abortion in North America (Donahue et al., 1991; Macleay et al., 2022). However, only 4% of equine cases of pregnancy loss positive for leptospirosis worldwide originated from Europe (Macleay et al., 2022). Up till now, no information is available concerning the role of leptospirosis in equine ASND in Belgium. In the present study, only 3% of the diagnosed cases were positive for *L. interrogans*. Differences in density of the horse population and in the presence of wild animal reservoirs may explain the lower prevalence of leptospirosis in our region compared to others.

*Neospora caninum*, an apicomplexa protozoan parasite, is recognized as a major cause of abortion in cattle (Dubey, 2005; Dubey and Schares, 2006; Van Loo et al., 2021). In horses, an association between equine reproductive disorders and *N. caninum* infec-

tion has also been suggested (Villalobos et al., 2006; Veronesi et al., 2008). The number of animals with elevated anti-*Neospora* specific antibodies is higher in aborting mares (Pitel et al., 2003; Kligler et al., 2007). Léon et al. (2012) detected *N. caninum* by molecular analysis in 1% of aborted foals in France. PCR for *N. caninum* was positive in 23% of brain specimen from aborted foals in a study by Veronesi et al. (2008). In the present study, *N. caninum* was detected in only one case in the brain. However, as this parasite is very easily transmitted from infected mother to fetus, it can also be found in cases where *N. caninum* is not the cause of abortion (Dubey and Schares, 2006). Veronesi et al. (2008) also reported infections with *N. caninum* in aborted foals where the abortion event was assumed as primarily caused by EHV-1. Histology was not performed in this study, which could have been useful in order to correlate results of the PCR with the detection of *N. caninum* tachyzoites in fetal tissues (Dubey and Schares, 2006). However, detecting these protozoal agents in brain specimens by histological examination may be challenging (Veronesi et al., 2008).

In the present study, no EVA virus was detected. However, a serological study has shown that 10% of tested horses in Belgium presented specific antibodies to EVA (unpublished data, Lauwers, 1997-1998). In 2000, a severe outbreak of EVA infection happened in a Belgian Arabian stud farm (Van der Meulen et al., 2001). Gryspeerdt et al. (2009) reported also a small outbreak of neonatal death caused by EVA infection in Belgium.

*Chlamydophila abortus*, *C. psittaci* or *C. pecorum* were not detected in this study. There is only limited information available regarding the role of *Chlamydophila spp* in equine abortion. Abortions associated with *C. psittaci* have been reported in both Australia and Europe (France, Germany, Hungary and Switzerland) (Macleay et al., 2022). A high prevalence of *C. psittaci* in equine fetal membranes has been demonstrated in Hungary (Szeredi et al., 2005). Reports based on molecular tests also associated *C. psittaci* with equine abortion (Henning et al., 2000; Telocnik et al., 2018).

Placentitis is known as one of the main causes of infectious ASND in horses (Brinsko et al., 2011). According to a study by Macleay et al. (2022), placentitis accounted for 16% of reported pregnancy loss in mares worldwide. However, this percentage may be an underestimation as the diagnosis of placentitis in most studies is only based on gross placental examination without further cause-specific laboratory tests or histology (Macleay et al., 2022). Histopathology has been described as the standard tool for definitive diagnosis of placentitis (Cummins et al., 2008). Unfortunately, in the present study, no microbiological or histological examination on placental tissue was performed because of autolysis, contamination or scavenger damage in multiple cases. Studies in the

US (Tengelsen et al., 1997) and France (Bain et al., 1996) using microbiologic examination of the placenta, showed an infection by *S. zooepidemicus* in 7% and 24% of equine abortions, respectively.

No analyses were performed to detect nocardioform placentitis. This specific type of placentitis is associated with gram-positive branching actinomycetes. The disease causes episodic abortions and weak neonates in horses, primarily in the USA (Fedorka et al., 2021). However, nocardioform placentitis is rather uncommon in Europe (Cattoli et al., 2004), and therefore, this pathogen was not included in the current study.

Non-infectious conditions such as umbilical cord abnormalities were rarely detected in the present study. In the literature, umbilical cord disorders in horses have been reported with an incidence ranging from 0.8 to 46% (Smith, et al. 2003; Tengelsen et al., 1997; Ricketts et al., 2003; Weber et al., 2018). Macleay (2022) reported umbilical cord torsion mainly in Europe and North America, in both mid and late gestation. In the current study, which included predominantly warmblood foals, 4% of the cases showed umbilical strangulations. Important to mention is that in half of these cases, no infectious pathogen was detected. In the other half of the cases, an infection with *S. zooepidemicus* was diagnosed. During agony, umbilical strangulation can occur, secondary to the primary cause of compromise. Twisted umbilical cords without vascular compromise can often be seen in aborted foals (Vandenplassche and Lauwers, 1986). Umbilical strangulation in this study was only mentioned if edema, congestion or hemorrhage of the cord was present. Umbilical or placental disorders were possibly underestimated in this study due to the submission of incomplete placental tissue specimens and/or the absence of the umbilical cord in multiple cases.

Miscellaneous conditions such as dystocia or twinning could be missed due to the limited availability of history in several cases, and the less likelihood of such cases to be submitted as the main aim of submission to a diagnostic lab is the exclusion of infectious causes. Twin pregnancy was the main cause of non-infectious abortion (21.1%) in the study by Weber et al. (2018). Late-term twin pregnancies are however quite rare in Belgian horses because of routine ultrasonographic examination in early pregnancy.

## CONCLUSION

In this study, the importance of PCR tests is confirmed, as advanced autolysis or strenuous culture protocols are often limiting factors in standard investigation protocols of equine ASND.

EHV-1 was the predominant infectious cause of ASND in Belgian horses, which is comparable to results worldwide. The high prevalence of *S. equi subspecies zooepidemicus* in this study highlights the

importance of molecular analysis for this pathogen in future studies. Given the detection of *C. burnetii* and *Leptospira spp.*, these zoonotic pathogens should be taken into account as possible causes of equine ASND.

As an infectious agent was detected in only 37% of the cases, additional analyses to detect both infectious and non-infectious causes of ASND in horses are required to increase the diagnostic rate.

## REFERENCES

- Acland, H. (1993). Abortion in mares. In: A.O. McKinnon and J.L. Voss, Lea & Febiger, Malvern, Pennsylvania (editors). *Equine Reproduction*. Mosby-Year Book, St. Louis, Michigan, 554-562.
- Allen G.P., Kydd J.H., Slater J.D., Smith K.C. (1999). Advances in understanding of the pathogenesis, epidemiology and immunological control of equine herpesvirus abortion. In: Wernery U., Wade J.A., Mumford J.A., Kaaden O.R. (editors). *Equine Infectious Diseases VIII, Proceedings of the Eight International Conference*. R and W Publications, Newmarket, 129-146.
- Bain A.M. (1969). Foetal losses during pregnancy in the Thoroughbred mare: a record of 2562 pregnancies. *New Zealand Veterinary Journal* 17, 155-158.
- Bosh K.A.; Powell D., Neiberger J.S.; Shelton B., Zent W. (2009). Impact of reproductive efficiency over time and mare financial value on economic returns among Thoroughbred mares in central Kentucky. *Equine Veterinary Journal* 41, 889-894.
- Brinsko, S.P., Blanchard, T.L., Varner, D.D., Schumacher, J., Love, C.C., Hinrichs, K., Hartman, D. (2011). Pregnancy loss. In: P. Rudolph and L. Harms (editors). *Manual of Equine Reproduction*. Third edition, Mosby Elsevier, Maryland Heights, MO, USA.
- Carvelli A., Saxmose Nielsen S., Paillet R., Broglia A., Kohnle L. (2022). Clinical impact, diagnosis and control of Equine Herpesvirus-1 infection in Europe. *European Food Safety Authority (EFSA) Journal, Scientific Report* doi: 10.2903/j.efsa.2022.7230.
- Cattoli G., Vascellari M., Corrb M., Capua I., Mutinelli E., Sells S.F., Donahue. (2004). First case of equine nocardioform placentitis caused by *Crossiella equi* in Europe. *Veterinary Record* 154, 730-731.
- Clothier K. and Anderson M. (2016). Evaluation of bovine abortion cases and tissue stability for identification of infectious agents in California diagnostic laboratory cases from 2007 to 2012. *Theriogenology* 85, 933-938.
- Cummins C., Carrington S., Fitzpatrick E., Duggan V. (2008). Ascending placentitis in the mare: a review. *Irish Veterinary Journal* 61(5), 307-313.
- Damiani A.M., Vries M., Reimers G., Winkler S., Osterrieder N. (2014). A severe equine herpesvirus type 1 (EHV-1) abortion outbreak caused by a neuropathogenic strain at a breeding farm in northern Germany. *Veterinary Microbiology* 172(3-4), 555-562.
- Deyell M.W., Chiu B., Ross D.B., Alvarez N. (2006). Q fever endocarditis: a case report and review of the literature. *Canadian Journal of Cardiology* 2(9), 781-785.
- Diallo I.S., Hewitson G., Wright L.L., Kelly M.A., Rodwell B.J., Corney B.G. (2007). Multiplex real-time PCR for

- the detection and differentiation of equid herpesvirus 1 (EHV-1) and equid herpesvirus 4 (EHV-4). *Veterinary Microbiology* 123, 93–103.
- Donahue J.M., Smith B.J., Redmon K.J., Donahue J.K. (1991). Diagnosis and prevalence of leptospira infection in aborted and stillborn horses. *Journal of Veterinary Diagnostic Investigation* 3, 148-151.
- Donahue J.M., Williams N.M. (2000). Emergent causes of placentitis and abortion. *Veterinary Clinics of North America: Equine Practice* 16(3), 443-456.
- Dubey J.P. (2005) Neosporosis in cattle. *Veterinary Clinics of North America: Food Animal Practice* 21, 473-483.
- Dubey J.P., Schares G. (2006). Diagnosis of bovine neosporosis. *Veterinary Parasitology* 140, 1-34.
- Ellis W.A., O' Brien J.J. (1988). Leptospirosis in horses. In: *Proceedings of the Fifth International Conference of Equine Infectious Disease*. Lexington, KY, 168.
- Erol E., Sells S.F., Williams N.M., Kennedy L., Locke S.J., Labeda D.P., Donahue J.M., Carter C.N. (2012). An investigation of a recent outbreak of nocardioform placentitis caused abortions in horses. *Veterinary Microbiology* 158(3), 425-430.
- Fedoroka C.E., Scoggin K.E., Ruby R.E., Erol E., Ball B.A. (2021). Clinical, pathologic, and epidemiologic features of nocardioform placentitis in the mare. *Theriogenology* 171, 155-161.
- Giles R.C., Donahue J.M., Hong C.B., Tuttle P.A., Petrites-Murphy M.B., Poonacha K.B., Roberts A.W., Tramontin R.R., Smith B., Swerczek T.W. (1993). Causes of abortion, stillbirth and perinatal deaths in horses: 3527 cases (1986-1991). *Journal of the American Veterinary Medical Association* 203, 1170-1185.
- Gryspeerd A., Chiers K., Govaere J., Vercauteren G., Ducatelle R., Van de Walle G.R., Nauwynck H.J. (2009). Neonatal foal death due to infection with equine arteritis virus in Belgium. *Vlaams Diergeneeskundig Tijdschrift* 78, 189-193.
- Henning K., Sachse K., Sting R. (2000) Demonstration of Chlamydia from an equine abortion. *Deutsche Tierärztliche Wochenschrift* 107(2),49-52.
- Hue E.S., Fortier C.I., Laurent A., Quesnelle Y., Fortier G.D., Legrand L.J., Pronost S. (2015). Development and validation of a quantitative PCR method for equid herpesvirus-2 diagnostics in respiratory fluids. *Journal of Visualized Experiments* 109, 53-67.
- Hussey S.B., Clark R., Lunn K.F., Breathnach C., Soboll G., Whalley J.M., Lunn D.P. (2006). Detection and quantification of equine herpesvirus-1 viremia and nasal shedding by real-time polymerase chain reaction. *Journal of Veterinary Diagnostic Investigation* 18(4), 335-342.
- Jelocnik M., Jenkins C., O' Rourke B., Barnwell J, Polkinghorne A. (2018). Molecular evidence to suggest pigeon-type Chlamydia psittaci in association with an equine foal loss. *Transbound Emerging Diseases* 65(3), 911-915.
- Kligler E.B., Shkap V., Baneth G., Mildenberg Z., Steinman A. (2007). Seroprevalence of Neospora spp. among asymptomatic horses, aborted mares and horses demonstrating neurological signs in Israel. *Veterinary Parasitology* 148(2),109-113.
- Léon A., Pronost S., Tapprest J., Foucher N., Blanchard B., André-Fontaine G., Laugier C., Fortier G., Leclercq R. (2006). Identification of pathogenic Leptospira strains in tissues of a premature foal by use of polymerase chain reaction analysis. *Journal of Veterinary Diagnostic Investigation* 18, 218-221.
- Léon A., Richard E., Fortier C., Laugier C., Fortier G., Pronost S. (2012). Molecular detection of Coxiella burnetii and Neospora caninum in equine aborted fetuses and neonates. *Preventive Veterinary Medicine* 104(1-2), 179-183.
- Levett P.N. (2001) Leptospirosis. *Clinical Microbiology Review* 14, 296-326.
- Macleay C.M., Carrick J., Shearer P., Begg A., Stewart M., Heller J., Chicken C., Brookes V.J. (2022). A scoping review of the global distribution of cause and syndromes associated with mid- to late-term pregnancy loss in horses between 1960 and 2020. *Veterinary Science* 9(4), 186; <https://doi.org/10.3390/vetsci9040186>.
- Marenzoni M.L., Stefanetti V., Papa P., Casagrande Proietti P., Bietta A., Coletti M., Passamonti F., Henning K. (2013). Is the horse a reservoir or an indicator of Coxiella burnetii infection? Systematic review and biomolecular investigation. *Veterinary Microbiology* 167(3-4), 662-669.
- McGeady T.A., Quinn P.J., Fitzpatrick E.S. (2017). Age determination of the embryo and foetus. In: *Veterinary Embryology*. Second edition, Blackwell Publishing, Oxford, 26, 331-332.
- Parameswaran T. and Senthil N.R. (2014). Analysis of economic loss due to Equine Herpes Viral infection. *International Journal of Advanced Veterinary Science and Technology* 3(1), 134-139.
- Patel J.R., Heldens J. (2005). Equine herpesviruses 1 (EHV-1) and 4 (EHV-4) – epidemiology, disease and immunoprophylaxis: a brief review. *The Veterinary Journal* 170, 14-23.
- Pitel P.H., Romand S., Pronost S., Foucher N., Gargala G., Maillard K., Thulliez P., Collobert-Laugier C., Tainturier D., Fortier G., Ballet J.J. (2003). Investigation of Neospora sp. antibodies in aborted mares from Normandy, France. *Veterinary Parasitology* 18(1-2), 1-6.
- Pronost S., Legrand L., Pitel P.H., Wegge B., Lissens J., Freymuth F., Richard E., Fortier G. (2012). Outbreak of equine herpesvirus myeloencephalopathy in France: a clinical and molecular investigation. *Transbound Emerging Diseases* 59, 256-263.
- Pronost S., Pitel P.H., Miszczak F., Legrand L., Marcillaud-Pitel C., Hamon M., Tapprest J., Balasuriva U.B., Freymuth F., Fortier G. (2010). Description of the first recorded major occurrence of equine viral arteritis in France. *Equine Veterinary Journal* 42(8), 713-720.
- Ricketts S.W., Barrelet A., Whitwell K.E. (2001). A review of the causes of abortion in UK mares and means of diagnosis used in an equine studfarm practice in Newmarket. *Pferdeheilkunde* 17, 589-592.
- Ricketts S.W., Barrelet A., Whitwell K.E. (2003). Equine abortion. *Equine Veterinary Education, Manual* 6, 18-21.
- Saegerman C., Grégoire F. Delooz L. (2022). Diagnosis of Coxiella burnetii cattle abortion: a one-year observational study. *Pathogens* 11, 429-444.
- Sebastian M.M., Bernard W.V., Riddle T.W., Latimer C.R., Fitzgerald T.D., Harrison L.R. (2008). Review paper: mare reproductive loss syndrome. *Veterinary Pathology* 45(5), 710-722.
- Smith K.C., Blunden A.S., Whitwell K.E., Dunn K.A., Wales A.D. (2003). A survey of equine abortion, stillbirth and neonatal deaths in UK from 1988 to 1997. *Equine Veterinary Journal* 35, 496-501.
- Szeredi L., Hotzel H., Sachse K. (2005). High prevalence of chlamydial (Chlamydia psittaci) infection in foe-



- tal membranes of aborted equine fetuses. *Veterinary Research Communications* 29(1), 37-49.
- Szeredi L., Tenk M., Janosi S., Palfi V., Hotzel H., Sachse K., Pospischil A., Bozso M., Glavits R., Molnar T. (2008). A survey of equine abortion and perinatal foal losses in Hungary during a three-year period (1998-2000). *Acta Veterinaria Hungarica* 56, 353-367.
- Tengelsen L.A., Yamini B., Mullaney T.P., Bell T.G., Render J.A., Patterson J.S., Steficek A., Fitzgerald S.C., Kennedy F.A., Slanker M.R., Ramos-Vara J.A. (1997). A 12-year retrospective study of equine abortion in Michigan. *Journal of Veterinary Diagnostic Investigation* 9, 303-306.
- Van der Meulen K.M., Caij A., Nauwynck H., Pensaert M. (2001). An outbreak of equine viral arteritis abortion in Belgium. *Vlaams Diergeneeskundig Tijdschrift* 70, 221-222.
- Vandenplasse M., Lauwers H. (1986). The twisted umbilical cord: an expression of kinesis of the equine foetus? *Animal Reproduction Science* 10(3), 163-175.
- Van Loo H., Bogado Pascottini O., Ribbens S., Hooberghs J., Pardon B., Opsomer G. (2021). Retrospective study of factors associated with bovine infectious abortion and perinatal mortality. *Preventive Veterinary Medicine*. doi: 10.1016/j.prevetmed.2021.105366.
- Verma A., Stevenson B., Adler B. (2013). Leptospirosis in horses. *Veterinary Microbiology* 167(1-2), 61-66.
- Veronesi F., Diaferia M., Mandara M.T., Marenzoni M.L., Cittadini F., Piergili Fioretti D. (2008). Neospora spp. Infection associated with equine abortion and/or stillbirth rate. *Veterinary Research Communications* 21(Suppl 1), 223.
- Villalobos E.M., Ueno T.E., de Souza S.L., Cunha E.M., do Carmo Custodio de Souza Hunold Lara M., Genari S.M., Soares R.M. (2006). Association between the presence of serum antibodies against Neospora spp. and foetal loss in equines. *Veterinary Parasitology* 142(3-4), 372-375.
- Weber R., Hospes R., Wehrend A. (2018). Causes of abortion in horses – overview of the literature and own evaluations. *Tierärztliche Praxis Ausgabe G: Grosstiere/Nutztiere* 46(1), 35-42.
- Whitwell K.E., Blunden A.S., Miller J., Errington J. (2009). Two cases of equine pregnancy loss associated with Leptospira infection in England. *Veterinary Records* 165(13), 377-378.
- Yildirim Y., Yilmaz V., Kirmigizul A.H. (2015). Equine herpesvirus type 1 (EHV-1) and 4 (EHV-4) infections in horses and donkeys in northeastern Turkey. *Iranian Journal of Veterinary Research* 16(4), 341-344.
- Yin L., Schautteet K., Kalmar D., Bertels G., Van Driessche E., Czaplicki G., Borel N., Longbottom D., Fretin D., Dispas M., Vanrompay D. (2014) Prevalence of Chlamydia abortus in Belgian ruminants. *Vlaams Diergeneeskundig Tijdschrift* 83, 164-170.



© 2023 by the authors. Licensee Vlaams Diergeneeskundig Tijdschrift, Ghent University, Belgium. This article is an open access article distributed under the terms and conditions of

the Creative Commons Attribution (CC BY) license (<http://creativecommons.org/licenses/by/4.0/>).

## DGZ Vlaanderen als exclusieve partner van PathoSense voor Belux

Vanaf 2 mei 2023 zullen alle PathoSense analyses in de Belux exclusief uitgevoerd worden in het labo van DGZ. Dit werd op 29 maart 2023 officieel vastgelegd in de samenwerkingsovereenkomst die werd ondertekend tussen DGZ-MCC-Vivee en PathoSense.

PathoSense is een recente UGent spin-off die door dr. Sebastiaan Theuns en prof. dr. Hans Nauwynck werd opgericht in oktober 2020. PathoSense biedt een compleet 'staalname-tot-en-met-diagnostisch-interpretatie'-platform voor infectieziekten in de diergeneeskunde aan via nanopore sequencing (Oxford Nanopore Technologies). Via een gepatenteerde nieuwe swab kan je als dierenarts op een eenvoudige wijze stalen collecteren en de pathogenen in het staal meteen opzuiveren. De registratie van de analyse gebeurt via een intuïtieve mobiele app. Aangezien het platform gebruik maakt van een metagenoom analyse gebaseerd op ad random nanopore sequencing, hoef je geen voorafgaande selectie te maken van de te testen pathogenen. Hierdoor kan er een brede identificatie van virussen en bacteriën uitgevoerd worden bij acuut zieke dieren. Deze analyse kan worden ingezet voor alle diersoorten.



Marcel Heylen, voorzitter van DGZ en dr. Sebastiaan Theuns, co-founder van PathoSense ondertekenden de samenwerkingsovereenkomst onder het goedkeurend oog van prof. dr. Hans Nauwynck, co-founder van PathoSense en prof. dr. Benedikt Sas, directeur van DGZ.

Vanaf begin mei worden de PathoSense-analyses uitgevoerd in het labo van DGZ. Dierenartsen die de kit reeds in hun bezit hebben kunnen deze blijven gebruiken. Andere labo's die de kits nu al verdelen, blijven dit doen.

