



HAL
open science

An unprecedented case of cranial surgery in Longobard Italy (6th–8th century) using a cruciform incision

Ileana Micarelli, Flavia Strani, Samuel Bédécarrats, Sara Bernardini, Robert Paine, Lawrence Bliquez, Caterina Giostra, Valentina Gazzaniga, Mary Anne Tafuri, Giorgio Manzi

► To cite this version:

Ileana Micarelli, Flavia Strani, Samuel Bédécarrats, Sara Bernardini, Robert Paine, et al.. An unprecedented case of cranial surgery in Longobard Italy (6th–8th century) using a cruciform incision. *International Journal of Osteoarchaeology*, 2023, 33 (2), pp.187-195. 10.1002/oa.3202 . hal-03964969

HAL Id: hal-03964969

<https://normandie-univ.hal.science/hal-03964969v1>

Submitted on 31 Jan 2023

HAL is a multi-disciplinary open access archive for the deposit and dissemination of scientific research documents, whether they are published or not. The documents may come from teaching and research institutions in France or abroad, or from public or private research centers.







L'archive ouverte pluridisciplinaire **HAL**, est destinée au dépôt et à la diffusion de documents scientifiques de niveau recherche, publiés ou non, émanant des établissements d'enseignement et de recherche français ou étrangers, des laboratoires publics ou privés.



Distributed under a Creative Commons Attribution 4.0 International License

SHORT REPORT

An unprecedented case of cranial surgery in Longobard Italy (6th–8th century) using a cruciform incision

Ileana Micarelli¹  | Flavia Strani^{2,3}  | Samuel Bedecarrats⁴  |
 Sara Bernardini^{5,6}  | Robert R. Paine⁵ | Lawrence Bliquez⁷ | Caterina Giostra⁸ |
 Valentina Gazzaniga⁹  | Mary Anne Tafuri⁵  | Giorgio Manzi⁵ 

¹McDonald Institute for Archaeological Research, University of Cambridge, Downing St, Cambridge, CB2 3ER, UK

²Departamento de Ciencias de La Tierra, and Instituto Universitario de Investigación en Ciencias Ambientales de Aragón (IUCA), Universidad de Zaragoza, Zaragoza, 50009, Spain

³Department of Earth Sciences, Sapienza University of Rome, Piazzale Aldo Moro 5, Rome, 00185, Italy

⁴UMR 6273 CRAHAM, CNRS, Université de Caen Normandie, Esplanade de la paix, Caen cedex 5, CS, 14032, France

⁵Department of Environmental Biology, Sapienza University of Rome, Piazzale Aldo Moro 5, Rome, 00185, Italy

⁶Aix Marseille Univ, CNRS, Minist Culture, LAMPEA, Aix-en-Provence, France

⁷Department of Classics, University of Washington, Seattle, Washington, 98195-3110, USA

⁸Department of History, Archaeology and Art History, Università Cattolica del Sacro Cuore, Lrg. Agostino, Gemelli 1, 20123, Milan, Italy

⁹Department of Medico-Surgical Sciences and Biotechnologies, Sapienza, University of Rome, Piazzale Aldo Moro 5, Rome, 00185, Italy

Correspondence

Prof Giorgio Manzi, Department of Environmental Biology, Sapienza, University of Rome, Piazzale Aldo Moro 5, 00185 Rome (IT).
 Email: giorgio.manzi@uniroma1.it

Dr Ileana Micarelli, McDonald Institute for Archaeological Research, University of Cambridge, Downing St, CB2 3ER, Cambridge, UK.
 Email: im452@cam.ac.uk

Funding information

HORIZON EUROPE Marie Skłodowska-Curie Actions, B-CARED Osteobiographical investigation of disability and care in Medieval Europe, Grant/Award Number: 101061838; Source of support: "Population biology, diseases and mobility: Romans and Longobards in the post-classical era", Grande Progetto Sapienza 2018, RG118164364E4CB5.

Abstract

The Longobard necropolis of Castel Trosino dates from the 6th to the 8th century CE. Among the tombs excavated, the skull of an older female shows the first evidence of a cross-shaped bone modification on a living subject. Macroscopic, microscopic, and CT scan analyses revealed signs of at least two sets of scraping marks. Specifically, SEM analysis shows that *perimortem* bone-scraping traces are present on the skull. Both healed and non-healed defects suggest that the woman has received at least twice intentional bone modifications to address her condition. This is the first evidence of a cross-shaped therapeutic intervention on a living subject.

KEYWORDS

bioarchaeology, CT scan, paleopathology, SEM analysis, skull defect

1 | INTRODUCTION

Cranial defects constitute a significant interpretative challenge for osteoarchaeologists. They may be hidden by the proliferative or

resorptive bone response (Verano, 2017). To improve the quality of the interpretation of defects, it is critical to approach this process with a differential diagnosis perspective and contextualize findings with historical medical documents and the archeological record

Ileana Micarelli, Flavia Strani, and Samuel Bedecarrats contributed equally.

This is an open access article under the terms of the [Creative Commons Attribution](https://creativecommons.org/licenses/by/4.0/) License, which permits use, distribution and reproduction in any medium, provided the original work is properly cited.

© 2023 The Authors. *International Journal of Osteoarchaeology* published by John Wiley & Sons Ltd.

(e.g., Aidonis et al., 2021). Using a multidisciplinary approach, we present unprecedented evidence specific to several cranial defects observed in one female skull.

The remains were excavated from the Longobard cemetery of Castel Trosino, *contrada* Santo Stefano (Figure 1a,b) in central Italy, dated to the Early Middle Ages (Ascoli Piceno, 6th–8th century CE; Ricci & Paroli, 2007). The cemetery was investigated at the end of the 19th century (Mengarelli, 1902; Sergi, 1902). Hundreds of burials were recovered, but only 19 skulls are available for assessment (Micarelli et al., 2021).

Castel Trosino was a critical site in the complex political situation that developed after the collapse of the Roman Empire (postclassical

period). After losing Po Valley territories, the Byzantine government stabilized military control of central Italy. As a result, during the 6th century CE, Castel Trosino became a strategic site. The archaeological literature (Delogu, 2016; Ricci & Paroli, 2007) describes the site as having a non-preminent military function. The first Longobard phase at Castel Trosino began during the last decade of the 6th century (Jørgensen, 1991; Ricci & Paroli, 2007). Most likely, this phase was established by a small group of warriors led by high-ranking military leaders who were given the insignia of Imperial Generals (Delogu, 2016). They aimed to compensate barbarian leaders associated with the Imperial government and ensure regional peace. To do so, the Byzantine authorities encouraged the occupation of Castel

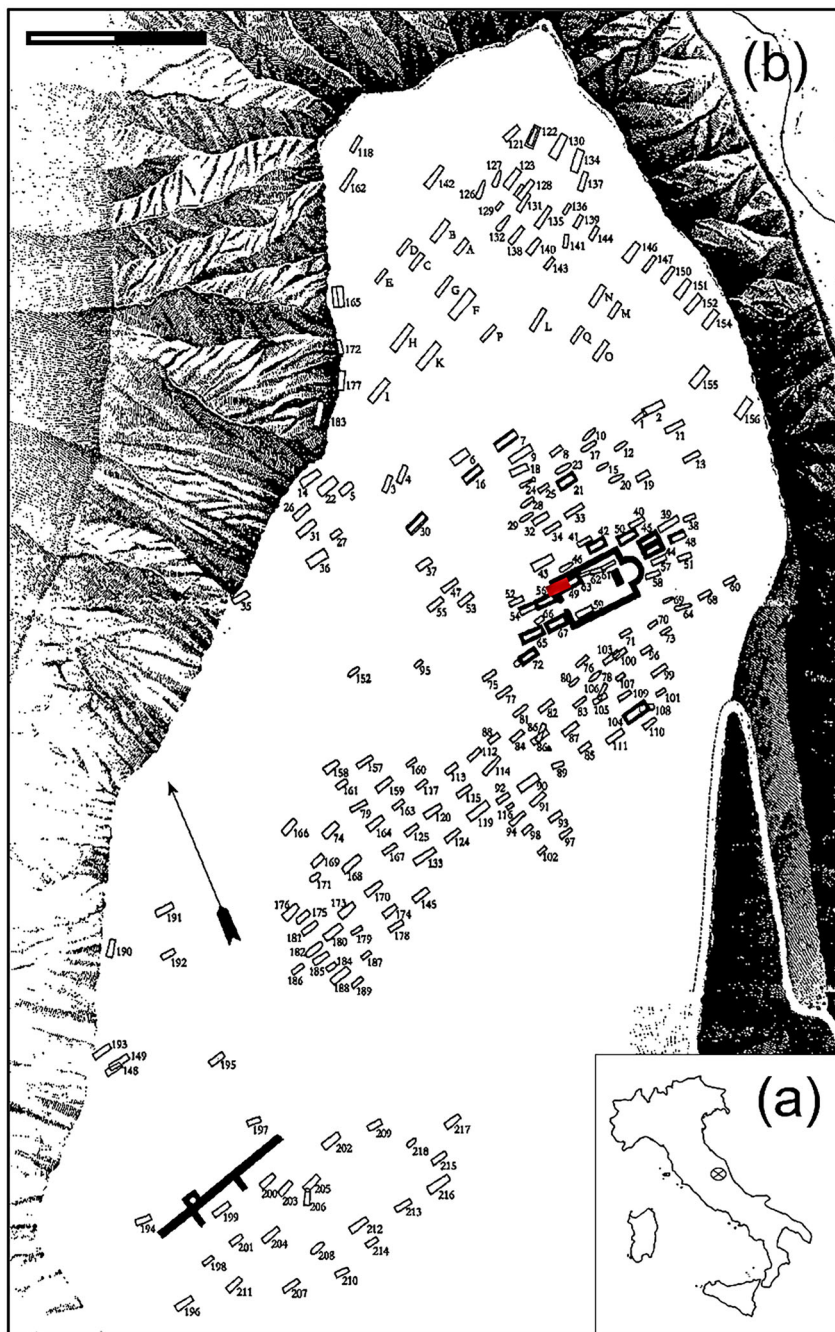


FIGURE 1 (a) Location of Castel Trosino (Ascoli Piceno, Italy); (b) map of the necropolis in the *contrada* Santo Stefano. Burial T67 is in red. Image modified from Ricci & Paroli, (2007), Figure 2, p.10. [Colour figure can be viewed at [wileyonlinelibrary.com](https://onlinelibrary.wiley.com/doi/10.1002/oa.3202)]

Trosino by Longobard elites (Delogu, 2016; Jørgensen, 1991; Profumo & Staffa, 2007; Ricci & Paroli, 2007). Castel Trosino became the residence of several prestigious families, as indicated by exceptional grave goods (gold objects and fine jewelry). As unique postclassical Italian grave goods, these pieces are primarily Roman-Byzantine manufactured and correspond to the customs of Byzantine and Longobard societies (Delogu, 2016).

2 | MATERIALS AND METHODS

Skull CT1953 was found in a double burial (T67) at the Christian Church exterior façade in the center of the cemetery. Grave goods included a bronze brooch, comb, and gold filaments (Mengarelli, 1902). The burial location and the richness of the grave goods suggest that the two owners (a male and a female; Micarelli et al., 2021) come from a privileged family (Delogu, 2016). The skull is well-preserved; the surface morphology is intact, with no modifications caused by taphonomic processes (Figure 2).

A biological profile of the skull was conducted following standard anthropology protocols. Sex was determined via cranial morphological traits (Buikstra & Ubelaker, 1994), and the age at death was estimated by examining cranial sutures (Meindl & Lovejoy, 1985) and dental occlusal wear (Walker et al., 1991).

2.1 | Methods for the analysis of the bone marks

A gross pathological assessment was conducted to document the cranial defects (Kranioti, 2015; Lovell, 1997; Redfern & Roberts, 2019).

Two acquisitions of the skull from CT1953 (Figure 2) were performed at the Istituto Superiore di Sanità in Rome (IT) via cone beam

CT scan (NewTom 5GXL EXTRA.VISION) using a protocol adapted to bone analysis (slice thickness: 0.3 mm, 110 kVp). Virtual reconstruction of the scan was performed on a $611 \times 692 \times 539$ pixel matrix (Schindelin et al., 2012).

We molded the scraped areas using a nondestructive and conservation-friendly technique for investigating skeletal remains (see Camarós et al., 2016). We analyzed epoxy resin casts via scanning electron microscope (SEM). Following a standard protocol (Strani et al., 2018), we prepared casts of the bone defects on the CT1953 skull (the complete procedure is described in Figure 3).

3 | RESULTS

Cranial morphology indicates that the skull is female, approximately 50 years old. The macroscopy investigation showed a cross-shaped area of porous bone on the external surface of the cranial vault, with an oval-shaped depression at the center of the cross. The anterior frontal bone shows a second oval-shaped scraped area. These are described in detail in Table 1. Moreover, two abscesses (one involving the alveolus of RI¹ and RI² and the other affecting the LI²; Figure 2a) and *antemortem* tooth loss (right maxilla: RI¹, RI², RC, LM³; and left maxilla: LI¹, LI², LC, LP¹, LP²; Figure 2a) were also observed and illustrated (Figure 2a,b).

The CT scan analysis showed a thickening of the diploe in the frontal area, which presents a significant width (10 measurements: mean 21.50 mm, min 15.3, max 26.72). This is considered abnormal compared to modern populations (e.g., Şakir Ekşi et al., 2021 represent 8.7 mm for women). This change may reveal the first phase of *hyperostosis frontalis interna* (HFI), a condition that appears commonly in female individuals during menopause (at century 50 years old) (Cvetković et al., 2020; Figure 4a). This differential diagnosis can be

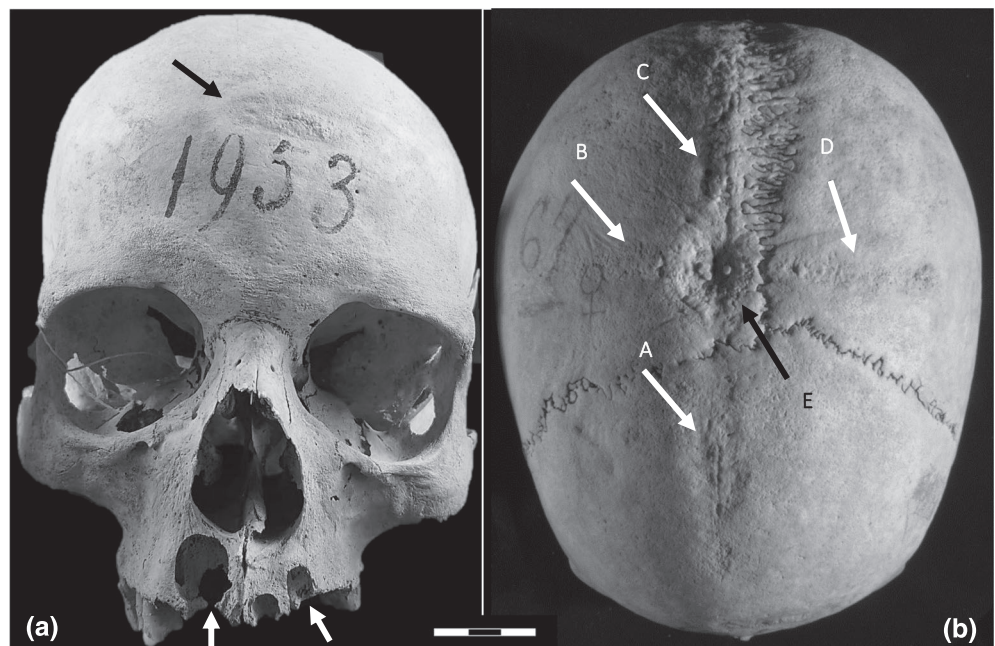

FIGURE 2 Skull CT1953 from burial T67. (a) Frontal view. The black arrow indicates the large oval scraped area on the frontal bone. The white arrows show the abscesses involving RI¹ and RI² and LI². (b) Superior view. The black arrow indicates the circular ectocranial depression near bregma. The white arrows show the cross-shaped scraping parallel to the sagittal and coronal sutures.




FIGURE 3 Molding and casting process on CT1953 skull. (a) The bone surface is cleaned by wiping with cotton swabs moistened with acetone ($\geq 99.5\%$). Then, acetone was removed by ethanol and left to dry completely. (b) The silicone was applied to the bone defects with the dispensing gun (blue silicone). As Camarós et al. (2016: 4) recommended, another layer of silicone is added to cover it (the orange one in the picture). (c) The casts were laid following the anatomical position and marked to distinguish them. Silicone walls (in orange) were added to contain the transparent epoxy resin (araldite LY 554) and catalyst (HY 956) for the positive casts. We left the transparent epoxy resin for 48 h in a dry place. (d) The casts passed through the metallization of the surface with golden powder. (e) The sample was examined with SEM at the Department of Scienze della Terra, Sapienza, University of Rome. [Colour figure can be viewed at [wileyonlinelibrary.com](https://onlinelibrary.wiley.com/doi/10.1002/oa.3202)]

related to a calvaria thickening or HFI. However, considering that the skull does not have the large bone nodules typical of HFI (Herskovitz et al., 1999), we cannot consider HFI the only possibility. Although the individual's biological profile tends to favor this hypothesis, other conditions such as an idiopathic form, Paget's disease, sclerosing dysplasia, acromegaly, or a hematopoietic disorder cannot be excluded. The absence of clear signs and the impossibility of an exhaustive examination of the skeleton do not allow the differential diagnosis to be refined.

The CT scan shows sagittal fissures in the middle of Defect E (black arrows in Figure 4b, white arrow and white square in Figure 4d) and endocranial and ectocranial bone thinning correspondingly with the circular depression near bregma (white arrow and white square in Figure 4d).

Recent cut marks are recognized via SEM analysis of the defects (Figure 5). The V-shaped marks have a profound deep point with sharp edges (Table 1; Figure 5a,b arrows), suggesting a *perimortem* or *postmortem* event.

4 | DISCUSSION

Pitting and periosteal new bone formation on the external table of cranial vault suggests changes secondary to inflammation (Figure 2b). The cut marks seen on visual inspection, and scanning electron microscopy would indicate that metal surgical tools were used. A plausible interpretation of these changes would be that a cross-shaped incision had been made to the top of the head by a medical practitioner, and the scalp scraped away from the bone, stimulating inflammation. If infection of the wound occurred, this would add to the inflammation. The oval area at the center of the cross appears to be a well-healed scraped trepanation.

The use of several shaped instruments and medical procedures are well-documented (Bliquez, 2014). Medical instrumentations and the methods of their use were passed almost unchanged from Greek to Arabic and Byzantine literature. Instruments and treatments were standardized and remained unchanged throughout the Middle Ages (Gazzaniga & Marinozzi, 2015). Various drilling techniques were used

TABLE 1 Description of defects for a differential diagnosis

Defect on the skull	Bone involved	Description of the defect	Measurements	Bone reaction
The oval defect on the frontal bone	Frontal bone	A large oval area runs laterally across the central portion of the frontal bone.	Length: 43 mm Max width: 16 mm	Healed: Visible to the naked eye; Figure 2a, black arrow
Defect A	Frontal bone	Oval branch on the upper part of the frontal squama. This defect runs anterior to posterior. It has a hollowed ridge of bone in the center, whereas the outer edges are deeply marked.	Length: 40 mm Max width: 11 mm	Healed: Bone reaction with the osteoblastic and osteolytic remodeling in the entire area of the defect (visible to the naked eye; Figure 2b, white arrow) No healing process: Marks with sharp edges and sharp edges, V-shaped sections. The marks run parallelly and perpendicularly (SEM images; Figure 5a, black arrows)
Defect B	Right parietal	The defect runs parallel to the coronal suture. This lesion is perpendicular to Lesion C.	Length: 60 mm Max width: 10 mm	Healed: Bone reaction with the osteoblastic and osteolytic remodeling in the entire defect area (visible to the naked eye, Figure 2b, white arrow) No healing process: The marks run parallel to each other (SEM images).
Defect C	Right parietal	Defect C runs parallel to the sagittal suture. Lesion C has a raised line of remodeled compacted bone (30 × 5 mm)	Length: 60 mm Max width: 8 mm	No good quality SEM picture to determine the healing process
Defect D	Left parietal	Defect D runs parallel to the coronal suture. At the most lateral part, there is a small, raised surface (10 × 5 mm)	Length: 60 mm Max width: 11 mm	Healed: Bone reaction with the osteoblastic and osteolytic remodeling in the entire area of the defect (visible to the naked eye; Figure 2b, white arrow) No healing process: Marks with sharp edges and sharp edges, V-shaped sections. The marks run parallelly and perpendicularly (SEM images; Figure 5b, black arrows)
Defect E	Right parietal	At the intersection of the A, B, C, and D defects, there is an oval-shaped defect at 1 mm from the sagittal suture and 8 mm from the coronal one. The center portion is more profound than the outer edge (minus 1,5 mm from the external tables of the skull). In the middle of lesion E, two tiny holes lead into the braincase (hole a 0,5 mm in diameter; hole b 1 mm in diameter). There are three small osteophytes on the border of the deep lesion: Osteophyte (i) on the left board 1,5 mm in diameter; osteophyte (ii) on the frontal board 2 × 8 mm; osteophyte (iii) in the middle 3 × 2 mm: (Figure 4b). There are two fissures in the middle of the Defect E: (Fissure I) 2-mm long; (Fissure II) 1-mm long.	Length: 20 mm Max width: 15 mm	Healed: Bone reaction with the osteoblastic and osteolytic remodeling in the entire area of the defect (visible to the naked eye; Figure 2b, white arrow) No healing process: Marks with sharp edges and V-shaped sections. The marks run parallelly and perpendicularly (SEM images; Figure 5c, black arrows)

for curative purposes. Both Celsus (1st century) and Paul of Aegina (7th century) describe in their respective medical treatises the scraping of the skull with a sharp-edged metal tool as a trepanation

procedure (González-Darder, 2019). Constantine the African, in his “Surgery” (chapter 92), was the first mentioning cross-shape scalping (Perrot, 1982). The 12th century Book I of *Practica Chirurgiae* by

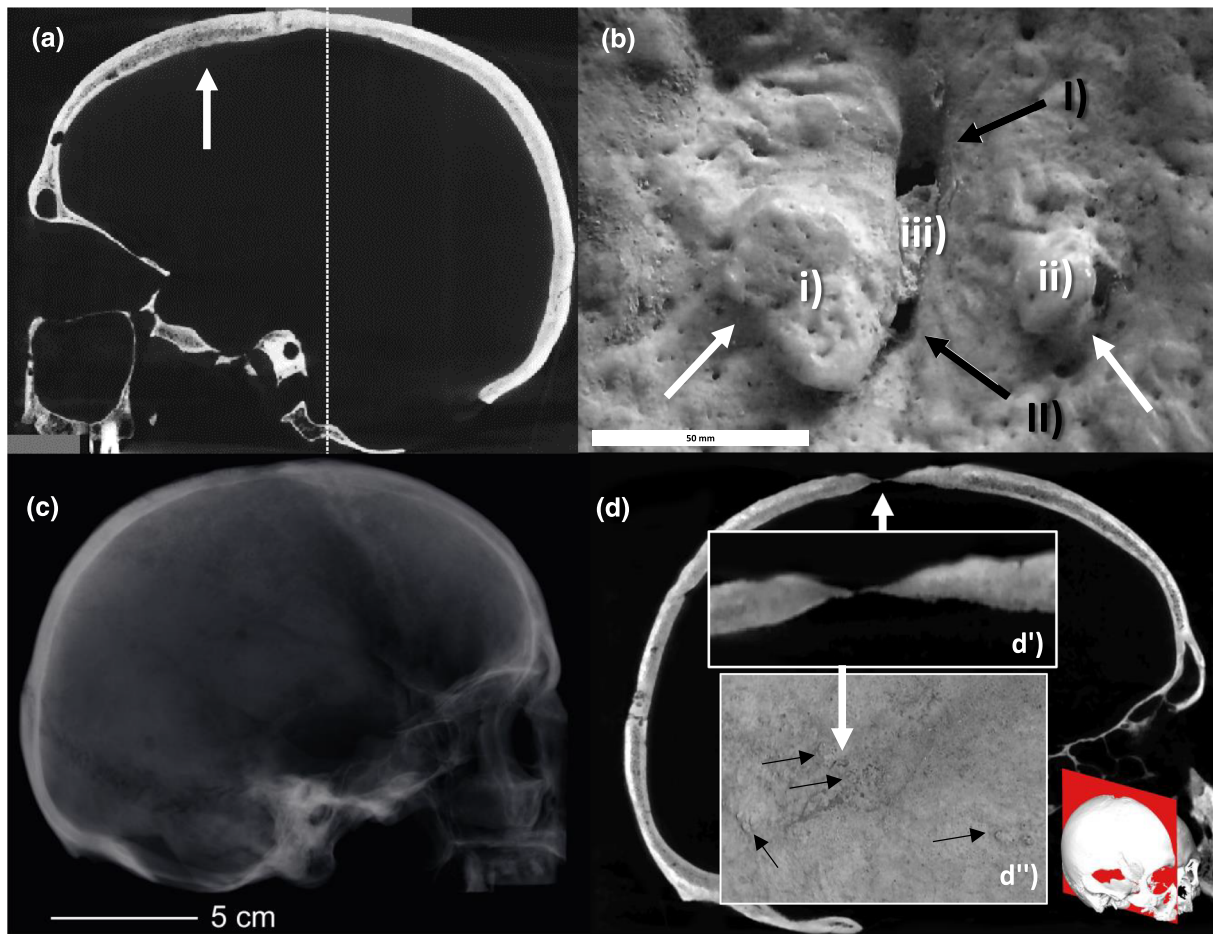


FIGURE 4 Virtual analyses of the skull CT1953. (a) CT scan of the skull (left view). The arrow shows the diploe of the frontal area; (b) magnification of the circular ectocranial depression near bregma, labelled in Table 1 Defect E, external view. The white arrows indicate the osteophytes, and the black ones shows the fissures, described in Table 1; (c) X-rays of the skull, right side; (d) sagittal view of the skull CT scan. The white arrow indicates the thinning of the bone (endocranial and ectocranial) in correspondence with the circular depression near bregma. D') shows the opening into the skull. D'') black arrows indicate the presence of lithic lesions. [Colour figure can be viewed at wileyonlinelibrary.com]




FIGURE 5 SEM analyses of the skull CT1953. Arrows indicate incision by a sharp object showing no remodeling. (a) Defect A; (b) Defect C; (c) Defect E

Roger Frugard, which incorporates Greco-Roman medical traditions, describes the X-shaped incision as a regular way of clearing the scalp to get to the cranium.

The endocranial thinning of the cranial vault near bregma (Defect E, Figure 4d') shows rim formation and bone loss of the diploic structure (Figure 4d), suggesting significant healing. This can

be linked to several conditions. Among them, we considered (i) perforating trauma results from the severe impact on the skull. This may cause the break of the inner table of the skull and, eventually, fracture lines running from the injury (Nerlich et al., 2003; Rubini & Zaio, 2011). Given the impact and the open fracture in the skull, these lethal traumas often lead to death. This is not the case for CT1953; (ii) neoplastic pathologies (e.g., multiple myeloma and metastatic carcinoma): the absence of the typical destructive lesions (e.g., sunburst, scalloped, and edges) and the lack of multiple lesions (Marques, 2019; Figure 4c and Table 1), suggest eliminating this hypothesis; (iii) middle meningeal artery (MMA) aneurysm: can be excluded given the position of the lesion (Ricconi et al., 2022); (iv) arachnoid granulations: their shape and location, mainly along the transverse or superior venous sinuses, may lead to excluding this condition for CT1953 (Gomez et al., 2018). However, arachnoid granulations can also be related to meningiomas. In these cases, granulation is often found at the bregma (Ye et al., 2022). The endocranial thinning of the CT1953 skull might be related to this condition (Figure 4d”).

The abscesses on the maxilla severely affected the pulp cavity, causing infection and resorption of the maxillary bone. Dental abscesses and *antemortem* tooth loss likely indicate poor oral health (Larsen, 2015).

Given the absence of the mandible and the rest of the skeleton, it is challenging to diagnose a pathological condition. However, the presence of porosity on the skull surface and the lesion on the ectocranial surface suggests a systemic pathological condition that affected CT1953 during her life. Illness linked to chronic headaches and neurological, mental, or behavioral disorders is impossible to verify from the bones (Gresky et al., 2016).

CT1953 shows two sets of defects:

- i. *Antemortem*: bone response is present and visible to the naked eye (Figure 1a,b). Signs of remodeling, such as osteophyte and/or bony bridges, are the first bone response, indicating short-term survival (1–3 weeks up to 2.5 months after sustaining an injury). Long-term survival is supported by smooth bone surface. This occurs after 6 months (e.g. Barbian & Sledzik, 2008).
- ii. *Perimortem*: V-shaped marks indicate interventions close to death (Table 1; black arrows in Figure 5). Up to 5–7 days after the intervention, the edges of the marks are sharp without osteoclastic resorption or bone formation (Kranioti, 2015). No bone healing is present for these bone marks on the CT1953 skull. Moreover, the repetitive movements by a practitioner created *perimortem* intersecting scraping mark on the skull surface (black arrows in Figure 5).

Redfern and Roberts (2019) suggest that intentional superficial cranial changes with a non-penetrated cranial vault are infrequently reported in the literature (e.g., the T-sincipital described by Manouvrier in 1895). Following Verano (2017: 2), scraping trepanations consist of gradually removing the outer table and diploe. When the inner table is exposed, it can be scraped or broken out. We support the argument that the bone marks on the CT1953 skull are a series of voluntary

actions (i.e., the oval defect on the frontal bone, Figure 2a; Defects A, B, C, D, and E Figure 2a,b; Table 1). These were planned, and an operator intentionally conducted recurring bone modifications. Given the extension and the voluntary repetition of the interventions and the presence of the fissures in the cranial vault following the Western nomenclature (Lisowski, 1967), we define the oval-shaped Defect E as a trepanation obtained via the cruciform surgical incisions (Defects A, B, C, and D). Drilling and scraping the skull did not always mean penetrating through the *dura mater*, as in some cases, ancient trepanations were designed not to create an opening in the skull (Bliquez, 2014: 186). Greco-Roman medical literature offers examples of more superficial skull drilling or scraping to treat decaying cranial tissue or tere-donismos (Oribasius, Coll. Med. 46.22.16; Heliodorus), excessive callus as a *sequela* to fracture (Paul 6.108.1), and excessive bone growth (Oribasius, Coll. Med. 46.29.8; Heliodorus). Correction of these situations required drills, chisels, and rugines/curettes. Oribasius indicates this when he recommends promoting the growth of flesh after head trauma by first scraping to the diploe “with an ordinary/common scraping tool” (διὰ κοινοῦ ξυστήρος; Coll. Med.46.9.5).

To further explore an alternative rationale for the cranial scraping, we considered ritualistic/sacral trepanations used by the Avar people in the Carpathian basin during the 6th and the 11th century CE (Bereczki et al., 2015; Király et al., 2022; Mednikova, 2003). Following this archeological example, the Longobard people of Castel Trosino and Byzantine culture are tightly intertwined (Ebanista & Rotili, 2010). Although the symbolic hypothesis is fascinating, no documented or archeological evidence supports that ritualistic trepanation practice was borrowed from Eastern Barbaric for CT1953.

We also considered that the scraping might be related to judicial punishment, namely, *decalvatio*, as written in Longobard law (Gasparri & Azzara, 2011). This penalty was of particular gravity and rarely applied (Longobard laws: King Liutprando: law number 141, and King Astulf: law number 4). It entailed cutting off the hair and removing part of the skin of the skull. Scalping implied permanent visual mutilation. Given the persistence of beliefs in the magical value of hair, *decalvatio* in the Longobard culture was a dishonorable punishment. Two reasons are given for *decalvatio*: (i) soldiers who left the field of battle with a loss of manhood (Venchiarutti, 2006); and (ii) the *iudices* (i.e., with public functions) who traded with the Byzantines without the king's license (Bertolini, 1962). As Gresky et al. (2017) pointed out, cases of scalping in the osteological record show a unique pattern of cut marks on the skull. These form a rough circle around the skull and are clustered in small groups on the frontal, parietal, and occipital bones (Bueschgen & Case, 1996; Toyne, 2011). None of these cut marks is present on the skull. Moreover, the sex and the historical background of CT1953 firmly exclude the *decalvatio*.

5 | CONCLUSIONS

We employed CT scan and SEM analysis as part of a bioarchaeological and paleopathological investigation assessing an Early

Medieval Longobard woman's skull. We found that she had survived several surgeries and experienced long-term trepanation therapy. The last surgery appears to have occurred just before the individual's death. There is no evidence of trauma, tumor, congenital disorder, or other pathology; hence, why a Medieval medical practitioner would undertake such a dangerous surgery is considered here. Although it is intriguing to consider the possibilities of ritual or judicial resolution, no biological or historical evidence supports these hypotheses.

Nevertheless, this represents one of the few pieces of archaeological evidence of a trepanation surgery performed on Early Medieval women paving the path for future research on the rationale behind this dangerous surgical procedure in this period.

ACKNOWLEDGEMENTS

We thank Dr Rossella Bedini of the Istituto Superiore di Sanità in Rome (IT) for acquiring the CT scans of the skull. We thank Dr Tania Ruspandini of the Department of Scienze della Terra, Sapienza, University of Rome (IT) and Dr Marco Albano at CNR in Rome (IT) for SEM acquisitions.

We wish to thank the two anonymous reviewers and the Editor for their valuable comments and suggestions.

Source of support: "Population biology, diseases and mobility: Romans and Longobards in the post-classical era", Grande Progetto Sapienza 2018, RG118164364E4CB5; HORIZON EUROPE Marie Skłodowska-Curie Actions, B-CARED Osteobiographical investigation of disability and care in Medieval Europe, 101061838.

This study does not involve any modern human or animal subject. Open Access Funding provided by Università degli Studi di Roma La Sapienza within the CRUI-CARE Agreement.

CONFLICT INTEREST STATEMENT

The authors declare no conflicts of interest.

DATA AVAILABILITY STATEMENT

The data that support the findings of this study are available from the corresponding author upon reasonable request.

ORCID

Ileana Micarelli  <https://orcid.org/0000-0001-7498-5218>

Flavia Strani  <https://orcid.org/0000-0003-4566-3644>

Samuel Bedecarrats  <https://orcid.org/0000-0001-6016-577X>

Sara Bernardini  <https://orcid.org/0000-0001-7283-6323>

Valentina Gazzaniga  <https://orcid.org/0000-0003-2110-4856>

Mary Anne Tafuri  <https://orcid.org/0000-0002-2913-7225>

Giorgio Manzi  <https://orcid.org/0000-0002-8611-1371>

REFERENCES

Aidonis, A., Papavramidou, N., Moraitis, K., & Papageorgopoulou, C. (2021). Trepanations in the ancient Greek colony of Akanthos: Skull surgery in the light of Hippocratic medicine. *International Journal of Paleopathology*, 35, 8–21. <https://doi.org/10.1016/j.ijpp.2021.07.008>

- Barbian, L. T., & Sledzik, P. S. (2008). Healing following cranial trauma. *Journal of Forensic Sciences*, 53(2), 263–268. <https://doi.org/10.1111/j.1556-4029.2007.00651.x>
- Bereczki, Z., Molnár, E., Marcsik, A., & Pálfi, G. (2015). Rare types of trepanation from Hungary shed new light on possible cross-cultural connections in the Carpathian Basin. *International Journal of Osteoarchaeology*, 25(3), 322–333. <https://doi.org/10.1002/oa.2304>
- Bertolini, O. (1962). Astolfo, re dei Longobardi. In A. M. Ghisalberti (Ed.). *Treccani, Dizionario Biografico degli Italiani - Volume 4*. Istituto Della Enciclopedia Italiana. online version: https://www.treccani.it/enciclopedia/re-dei-longobardi-astolfo_%28Dizionario-Biografico%29/
- Bliquez, L. (2014). *The tools of Asclepius: Surgical instruments in Greek and Roman times* (pp. 185–195). Brill.
- Bueschgen, W. D., & Case, D. T. (1996). Evidence of prehistoric scalping at Vosberg, Central Arizona. *International Journal of Osteoarchaeology*, 6(3), 230–248. [https://doi.org/10.1002/\(SICI\)1099-1212\(199606\)6:3<230::AID-OA268>3.0.CO;2-Y](https://doi.org/10.1002/(SICI)1099-1212(199606)6:3<230::AID-OA268>3.0.CO;2-Y)
- Buikstra, J. E., & Ubelaker, D. H. (1994). *Standard for data collection from human skeletal remains, Arkansas archaeological survey research series, n. 40*. Wiley.
- Camarós, E., Sánchez-Hernández, C., & Rivals, F. (2016). Make it clear: Molds, transparent casts and lightning techniques for stereomicroscopic analysis of taphonomic modifications on bone surfaces. *Journal of Anthropological Sciences*, 94, 1–8.
- Cvetković, D., Jadžić, J., Milovanović, P., Djonić, D., Djurić, M., Bracanović, D., Nikolić, S., & Živković, V. (2020). Micro-computed tomography study of frontal bones in males and females with hyperostosis frontalis interna. *Calcified Tissue International*, 107, 345–352. <https://doi.org/10.1007/s00223-020-00730-2>
- Delogu, P. (2016). Storia immaginaria dei Longobardi di Castel Trosino. In A. Chavarría Arnau & M. Jurković (Eds.). *Alla Ricerca di un Passato Complesso. Contributi in onore di Gian Pietro Brogiolo per il suo settantesimo compleanno* (pp. 83–100). Brepols Publishers.
- Ebanista, C., & Rotili, M. (2010). *Ipsam Nolam barbari vastaverunt. L'Italia e il mediterraneo occidentale tra il V secolo e la metà del VI*. Atti del convegno internazionale di studi. Cimitile-Nola-Santa Maria Capua Vetere, 18–19 giugno 2009 (Vol. 2).
- Eksji, M. Ş., Güdük, M., & Usseli, M. I. (2021). Frontal bone is thicker in women and frontal sinus is larger in men: A morphometric analysis. *The Journal of Craniofacial Surgery*, 32(5), 1683–1684. <https://doi.org/10.1097/SCS.00000000000007256>
- Gasparri, S., & Azzara, C. (2011). Le leggi dei longobardi: storia, memoria e diritto di un popolo germanico. In S. Gasparri & C. Azzara (Eds.). *Le leggi dei Longobardi* (pp. 1–473). Viella.
- Gazzaniga, V., & Marinuzzi, S. (2015). Strumenti per la trapanazione del cranio: una storia di 'lunga durata'. *Giornale Italiano di Ortopedia e Traumatologia*, 41, 246–251.
- Gomez, C. K., Schiffman, S. R., & Bhatt, A. A. (2018). Radiological review of skull lesions. *Insights into Imaging*, 9(5), 857–882. <https://doi.org/10.1007/s13244-018-0643-0>
- González-Darder, J. M. (2019). Cranial Trepanation During the Middle Ages. In J. M. González-Darder (Ed.). *Trepanation, trephining and craniotomy* (pp. 95–107). Springer. <https://doi.org/10.1007/978-3-030-22212-3>
- Gresky, J., Batieva, E., Kitova, A., Kalmykov, A., Belinskiy, A., Reinhold, S., & Berezina, N. (2016). New cases of trepanations from the 5th to 3rd millennia BC in southern Russia in the context of previous research: Possible evidence for a ritually motivated tradition of cranial surgery? *American Journal of Physical Anthropology*, 160(4), 665–682. <https://doi.org/10.1002/ajpa.22996>
- Gresky, J., Haelm, J., & Clare, L. (2017). Modified human crania from Göbekli Tepe provide evidence for a new form of Neolithic skull cult. *Science Advances*, 3(6), e1700564. <https://doi.org/10.1126/sciadv.1700564>

- Hershkovitz, I., Greenwald, C., Rothschild, B. M., Latimer, B., Dutour, O., Jellema, L. M., & Wish-Baratz, S. (1999). Hyperostosis frontalis interna: An anthropological perspective. *American Journal of Physical Anthropology*, 109(3), 303–325. [https://doi.org/10.1002/\(SICI\)1096-8644\(199907\)109:3<303::AID-AJPA3>3.0.CO;2-I](https://doi.org/10.1002/(SICI)1096-8644(199907)109:3<303::AID-AJPA3>3.0.CO;2-I)
- Jørgensen, L. (1991). Castel Trosino and Nocera Umbra. A chronological and social analysis of family burial practices in Lombard Italy (6th–8th cent. AD). *Acta Archaeologica*, 62, 1–58.
- Király, K., Váradi, O. A., Kis, L., Nagy, R., Elekes, G., Bukva, M., Tihanyi, B., Spekker, O., Marcsik, A., Molnár, E., Pálfi, G., & Bereczki, Z. (2022). New insights in the investigation of trepanations from the Carpathian Basin. *Archaeological and Anthropological Sciences*, 14(4), 1–17.
- Kranioti, E. F. (2015). Forensic investigation of cranial injuries due to blunt force trauma: Current best practice. *Research and Reports in Forensic Medical Science*, 5, 25.
- Larsen, C. S. (2015). *Bioarchaeology: Interpreting behaviour from the human skeleton* (Vol. 69). Cambridge University Press.
- Lisowski, F. P. (1967). Prehistoric and early historic trepanation. In D. R. Brothwell & A. T. Sandison (Eds.), *Diseases in antiquity* (pp. 651–672). Ch C Thoma.
- Lovell, N. C. (1997). Trauma analysis in paleopathology. *American Journal of Physical Anthropology*, 104, 139–170. [https://doi.org/10.1002/\(SICI\)1096-8644\(1997\)25+<139::AID-AJPA6>3.0.CO;2-#](https://doi.org/10.1002/(SICI)1096-8644(1997)25+<139::AID-AJPA6>3.0.CO;2-#)
- Marques, C. (2019). Tumors of bone. In J. Buikstra (Ed.), *Ortner's identification of pathological conditions in human skeletal remains* (pp. 639–717). Academic Press.
- Mednikova, M. B. (2003). Ritual initiation in prehistoric Eurasians based on cranial data: Symbolic trepanations. *Archaeology, Ethnology and Anthropology of Eurasia*, 1(13), 147–157.
- Meindl, R. S., & Lovejoy, C. O. (1985). Ectocranial suture closure: A revised method for the determination of skeletal age at death based on the lateral-anterior sutures. *American Journal of Physical Anthropology*, 68, 57–66. <https://doi.org/10.1002/ajpa.1330680106>
- Mengarelli, R. (1902). *La necropoli barbarica di Castel Trosino presso Ascoli Piceno*. Roma.
- Micarelli, I., Paine, R. R., Tafuri, M. A., & Manzi, G. (2021). Conservation and reassessment of an overlooked skeletal collection preserved since 1901 at the Museum of Anthropology “G. Sergi”, Rome. *Conservation Science in Cultural Heritage*, 20, 65–78. <https://doi.org/10.6092/issn.1973-9494/12788>
- Nerlich, A. G., Zink, A., Szeimies, U., Hagedorn, H. G., & Rösing, F. W. (2003). Perforating skull trauma in ancient Egypt and evidence for early neurosurgical therapy. In R. Arnott, S. Finger, C. Smith, & R. Arnott (Eds.), *Trepanation history, discovery? Theory* (pp. 191–202). Swets & Zeitlinger Publishers.
- Perrot, R. (1982). Les blessures et leur traitement au Moyen-Age d'après les textes médicaux anciens et les vestiges osseux, grande région Lyonnaise. Diss. Université Claude Bernard: Lyon.
- Profumo, M. C., & Staffa, A. R. (2007). Le necropoli altomedievali ed il sito fortificato di Castel Trosino. In E. Catani & G. Paci (Eds.), *La Salaria in età tardoantica e altomedievale (Atti del Convegno)*, Roma (pp. 393–394). Arbor Sapientiae.
- Redfern, R., & Roberts, C. (2019). Chapter 9 – Trauma. In J. Buikstra (Ed.), *Ortner's identification of pathological conditions in human skeletal remains* (pp. 211–284). Academic Press.
- Ricci, M., & Paroli, L. (2007). *La necropoli altomedievale di Castel Trosino*. All'insegna del Giglio.
- Riccomi, G., Bareggi, A., Minozzi, S., Aringhieri, G., Pellegrino, C., & Giuffra, V. (2022). Paleopathology of Endocranial lesions: A possible Case of a middle meningeal artery aneurysm in an Etruscan child from Pontecagnano (southern Italy). *World Neurosurgery*, 158, 168–173. <https://doi.org/10.1016/j.wneu.2021.11.093>
- Rubini, M., & Zaio, P. (2011). Warriors from the east. Skeletal evidence of warfare from a Lombard-Avar cemetery in Central Italy (Campochiaro, Molise, 6th–8th century AD). *Journal of Archaeological Science*, 38(7), 1551–1559. <https://doi.org/10.1016/j.jas.2011.02.020>
- Schindelin, J., Arganda-Carreras, I., Frise, E., Kaynig, V., Longair, M., Pietzsch, T., Preibisch, S., Rueden, C., Saalfeld, S., Schmid, B., Tinevez, J. Y., White, D. J., Hartenstein, V., Eliceiri, K., Tomancak, P., & Cardona, A. (2012). Fiji: An open-source platform for biological-image analysis. *Nature Methods*, 9, 676–682. <https://doi.org/10.1038/nmeth.2019>
- Sergi, S. (1902). Appendice, Nota sui teschi di Castel Trosino. In R. Mengarelli (Ed.), *La necropoli barbarica di Castel Trosino presso Ascoli Piceno* (pp. 189–192). Accademia dei Lincei.
- Strani, F., Profico, A., Manzi, G., Pushkina, D., Raia, P., Sardella, R., & DeMiguel, D. (2018). MicroWeaR: A new R package for dental micro-wear analysis. *Ecology and Evolution*, 8, 7022–7030. <https://doi.org/10.1002/ece3.4222>
- Toyne, J. M. (2011). Possible cases of scalping from pre-Hispanic highland Peru. *International Journal of Osteoarchaeology*, 21(2), 229–242. <https://doi.org/10.1002/oa.1127>
- Venchiariutti, W. (2006). Longobardi e Longobardismi, Spunti e suggestioni antropologiche nelle consuetudini del Cremasco, Insula Fulcheria XXXVI, Comune di Crema. <https://www.comunecrema.it/insula-fulcheria/insula-fulcheria-indice-completo/insula-fulcheria-rivista-n-xxxvi-2006>
- Verano, J. W. (2017). Reprint of-differential diagnosis: Trepanation. *International Journal of Paleopathology*, 19, 111–118. <https://doi.org/10.1016/j.ijpp.2017.03.004>
- Walker, P. L., Dean, G., & Shapiro, P. (1991). Estimating age from tooth wear in archaeological populations. In M. A. Kelley & C. S. Larsen (Eds.), *Advances in dental anthropology* (pp. 169–178). Wiley-Liss.
- Ye, Y., Gao, W., Xu, W., Gong, J., Qiu, M., Long, L., & Ding, J. (2022). Anatomical study of arachnoid granulation in superior sagittal sinus correlated to growth patterns of Meningiomas. *Frontiers in Oncology*, 12, 848851. <https://doi.org/10.3389/fonc.2022.848851>

How to cite this article: Micarelli, I., Strani, F., Bedecarrats, S., Bernardini, S., Paine, R. R., Bliquez, L., Giostra, C., Gazzaniga, V., Tafuri, M. A., & Manzi, G. (2023). An unprecedented case of cranial surgery in Longobard Italy (6th–8th century) using a cruciform incision. *International Journal of Osteoarchaeology*, 1–9. <https://doi.org/10.1002/oa.3202>