



HAL
open science

Two RFC1 splicing variants in CANVAS

Sacha Weber, Giulia Coarelli, Anna Heinzmann, Marie-Lorraine Monin, Nicolas Richard, Marion Gerard, Alexandra Durr, Vincent Huin

► **To cite this version:**

Sacha Weber, Giulia Coarelli, Anna Heinzmann, Marie-Lorraine Monin, Nicolas Richard, et al.. Two RFC1 splicing variants in CANVAS. *Brain - A Journal of Neurology*, 2022, <10.1093/brain/awac466>. <hal-03920011>

HAL Id: hal-03920011

<https://normandie-univ.hal.science/hal-03920011v1>

Submitted on 12 Jan 2024

HAL is a multi-disciplinary open access archive for the deposit and dissemination of scientific research documents, whether they are published or not. The documents may come from teaching and research institutions in France or abroad, or from public or private research centers.

L'archive ouverte pluridisciplinaire HAL, est destinée au dépôt et à la diffusion de documents scientifiques de niveau recherche, publiés ou non, émanant des établissements d'enseignement et de recherche français ou étrangers, des laboratoires publics ou privés.



HAL Authorization

1 LETTER TO THE EDITOR

2 **Two *RFC1* splicing variants in CANVAS**

3 Sacha Weber,^{1,2} Giulia Coarelli,³ Anna Heinzmann,³ Marie-Lorraine Monin,⁴ Nicolas
4 Richard,⁵ Marion Gerard,¹ Alexandra Durr³ and Vincent Huin⁶

5

6 **Author affiliations:**

7 1 Medical Genetics Department, Caen University Hospital, Caen, France

8 2 Neurology Department, Caen University Hospital, Caen, France

9 3 Sorbonne Université, Paris Brain Institute, APHP, INSERM, CNRS, Paris, France

10 4 Reference Center for Rare "Neurogenetic" Diseases, Department of Medical Genetics,
11 Pellegrin Hospital, Bordeaux University Hospital, Bordeaux, France

12 5 Department of Genetics, Normandy University, UNICAEN, Caen University Hospital, EA
13 7450 BioTARGen, F-14000 Caen, France

14 6 Univ. Lille, Inserm, CHU Lille, U1172 - LilNCog (JPARC) - Lille Neuroscience &
15 Cognition, F-59000 Lille, France

16

17 Correspondence to: Dr Vincent Huin

18 Lille Neuroscience & Cognition, F-59000 Lille, France

19 E-mail: vincent.huin@inserm.fr

20

21 **ORCID:**

22 Sacha Weber = 0000-0001-9363-5141

23 Giulia Coarelli = 0000-0002-7824-8343

24 Anna Heinzmann = 0000-0001-8007-2597

25 Marie-Lorraine Monin = 0000-0002-0116-036X

26 Nicolas Richard = 0000-0003-0702-7399

1 Marion Gerard = 0000-0003-2319-0305

2 Alexandra Durr = 0000-0002-8921-7104

3 Vincent Huin = 0000-0001-8201-5406

4

5 We read with great interest the original article “*RFC1* nonsense and frameshift
6 variants cause CANVAS: clues for an unsolved pathophysiology” by Benkirane *et al.*¹

7 Biallelic *RFC1* (AAGGG)_n expansions are responsible for cerebellar ataxia,
8 neuropathy, and vestibular areflexia syndrome (CANVAS), a frequent cause of late-onset
9 ataxia, with sporadic or autosomal recessive inheritance.² Since their discovery, other
10 pathogenic pentanucleotide motifs have been reported in the literature.³⁻⁵

11 The authors reported two cases of heterozygous compound truncating variants of
12 *RFC1* in two patients with CANVAS. They were null variants (one frameshift and one
13 nonsense variant) and were associated with a classical *RFC1* (AAGGG)_n intronic expansion
14 in *trans*. For the first time, Benkirane *et al.*¹ succeeded in advancing our understanding of the
15 pathophysiology of CANVAS, which, until now, has remained elusive. The authors showed a
16 decrease in *RFC1* mRNA levels in the patients’ blood, supporting the hypothesis of a loss-of-
17 function of the gene as the cause of the disease. Here, we report genetic and clinical data from
18 two additional unrelated families with heterozygous compound expansions in *RFC1* and loss-
19 of-function pathogenic variants.

20

21 **Case reports**

22 **Case 1**

23 A 62-year-old French man who was referred to the Caen University Hospital presented
24 with progressive proprioceptive ataxia associated with cerebellar signs and self-reported hand
25 myotonia. His familial history revealed possible late-onset gait problems in his mother and
26 maternal grandfather. He started at age 37 with gait problems which were worse in the dark.
27 He had a chronic and unexplained cough since age 20. Clinical examination showed severe
28 proprioceptive ataxia, absent deep tendon reflexes, a flexor plantar response, and sensory
29 problems, with a decreased tactile sense and abolition of the vibration sense of the
30 extremities. He had a cerebellar syndrome, shown by a SARA (Scale for the Assessment and

1 Rating of Ataxia) score of 26/40, with action tremor and dysarthria. He exhibited vertical
2 nystagmus on videonystagmography, diplopia in the lateral view, a positive head impulse test,
3 and abolished visually-enhanced vestibulo-ocular reflex. He suffered from severe
4 dysautonomia with orthostatic hypotension, abnormal secretion and vomiting of mucus,
5 constipation, dysuria, erectile dysfunction, tachycardia, excessive sweating, and a disorder of
6 thermoregulation, with an intolerance to hot humid weather. He had normal hearing but had
7 had tinnitus since age 55. Myotonia was not found during the examination nor by EMG and
8 he was diagnosed instead with myokymia. He developed akineto-rigid syndrome at age 56
9 and his gait problems and orthostatic hypotension progressively worsened and confined the
10 patient to bed or a wheelchair at age 60.

11 EMG at age 50 showed sensory neuropathy associated with moderate reductions in
12 motor action potentials of the lower limbs. EMG at age 57 confirmed the previous results and
13 showed a small decrease in motor potentials in the lower limbs associated with prolonged
14 distal motor latency in the upper limbs. Brain MRI showed mild cerebellar atrophy involving
15 the vermis. Dopamine transporter (DaT) SPECT showed bilateral and symmetrical reduction
16 of striatal fixation. Computed tomography of the chest, abdomen, and pelvis was normal. The
17 patient fully met the criteria for the diagnosis of clinically definitive CANVAS.⁶

18 We excluded acquired or metabolic causes of cerebellar atrophy, including infectious,
19 inflammatory, immune, parental, and neo- and paraneoplastic causes. Previous genetic
20 screening of the *POLG* and *DMPK* genes, dystrophic myotonia and episodic ataxia panel
21 genes (*CACNA1A*, *CLCN1*, *KNJ2*, *KCNIA*) by next-generation sequencing (NGS), and
22 polyglutamine expansions in the *ATXN1*, *ATXN2*, *ATXN3*, *CACNA1A*, *ATXN7*, and *TBP*
23 genes were negative. The *FMRI* locus was normal. Analysis of mitochondrial DNA by NGS
24 was normal. Screening for Friedreich ataxia showed an expanded allele of ≈ 1000 triplets and
25 a normal allele without other pathogenic variants shown by Sanger sequencing and MLPA of
26 the *FXN* gene. We screened the *RFC1* gene by fluorescent duplex PCR, repeat primer-PCR,
27 and LR-PCR with Southern-blotting of the PCR product, as previously described.⁷ The patient
28 carried an expanded (AAGGG)_n allele and an allele of normal length with 10 pentaplets.
29 Finally, we performed exome sequencing and found a heterozygous splicing variant in the
30 canonical acceptor site of exon 19 in the *RFC1* gene: NM_002913.5: c.2535+2T>C, p?.
31 Segregation analyses performed on the proband's mother and son confirmed the compound
32 heterozygous status (Figure 1).

33

1 Case 2

2 A 38-year-old French man with a personal history of rheumatoid arthritis and no
3 family history of neurodegenerative diseases presented with cerebellar and proprioceptive
4 ataxia at the Neurogenetics Reference Center for Rare Diseases at the Salpêtrière Hospital in
5 Paris. He started at age 32 with gait problems. Clinical examination showed a decreased sense
6 of vibration at the ankles (2/8), cerebellar ataxia, and cerebellar dysarthria, with a SARA
7 score of 8.5/40. He had brisk deep tendon reflexes and fasciculations of the lower limbs. He
8 had suffered from a chronic and unexplained cough since age 18.

9 EMG showed generalized sensory neuronopathy. Somatosensory-evoked potentials
10 showed a somatosensory deficit. Eye movement recording showed dysmetric horizontal
11 saccades, decreased velocity of vertical saccades, numerous square waves, and downbeat
12 nystagmus. Brain MRI showed cerebellar atrophy of both the vermis and cerebellar
13 hemispheres. Previous genetic screening, including for Friedreich ataxia and the search for
14 polyglutamine expansions in the *ATXN1*, *ATXN2*, *ATXN3*, *CACNA1A*, *ATXN7*, and *TBP*
15 genes showed no abnormal expansions. *RFC1* gene screening showed an expanded
16 (AAGGG)_n allele and an allele of normal length with nine pentaplets. Exome sequencing
17 showed a heterozygous splicing variant in the canonical acceptor site of exon 20 in the *RFC1*
18 gene: NM_002913.5: c.2690+1G>A, p.? (Figure 1).

19

20 Discussion

21 Here, we confirm the report of Benkirane *et al.*¹ by adding two additional patients
22 whose phenotypes are characteristic of *RFC1*-related disorders and who carry heterozygous
23 compound mutations in the *RFC1* gene. Such compound heterozygous mutations are
24 reminiscent of the loss-of-function mutations associated with (GAA)_n intronic expansion in
25 the *FXN* gene, responsible for Friedreich ataxia, for which the phenotype of late onset forms
26 is very similar to that of CANVAS.^{8,9} Consistent with this hypothesis, we noted that the *RFC1*
27 gene is intolerant to loss-of-function variants based on the constraint score in the gnomAD
28 database (loss-of-function observed/expected upper bound fraction = 0.305). There are only
29 121 allele counts with a loss-of-function variant recorded in gnomAD v2.1.1, including three
30 counts with disputable annotation or quality and 98 counts of a splice variant with an
31 uncertain loss-of-function effect due to weak/unrecognized splice rescue. Moreover, Zhao *et*
32 *al.*¹⁰ showed that *RFC1*^{-/-} knock-out mice are embryonic lethal.

1 The two patients have first motor neuron signs (brisk deep tendon reflexes in case 2)
2 or second motor neuron signs (myokymia in case 1 and fasciculations in case 2). Mixed motor
3 and sensory neuropathy was also observed in case 1. This is consistent with our previous
4 report of frequent motor neuron involvement in *RFC1* patients.⁷ Interestingly, the two cases
5 that we report had earlier onset than that previously reported for classical CANVAS. The
6 second difference is the presence of an MSA-like phenotype in the first case, not present in
7 the second, indicating that other factors are involved in this phenotypic expression of *RFC1*-
8 related disorders.

9 10 **Data availability**

11 The data that support the findings of this study are available from the corresponding authors
12 upon reasonable request.

13 14 **Acknowledgements**

15 We are grateful to the patients for their participation in this study.

16 17 **Funding**

18 This work was funded by the University of Lille, the “Institut National de la Santé et de la
19 Recherche Médicale” (INSERM), the Lille University Hospital, the Association des Aidants
20 et Malades à Corps de Lewy (A2MCL) charity, and the France Alzheimer charity. This work
21 was also supported by grants from the Programs d’Investissements d’Avenir LabEx
22 (excellence laboratory) DISTALZ (Development of Innovative Strategies for a
23 Transdisciplinary approach to ALZheimer’s disease).

24 25 **Competing interests**

26 The authors report no competing interests.

27

28

1 **References**

- 2 1 Benkirane M, Da Cunha D, Marelli C, et al. RFC1 nonsense and frameshift variants cause
3 CANVAS: clues for an unsolved pathophysiology. *Brain*. Published online July 27,
4 2022:awac280. doi:10.1093/brain/awac280
- 5 2 Cortese A, Simone R, Sullivan R, et al. Biallelic expansion of an intronic repeat in RFC1 is
6 a common cause of late-onset ataxia. *Nat Genet*. 2019;51(4):649-658. doi:10.1038/s41588-
7 019-0372-4
- 8 3 Tsuchiya M, Nan H, Koh K, et al. RFC1 repeat expansion in Japanese patients with late-
9 onset cerebellar ataxia. *J Hum Genet*. 2020;65(12):1143-1147. doi:10.1038/s10038-020-0807-
10 x
- 11 4 Beecroft SJ, Cortese A, Sullivan R, et al. A Māori specific RFC1 pathogenic repeat
12 configuration in CANVAS, likely due to a founder allele. *Brain*. 2020;143(9):2673-2680.
13 doi:10.1093/brain/awaa203
- 14 5 Miyatake S, Yoshida K, Koshimizu E, et al. Repeat conformation heterogeneity in
15 cerebellar ataxia, neuropathy, vestibular areflexia syndrome. *Brain*. 2022;145(3):1139-1150.
16 doi:10.1093/brain/awab363
- 17 6 Szmulewicz DJ, Roberts L, McLean CA, MacDougall HG, Halmagyi GM, Storey E.
18 Proposed diagnostic criteria for cerebellar ataxia with neuropathy and vestibular areflexia
19 syndrome (CANVAS). *Neurol Clin Pract*. 2016;6(1):61-68.
20 doi:10.1212/CPJ.0000000000000215
- 21 7 Huin V, Coarelli G, Guemy C, et al. Motor neuron pathology in CANVAS due to RFC1
22 expansions. *Brain*. 2022;145(6):2121-2132. doi:10.1093/brain/awab449
- 23 8 Campuzano V, Montermini L, Moltò MD, et al. Friedreich's Ataxia: Autosomal Recessive
24 Disease Caused by an Intronic GAA Triplet Repeat Expansion. *Science*.
25 1996;271(5254):1423-1427. doi:10.1126/science.271.5254.1423
- 26 9 Galea CA, Huq A, Lockhart PJ, et al. Compound heterozygous FXN mutations and clinical
27 outcome in friedreich ataxia: Insights From Frataxin Structure and Function. *Ann Neurol*.
28 2016;79(3):485-495. doi:10.1002/ana.24595
- 29 10 Zhao R, Russell RG, Wang Y, et al. Rescue of Embryonic Lethality in Reduced Folate
30 Carrier-deficient Mice by Maternal Folic Acid Supplementation Reveals Early Neonatal

1 Failure of Hematopoietic Organs. Journal of Biological Chemistry. 2001;276(13):10224-
2 10228. doi:10.1074/jbc.C000905200

3

4

ACCEPTED MANUSCRIPT

1 **Figure legend**

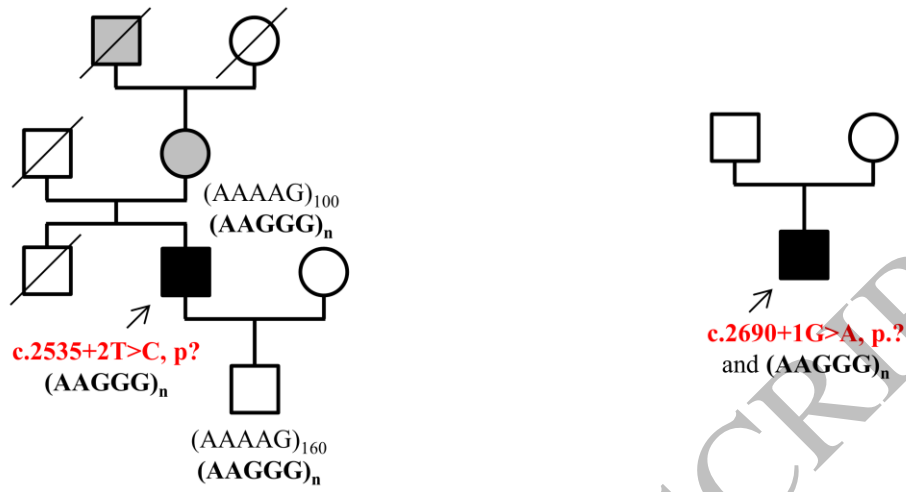
2 **Figure 1 Pedigrees and *RFC1* variants of the two families.** **A.** Pedigrees of family1 (left)
3 and family 2 (right). The probands are indicated by an arrow. Filled black symbols denote
4 clinically affected members. Grey filled symbols denote members clinically affected by late-
5 onset gait problems but who had not been examined by one of us. Numbers indicate the age at
6 onset in years for neurological signs (cough excluded). Open symbols indicate unaffected
7 individuals. A forward slash indicates deceased individuals. Intronic (AAGGG)_n *RFC1*
8 expansions are shown in bold. The two *RFC1* splicing variants are shown in bold and in red.
9 **B.** Electropherograms of the heterozygous splicing variants in the *RFC1* gene in the probands
10 from family 1 (left) and family 2 (right).

11

12

ACCEPTED MANUSCRIPT

A



B



Figure 1

160x123 mm (3.8 x DPI)

1
2
3