



HAL
open science

Gastric motility disorders and their endoscopic and surgical treatments other than bariatric surgery

H. Soliman, G. Mariano, H. Duboc, D. Giovinazzo, B. Coffin, G. Gourcerol,
D. Moszkowicz

► **To cite this version:**

H. Soliman, G. Mariano, H. Duboc, D. Giovinazzo, B. Coffin, et al.. Gastric motility disorders and their endoscopic and surgical treatments other than bariatric surgery. *Journal of Visceral Surgery*, 2022, 159 (1), pp.S8-S15. 10.1016/j.jviscsurg.2022.01.003 . hal-03592525

HAL Id: hal-03592525

<https://normandie-univ.hal.science/hal-03592525v1>

Submitted on 22 Jul 2024

HAL is a multi-disciplinary open access archive for the deposit and dissemination of scientific research documents, whether they are published or not. The documents may come from teaching and research institutions in France or abroad, or from public or private research centers.

L'archive ouverte pluridisciplinaire **HAL**, est destinée au dépôt et à la diffusion de documents scientifiques de niveau recherche, publiés ou non, émanant des établissements d'enseignement et de recherche français ou étrangers, des laboratoires publics ou privés.



Distributed under a Creative Commons Attribution - NonCommercial 4.0 International License

Gastric motility disorders and their endoscopic and surgical treatments other than bariatric surgery

Heithem Soliman¹, Germano Mariano², Henri Duboc^{3, 4}, Davide Giovonazzo², Benoit Coffin⁴, Guillaume Gourcerol¹, David Moszkowicz^{2, 3}

1 : Rouen University Hospital Center - INSERM UMR 1073 – CIC-CRB 1404, Rouen, France

2 : General and digestive surgery department, AP-HP, Louis Mourier Hospital, DMU ESPRIT-GHU AP-HP, Nord-Université de Paris, 92700 Colombes, France

3 : University of Paris, Inflammation Research Center, Inserm UMRS 1149, 75018 Paris, France

4 : Department of Hepato Gastro Enterology, Louis Mourier Hospital, DMU ESPRIT - GHU (AP-HP) - 92700, Colombes, France

Liens d'intérêts : Aucun auteur ne déclare de lien d'intérêt en rapport avec l'article.

Auteur correspondant: Dr David MOSZKOWICZ, General and digestive surgery department, Hôpital Louis-Mourier, 178 rue des Renouillers, 92700 Colombes,

E-mail : david.moszkowicz@aphp.fr

Abstract

Gastroparesis is the most common gastric motility disorder. The cardinal symptoms are nausea, vomiting, gastric fullness, early satiety, or bloating, associated with slow gastric emptying in the absence of mechanical obstruction. Delayed gastric emptying is demonstrated by a gastric emptying scintigraphy or by a breath test. Gastroparesis can be idiopathic, post-operative, secondary to diabetes, iatrogenic, or post-infectious. Therapeutic care must be multidisciplinary including nutritional, medical, endoscopic and surgical modes. The complications of delayed gastric emptying must be sought and addressed, particularly malnutrition, in order to identify and correct vitamin deficiencies and fluid and electrolyte disturbances. An etiology should be identified and treated whenever possible. Improvement in symptoms can be treated by dietary regimes and pharmaceutical treatments, including prokinetics. If these are not effective, specialized endoscopic approaches such as endoscopic or surgical pyloromyotomy aim at relaxing the pyloric sphincter, while the implantation of an electrical stimulator of gastric muscle should be discussed in specialized centers.

Keywords: gastric bypass; gastroparesis; G-POEM; gastric pacemaker; gastric electrical stimulation; endoscopic treatment.

Introduction

Gastric motility disorders may result in multiple non-specific digestive symptoms, such as nausea, vomiting, epigastric pain, or early satiety. Gastroparesis, defined by slow gastric emptying in the absence of mechanical obstruction and resulting in this combination of symptoms, is the most common of these disorders [1]. It can occur secondary to diabetes, or after surgery, but in 40% of cases, no etiology can be identified.

The severe forms can lead to an impaired quality of life, and to marked food intolerance and malnutrition [2]. Numerous endoscopic and surgical treatment options have been developed in recent years, aimed at improving the management of patients who are refractory to medical treatment. The objective of this review is to describe the clinical presentation of gastroparesis, to detail the diagnostic modalities, and then the multidisciplinary medical, nutritional, endoscopic and surgical management of this motility disorder.

Epidemiology

The prevalence of gastroparesis is difficult to assess since it is generally underdiagnosed, while its non-specific symptoms overlap with those of functional dyspepsia. Epidemiological data come mainly from the United States and, in particular, from a Mayo Clinic population study in Minnesota that evaluated the prevalence at 0.02% of the population [3]. The study by Rey *et al.* attempted to estimate the prevalence of undiagnosed disease and indicated that the prevalence could reach 1.8% of the general population [4]. Recently, an epidemiological study in the United Kingdom confirmed a similar diagnostic prevalence in Europe, estimated at 13.8 per 100,000 inhabitants [5]. These studies also revealed the incidence and prevalence to be two to four times higher in women, with no explanation for this gender inequality [3,5].

Data on life expectancy in gastroparesis are conflicting. Thus, in the study by Jung *et al.*, the survival of patients with gastroparesis was reduced compared to

subjects matched for age and gender [3]. However, other studies in patients with diabetic gastroparesis showed no increase in mortality up to 25 years after diagnosis, although morbidity was greater with more hospitalizations and emergency room visits [6]. Also, the number of hospitalizations is increasing sharply, estimated at + 160% between 1995 and 2004, due to an increase in the incidence of diabetes and a better ability to diagnose gastroparesis [7]. Finally, a quality of life study carried out on more than 1400 gastroparetic patients, showed that 35% judged their quality of life unsatisfactory, and 32% judged it mediocre [2].

Clinical presentation

The most common clinical symptoms described in gastroparesis are nausea (92% of patients), vomiting (84%), bloating (75%), early satiety (60%), and abdominal pain or discomfort (55%) [8]. Other studies suggest that abdominal pain is often underestimated and may affect up to 90% of patients, sometimes with disabling nocturnal pain that requires opioid treatment [9]. Symptoms are usually gradual in onset, but abrupt onset can be seen in some cases of idiopathic gastroparesis or after an episode of viral infection [10]. The diagnosis can also be made when a patient presents with an acute complication of disease such as esophagitis, Mallory-Weiss syndrome, aspiration pneumonia or gastric bezoar. Finally, long-term complications must be systematically sought, particularly undernutrition or dehydration, which are signs of severe disease [1]. These complications should be sought particularly in obese patients, who represent up to 50% of patients with gastroparesis in some studies [11]. Several scores have been developed to assess the frequency and severity of the disease. The most reproducible score at present is the Gastroparesis Cardinal Symptom Index (GCSI) assessing nine items (nausea, regurgitation, vomiting, gastric fullness, early satiety, post-prandial fullness, loss of appetite, bloating, abdominal distension) [12]. This questionnaire is reproduced in Appendix 1, Results are measured on a scale of 0 to 5; a score > 2 is considered as severe.

This score is also used in clinical trials to assess the response to treatments, and a decrease of 0.75 to 1 point in the score is considered effective therapy [13]. However, the GCSI has no diagnostic value, and there is currently no threshold to indicate the need for further investigation.

Etiologies

The diagnosis of gastroparesis is often suggested by the clinical context. Diabetes is a common cause, accounting for one-third of cases [14]. The cumulative risk of gastroparesis over 10 years has been estimated to be 5% in patients with type 1 diabetes and 1% in patients with type 2 diabetes [15]. The presence of diabetic gastroparesis is often associated with other complications of diabetes, particularly diabetic retinopathy, peripheral neuropathy, and poorly controlled diabetes with increased glycated hemoglobin (HgbA1C) levels [16]. Thirteen percent of gastroparesis occurs in a post-operative context. This entity should be distinguished from acute gastric distention, which can also occur after any abdominal surgery, or in the context of compartment syndrome. Acute gastric dilation is rare. There are many published case reports, but few series reported in the literature. It is defined by major gastric distension visible on imaging, with air and liquid contents of the stomach. This complication, similar to post-operative ileus, requires urgent medical treatment with nasogastric tube decompression. Delayed diagnosis can lead to vomiting or even gastric ischemia. The pathophysiology of this entity is not clear, although hyperglycemia, or gastroparesis may be risk factors [17]. Post-operative gastroparesis is defined by long-term persistence of delayed emptying of solids. It is often linked to vagus nerve injury and had thus been described in the aftermath of vagotomy for peptic ulcer disease, a procedure that is now no longer performed [18]. The current surgeries that predispose to vagal injury include anti-reflux surgeries, esophageal or gastric resection for cancer, and rarely bariatric surgeries [19]. Gastroparesis is also common following pancreateo-duodenectomy, but is most often transient [20].

The other causes are rarer. Medications may be implicated, particularly opioids. These medications cause a decrease in contractility of the gastric antrum and an increase in pyloric pressure. Post-viral gastroparesis has been described after infections with Epstein-Barr, herpes, or cytomegalovirus, but these seem to regress spontaneously within a year of infection [21]. Other systemic or neurodegenerative diseases can also be involved, such as scleroderma, or Parkinson's disease. Here, gastroparesis is thought to be linked to damage to the myenteric nervous system, or smooth muscle cells in the stomach. Finally, 40% of gastroparesis cases are idiopathic [14]. Of note, the consumption of tobacco or alcohol has not been associated with an increased risk of gastroparesis [11].

Definitive diagnosis

When symptoms suggestive of gastroparesis are present, the diagnosis should be confirmed by objective measurement of gastric emptying. An upper gastrointestinal endoscopy should be performed first to eliminate any mechanical cause for the symptoms. If gastroscopy is normal, gastric motility should then be evaluated, either by a radionuclide scan of gastric emptying or by a breath test after ingestion of a radioactive carbon isotope.

A radionuclide scintigraphy of gastric emptying is currently the gold standard [22]. The fasting patient ingests a solid meal labeled with Technetium⁹⁹ and a liquid meal labeled with Indium¹¹¹. The standardized content of the meal contains a appropriate quantity of calories and fat [22]. Images are obtained over at least four hours with image acquisition at 0, 1, 2 and 4 hours. A gastric retention rate >60% at two hours or >10% at four hours is diagnostic of gastroparesis [23]. The severity of gastroparesis is also classified according to the results: a retention rate of 10 to 15% at four hours constitutes slight impairment, while 15 to 35% defines moderate impairment, and >35% defines severe impairment [24]. However, use of scintigraphy is limited, mostly due to its low availability.

The carbon¹³ breath test is an alternative diagnostic test [25]. This test measures the level of exhaled C¹³ reflecting the amount of C¹³ incorporated in the meal, and how much is absorbed after gastric passage. The test is also performed after an eight-hour fasting period. The patient usually ingests C¹³, in an octanoic acid meal or spirulina. Respiratory samples are collected before meals, and thereafter at regular intervals, usually every 30 minutes for four hours. This helps to estimate the half-life of gastric emptying [26]. More widely available and having less radiation exposure than scintigraphy, this test nevertheless remains an indirect measure of gastric emptying, and results can be altered by respiratory or hepatic disease, by heart failure, or by intestinal malabsorption.

Recently, the United States Food and Drug Administration (FDA) approved the SmartPill™ capsule for the measurement of gastric emptying. This capsule is different from the recording video capsule used in everyday practice for assessment of the small bowel. It measures pressure, pH and temperature, and enables measurement of the gastric or intestinal transit time. However, reservations have been expressed on the reliability of these results, since the capsule, being a large and non-digestible object, does not seem to leave the stomach under normal conditions after eating, but is rather expelled by powerful post prandial antral contractions [27].

Other possibilities in the differential diagnoses of gastroparesis should not be overlooked. If symptoms are suggestive but gastric emptying is normal, the diagnosis of functional dyspepsia should be considered. The symptoms are indeed the same for these two entities, except for vomiting, which is absent in dyspepsia. A recent study showed that, at an advanced stage, these two diagnoses were indistinguishable, particularly owing to the intrinsic variability of gastric emptying over time [28]. Repeated vomiting should suggest the possibility of cannabis use, the cannabinoid hyperemesis syndrome, in which cyclic vomiting syndrome presents as repeated attacks spaced apart by asymptomatic intervals. Except during attacks, there is no change in gastric emptying. Finally, eating disorders, especially anorexia nervosa, can mimic

gastroparesis and lead to impaired gastric emptying, which is often normalized after correction of malnutrition [8].

Treatment (Figure 1)

Nutritional care

Dietary measures are the first-line treatment of gastroparesis. Oral feeding is always preferred when possible. Vitamin and electrolyte deficiencies should be detected and repleted. Since early satiety is a frequent patient complaint, meals should be split with the addition of snacks to daily meals to maintain a satisfactory caloric intake [8]. Clinical trials have shown the value of a low-fat, low-fiber diet with small particles [29]. Gastric emptying is more rapid with these foods, and these measures have led to symptomatic improvement in patients with diabetic gastroparesis [30]. In patients with severe impairment of gastric emptying, a blenderized diet may be necessary, with fortified soups and food supplements, since emptying of fluids is often less impaired.

Finally, for patients with severe undernutrition or recurrent fluid and electrolyte disturbances, a feeding jejunostomy may be necessary. It helps reduce symptoms and reduce the number of hospitalizations, by feeding distal to the affected stomach [31]. Tolerance of this feeding route should be checked by initial placement of a naso-jejunal tube, since small bowel dysmotility may also be present in some patients [8]. The preferred technique is percutaneous endoscopic jejunostomy (PEJ), which can be successfully performed in 78.6% of attempts. However, the rate of severe complications requiring surgery reached 18% at one year in a series of 12 patients [32]. An endoscopic alternative is the placement of an endoscopic gastrostomy with jejunal extension (PEG-J), which is technically simpler. However, the risk of jejunostomy tube migration is high, with an estimated re-operation rate of 39.5%, and the skin insertion site often becomes irritated due to leakage of acidic gastric contents [33]. The choice of technique for jejunostomy should also be adapted to the patient's surgical history,

and surgical placement may then be necessary. These techniques have a success rate of 53%, and the choice of technique is therefore guided by the complication rate [34]. Placement of a tube by a tunneled Witzel enterotomy has a 2% risk of complications such as small bowel obstruction and surgical site infection [35]. Needle catheter jejunostomy can be performed laparoscopically, with a similar complication rate, and allows for faster return of intestinal motility [34]. Finally, parenteral nutrition should only be considered as a last resort.

Medical treatment

Treatment of the underlying cause also slows the progression of gastroparesis. Thus, in diabetic patients, glycemic imbalance contributes to slow gastric emptying. Improvement of glycemic control with an insulin pump has been shown to be effective in optimizing symptoms of gastroparesis [36]. It should be noted that gastroparesis can also impair the absorption of oral medications and delay post-prandial absorption from meals, thus contributing to blood sugar imbalances [1]. Glucagon-like Peptide 1 (GLP-1) analogues should also be avoided since they slow gastric emptying [29]. Other treatments that cause slow gastric emptying, especially opioids, should be avoided.

As each of these measures often proves insufficient, combined drug treatments should be considered [24]. The medications that have best demonstrated their effectiveness are prokinetics, first and foremost dopamine D2 receptor antagonists [37]. These accelerate gastric emptying by increasing gastric contractions and they also have an antiemetic effect. Metoclopramide is the only treatment validated by the FDA for this indication, and the sublingual route of administration is preferred to circumvent bioavailability problems associated with the oral route in gastroparesis. However, since this medication crosses the blood-brain barrier, the risk of extrapyramidal syndrome and tardive dyskinesia should be monitored [38]. Domperidone has similar efficacy, and has been validated in several other countries, even though there may be cardiotoxicity with prolongation of the QT interval. Erythromycin, a Motilin agonist, has shown

similar short-term efficacy. Intravenous administration is more effective than oral administration [8]. However, drug side-effects are numerous, and treatment efficacy wanes in one-third of patients due to tachyphylaxis, warranting short-term prescriptions [39].

New prokinetics are also being evaluated. Thus, relamorelin, a ghrelin agonist that stimulates antral contractions, has shown an acceleration of gastric emptying, and a decrease in symptoms in patients with diabetic gastroparesis in a phase-2 study [40]. Prucalopride, a serotonin 5-HT₄ receptor agonist that is currently available in the treatment of refractory constipation, has also been shown to be effective in the treatment of idiopathic gastroparesis in a series of 34 patients [41].

If prokinetic treatments and dietary measures fail, other second-line symptomatic treatments can be combined to improve the patient's quality of life. For nausea and vomiting, several anti-emetics have been used such as promethazine, ondansetron, or even Aprepitant [1]. These treatments should be reserved for moderate to severe forms of vomiting, and it is necessary to take their side effects into consideration. Tricyclic antidepressants, such as amitriptyline, can be used to treat vomiting and epigastric pain, however, their effectiveness remains controversial in patients with gastroparesis [42]. For persistent pain, tramadol is preferred, since it has shown clinical benefit without impairing gastric emptying, and results in fewer hospitalizations and less nausea and vomiting compared to more potent opioids [43].

Endoscopic treatment

About 25% of patients do not have a satisfactory response to six months of correctly administered medical treatment and are therefore considered refractory. For these patients with moderate to severe refractory gastroparesis, several endoscopic management techniques have been developed. These techniques aim to treat pylorospasm, which is present in some patients with diabetic gastroparesis [44]. Pyloric dysfunction has recently been evaluated by the

Endoscopic Functional Lumen Imaging (EndoFLIP) system. This impedance planimetry system allows evaluation of the geometry and pressure of a sphincter. The EndoFLIP catheter, which has an inflatable balloon and a pressure sensor, is passed through the working channel of the gastroscope. It was initially designed for the assessment of the lower esophageal sphincter (LES) in achalasia, but has also been studied in gastroparesis. It shows that the resting pyloric pressure is not altered, but that the compliance after balloon inflation is reduced in these patients, compared to healthy volunteers [45]. This technique could therefore be a predictive tool for selecting patients eligible for treatments that target the pylorus.

Another technique is the intra-pyloric injection of botulinum toxin. Several retrospective studies have shown clinical benefit with short-term symptomatic improvement in 50 to 77% of patients [46]. However, two randomized placebo-controlled studies have not shown its superiority over a placebo injection either at a dose of 100 or 200 IU [47,48]. Thus, the European Society for Gastrointestinal Endoscopy (ESGE) does not recommend this treatment [49]. It can be used in some patients to induce temporary remission while waiting for other treatment, but its effectiveness is only short-term, lasting no more than three months [1].

Balloon dilation of the pyloric sphincter has been little studied, and most studies published to date are retrospective [49]. These show efficacy in patients with pylorospasm post esophagectomy or gastrectomy with pyloric preservation, with clinical efficacy of up to 73% at two years [50]. A single prospective study evaluated this technique and revealed efficacy in the very short term (10 days) in ten patients with improvement in symptoms, gastric emptying, and pyloric compliance [45]. Several pyloric dilation techniques have been described in the literature using a 20mm hydrostatic balloon passed through the endoscope operating channel or using a 30mm pneumatic balloon (Rigiflex) positioned under fluoroscopic control; there was no observed difference in the rate of complications [51]. The larger 30mm balloon would reduce the number of

iterative dilations required. Recently, a new Esophageal Functional Lumen Imaging device (EsoFLIP) was developed that combines compliance measurement by EndoFLIP with therapeutic dilation. In a retrospective study, pyloric dilation to diameters up to 30mm has been used in 46 patients with refractory gastroparesis, and showed a decrease in symptoms and in gastric emptying time in 57% of patients at four months [52]. However, since these studies constitute a low level of evidence, this treatment is not currently recommended by the ESGE [49]

The use of a transpyloric stent was evaluated in a series of 33 patients and resulted in symptom improvement in 75% [53]. However, the risk of stent migration, which occurred in 59% of patients, is high, and this technique is therefore not recommended [49].

Recently, endoscopic pyloromyotomy, referred to as G-POEM (gastric per-oral endoscopic myotomy) was developed based on the results of endoscopic myotomy of the lower esophageal sphincter (LES) in achalasia. The technique described by Khashab *et al.* consists of making a submucosal tunnel in the antrum, then continuing this tunnel 3cm to the pyloric muscle [54]. The pyloric muscle must then be divided down to its termination at the duodenal bulb; the mucosal tunnel entrance is then closed with clips or endoscopic suture [49]. If there are no complications, the patient's diet can be gradually increased, first to a liquid diet on D1, and further advanced after hospital discharge. Several retrospective series have shown similar short-term results with an improvement in the symptoms of gastroparesis, and an acceleration of gastric emptying in 62 to 90% of patients [55,56]. Prospective studies are underway, and show encouraging results, with a 56% efficacy at one year, and with no difference in efficacy regardless of the cause of the gastroparesis [57]. The complication rate has been estimated between 4 and 10% depending on the study, mainly bleeding and a low risk of pneumoperitoneum (<1%) [56]. Randomized studies are awaited to confirm the effectiveness of this technique, but it is currently the endoscopic technique most strongly recommended by ESGE [49].

Surgical treatment

Surgical pyloroplasty is based on the same principle as the above-mentioned endoscopic techniques that target the pylorus. Performed laparoscopically, it consists of a longitudinal seromyotomy starting 3 cm proximal to the pyloric sphincter and extending distally 3 cm into the duodenum [58]. This technique has resulted in improvement in over 80% of patients in the short term in non-randomized trials. However, the high complication rate (up to 30%), and the recent development of G-POEM with a much lower complication rate, have decreased the use of this technique [59]. This technique may still be indicated in conjunction with another surgery performed for gastroparesis (jejunostomy, or gastric stimulator placement) [60]. Extramucosal biopsies of the gastric wall are also recommended during surgery, to achieve better understanding of the possible underlying histological abnormalities [34].

Another treatment option in patients with refractory gastroparesis is the implantation of an electrical gastric stimulator (EGS). The stimulator device is implanted into the abdominal wall, and the two permanent stimulation electrodes are laparoscopically implanted in the muscularis of the gastric greater curvature, approximately 10cm proximal to the pylorus [61]. The stimulator is then activated *via* an external programmer. EGS aims to correct the antral hypomotility described in gastroparesis, and thus accelerate gastric emptying. Settings are akin to neurostimulation with short low-intensity pulses (5mA, 14Hz, 330µs, on-cycle 0.1s, off-cycle 5s). Since these settings do not show any change in gastric emptying, the technique therefore seems to improve symptoms by acting on the fibers of the vagus nerve, and interfering with the transmission of efferent signals to the brain, thereby allowing better gastric accommodation and less visceral sensitivity [1].

The EGS device was approved by the FDA in 2000 as a humane measure to improve refractory chronic nausea and vomiting. The effectiveness of the device on symptoms was demonstrated in an initial randomized trial on 33 patients [61]. However, two subsequent randomized trials in patients with diabetic or idiopathic

gastroparesis could not confirm these results, due to lack of power, and the positive results from retrospective series were controversial [62,63]. Recently, a large multicenter cross-over randomized controlled study that included 218 patients confirmed the effectiveness of this technique to decrease vomiting [64]. No statistically significant difference was noted in gastric emptying or nutritional status between periods when the device was turned on or off. Likewise, improvement in quality of life did not reach statistical significance. These results were similar regardless of the cause of the gastroparesis. This technique might also be more effective when combined with a pylorotomy, but there are currently no criteria to guide the therapeutic strategy in patients [34].

The high cost of EGS implantation (cost of \$15,000 in France without insurance coverage, and \$24,000 in the United States) has also hampered its use. However, a recent cost-effectiveness study showed that EGS reduced the costs related to hospitalizations and sick leave by \$3,500 per patient per year, making the technique cost-effective by four years after implantation [65]. The mean lifespan of EGS after device implantation is estimated at 10 years, with long-term efficacy persisting in 50% of patients [66]. The complication rate was not negligible, however, and 25% of patients may have a paradoxical increase in abdominal pain. Therefore, this treatment is debatable in patients in whom the disease is mainly expressed by pain. The risk of surgical site infection site was 7% and this complication can require explantation of the device (2 to 8% depending on the study). The settings should be adjusted for optimal effect, altering the frequency and intensity of EGS before considering explantation [34,64].

Surgical gastrectomy may be considered as a last resort for patients who are resistant to all other therapies, who constituted 5% of patients in a tertiary care center [33]. Gastrectomy was shown to be effective in 67% of patients, with an estimated anastomotic leak rate of 5% [33]. One study that compared total gastrectomy (n = 125) to partial gastrectomy (n = 46) did not show any statistically significant difference between the two techniques [67]. Finally, in

obese patients, several series have shown that Roux-en-Y gastric bypass led to improvement of the symptoms of gastroparesis in 67 to 71% of patients. This option should therefore be considered in obese patients [34]. In our experience, we have extrapolated the management in obese patients and we now offer a Roux-en-Y gastric bypass with a 70 cm alimentary loop and gastro-jejunal anastomosis to a small gastric pouch for patients who have failed other invasive treatments. This controls vomiting and reduces of pain (results submitted).

Conclusion

Gastroparesis is a gastric motility disorder whose incidence is increasing. It can be responsible for severe complications. The diagnostic methods and risk factors have now been identified, but the pathophysiology still remains poorly understood. New therapeutic options have become available, such as G-POEM, or EGS, whose efficacy has now been established, thus expanding the therapeutic arsenal. However, the therapeutic strategy remains uncodified and predictive factors for the response to the various treatments are still not known. The development of tests to better assess pyloric dysfunction or antral hypomotility seem necessary and would allow better personalization of treatments for individual patients.

REFERENCES

1. Camilleri M, Chedid V, Ford AC, Haruma K, Horowitz M, Jones KL, *et al.* Gastroparesis. *Nat Rev Dis Primers*. 2018 Nov 1; 4(1): 41.
2. Yu D, Ramsey FV, Norton WF, Norton N, Schneck S, Gaetano T, *i* The Burdens, Concerns, and Quality of Life of Patients with Gastroparesis. *Dig Dis Sci*. 2017 Apr; 62(4): 879–93.
3. Jung H-K, Choung RS, Locke GR, Schleck CD, Zinsmeister AR, Szarka LA, *i*The incidence, prevalence, and outcomes of patients with gastroparesis in Olmsted County, Minnesota, from 1996 to 2006. *Gastroenterology*. 2009 Apr; 136(4): 1225–33.
4. Rey E, Choung RS, Schleck CD, Zinsmeister AR, Talley NJ, Locke GR. Prevalence of Hidden Gastroparesis in the Community: The Gastroparesis “Iceberg.” *J Neurogastroenterol Motil*. 2012 Jan; 18(1): 34–42.
5. Ye Y, Jiang B, Manne S, Moses PL, Almansa C, Bennett D, *et al.* Epidemiology and outcomes of gastroparesis, as documented in general practice records, in the United Kingdom. *Gut*. 2021 Apr; 70(4): 644–53.
6. Hyett B, Martinez FJ, Gill BM, Mehra S, Lembo A, Kelly CP, *et al.* Delayed radionuclide gastric emptying studies predict morbidity in diabetics with symptoms of gastroparesis. *Gastroenterology*. 2009 Aug; 137(2): 445–52.
7. Wang YR, Fisher RS, Parkman HP. Gastroparesis-related hospitalizations in the United States: trends, characteristics, and outcomes, 1995-2004. *Am J Gastroenterol*. 2008 Feb; 103(2): 313–22.
8. Camilleri M, Parkman HP, Shafi MA, Abell TL, Gerson L. Clinical Guideline: Management of Gastroparesis. *Am J Gastroenterol*. 2013 Jan; 108(1): 18–38.
9. Cherian D, Sachdeva P, Fisher RS, Parkman HP. Abdominal pain is a frequent symptom of gastroparesis. *Clin Gastroenterol Hepatol*. 2010 Aug; 8(8): 676–81.
10. Parkman HP, Camilleri M, Farrugia G, McCallum RW, Bharucha AE, Mayer EA, *et al.* Gastroparesis and functional dyspepsia: excerpts from the AGA/ANMS meeting. *Neurogastroenterol Motil*. 2010 Feb; 22(2): 113–33.

11. Parkman HP, Yates K, Hasler WL, Nguyen L, Pasricha PJ, Snape WJ, *et al.* Clinical features of idiopathic gastroparesis vary with sex, body mass, symptom onset, delay in gastric emptying, and gastroparesis severity. *Gastroenterology*. 2011 Jan; 140(1): 101–15.
12. Revicki DA, Rentz AM, Dubois D, Kahrilas P, Stanghellini V, Talley NJ, *et al.* Gastroparesis Cardinal Symptom Index (GCSI): development and validation of a patient reported assessment of severity of gastroparesis symptoms. *Qual Life Res*. 2004 May; 13(4): 833–44.
13. Pasricha PJ, Camilleri M, Hasler WL, Parkman HP. White Paper AGA: Gastroparesis: Clinical and Regulatory Insights for Clinical Trials. *Clinical Gastroenterology and Hepatology*. 2017 Aug; 15(8): 1184–90.
14. Soykan I, Sivri B, Sarosiek I, Kiernan B, McCallum RW. Demography, clinical characteristics, psychological and abuse profiles, treatment, and long-term follow-up of patients with gastroparesis. *Dig Dis Sci*. 1998 Nov; 43(11): 2398–404.
15. Choung RS, Locke GR, Schleck CD, Zinsmeister AR, Melton LJ, Talley NJ. Risk of Gastroparesis in Subjects with Type 1 and 2 Diabetes in the General Population. *Am J Gastroenterol*. 2012 Jan; 107(1): 82–8.
16. Bharucha AE, Batey-Schaefer B, Cleary PA, Murray JA, Cowie C, Lorenzi G, *et al.* Delayed Gastric Emptying Is Associated With Early and Long-term Hyperglycemia in Type 1 Diabetes Mellitus. *Gastroenterology*. 2015 Aug; 149(2): 330–9.
17. Shaikh DH, Jyala A, Mehershahi S, Sinha C, Chilimuri S. Acute Gastric Dilatation: A Cause for Concern. *Case Rep Gastroenterol*. 2021 Feb 12; 15(1): 171–7.
18. Cowley DJ, Vernon P, Jones T, Glass HI, Cox AG. Gastric emptying of solid meals after truncal vagotomy and pyloroplasty in human subjects. *Gut*. 1972 Mar; 13(3): 176–81.
19. Hamrick MC, Davis SS, Chiruvella A, Coefield RL, Waring JP, Sweeney JF, *et al.* Incidence of delayed gastric emptying associated with revisional

- laparoscopic paraesophageal hernia repair. *J Gastrointest Surg.* 2013 Feb; 17(2): 213–7.
20. Mirrielees JA, Weber SM, Abbott DE, Greenberg CC, Minter RM, Scarborough JE. Pancreatic Fistula and Delayed Gastric Emptying Are the Highest-Impact Complications After Whipple. *J Surg Res.* 2020 Jun; 250: 80–7.
21. Naftali T, Yishai R, Zangen T, Levine A. Post-infectious gastroparesis: clinical and electrogastrographic aspects. *J Gastroenterol Hepatol.* 2007 Sep; 22(9): 1423–8.
22. Abell TL, Camilleri M, Donohoe K, Hasler WL, Lin HC, Maurer AH, *et al.* Consensus recommendations for gastric emptying scintigraphy: a joint report of the American Neurogastroenterology and Motility Society and the Society of Nuclear Medicine. *J Nucl Med Technol.* 2008 Mar; 36(1): 44–54.
23. Tougas G, Eaker EY, Abell TL, Abrahamsson H, Boivin M, Chen J, *et al.* Assessment of gastric emptying using a low fat meal: establishment of international control values. *Am J Gastroenterol.* 2000 Jun; 95(6): 1456–62.
24. Lacy BE, Parkman HP, Camilleri M. Chronic nausea and vomiting: evaluation and treatment. *Am J Gastroenterol.* 2018 May; 113(5): 647–59.
25. Ghos YF, Maes BD, Geypens BJ, Mys G, Hiele MI, Rutgeerts PJ, *et al.* Measurement of gastric emptying rate of solids by means of a carbon-labeled octanoic acid breath test. *Gastroenterology.* 1993 Jun; 104(6): 1640–7.
26. Bromer MQ, Kantor SB, Wagner DA, Knight LC, Maurer AH, Parkman HP. Simultaneous measurement of gastric emptying with a simple muffin meal using [¹³C]octanoate breath test and scintigraphy in normal subjects and patients with dyspeptic symptoms. *Dig Dis Sci.* 2002 Jul; 47(7): 1657–63.
27. Keller J, Bassotti G, Clarke J, Dinning P, Fox M, Grover M, *et al.* Expert consensus document: Advances in the diagnosis and classification of gastric and intestinal motility disorders. *Nat Rev Gastroenterol Hepatol.* 2018 May; 15(5): 291–308.
28. Pasricha PJ, Grover M, Yates KP, Abell TL, Bernard CE, Koch KL, *et al.* Functional dyspepsia and gastroparesis in tertiary care are interchangeable syndromes with common clinical and pathological features. *Gastroenterology*

[Internet]. 2021 Feb 3 [cited 2021 Feb 19]; 0(0). Available from:

[https://www.gastrojournal.org/article/S0016-5085\(21\)00337-1/abstract](https://www.gastrojournal.org/article/S0016-5085(21)00337-1/abstract)

29. Bharucha AE, Kudva YC, Prichard DO. Diabetic Gastroparesis. *Endocrine Reviews*. 2019 Oct 1; 40(5): 1318–52.

30. Olausson EA, Störsrud S, Grundin H, Isaksson M, Attvall S, Simrén M. A small particle size diet reduces upper gastrointestinal symptoms in patients with diabetic gastroparesis: a randomized controlled trial. *Am J Gastroenterol*. 2014 Mar; 109(3): 375–85.

31. Fontana RJ, Barnett JL. Jejunostomy tube placement in refractory diabetic gastroparesis: a retrospective review. *Am J Gastroenterol*. 1996 Oct; 91(10): 2174–8.

32. Toussaint E, Van Gossum A, Ballarin A, Le Moine O, Estenne M, Knoop C, *et al*. Percutaneous endoscopic jejunostomy in patients with gastroparesis following lung transplantation: feasibility and clinical outcome. *Endoscopy*. 2012 Aug;44(8): 772–5.

33. Sarosiek I, Davis B, Eichler E, McCallum RW. Surgical approaches to treatment of gastroparesis: gastric electrical stimulation, pyloroplasty, total gastrectomy and enteral feeding tubes. *Gastroenterol Clin North Am*. 2015 Mar; 44(1): 151–67.

34. Fonseca Mora MC, Milla Matute CA, Alemán R, Castillo M, Giambartolomei G, Schneider A, *et al*. Medical and surgical management of gastroparesis: a systematic review. *Surgery for Obesity and Related Diseases*. 2021 Apr 1; 17(4): 799–814.

35. Sj G, Mb O. Tube jejunostomy as an adjunct to esophagectomy. *Surgery*. 1994 Feb 1; 115(2): 164–9.

36. Calles-Escandón J, Koch KL, Hasler WL, Van Natta ML, Pasricha PJ, Tonascia J, *et al*. Glucose sensor-augmented continuous subcutaneous insulin infusion in patients with diabetic gastroparesis: An open-label pilot prospective study. *PLoS One*. 2018; 13(4): e0194759.

37. Vijayvargiya P, Camilleri M, Chedid V, Mandawat A, Erwin PJ, Murad MH. Effects of Proton Pump Inhibitors on Gastric Emptying and Symptoms: A Systematic Review and Meta-analysis. *Gastroenterology*. 2019 May; 156(6): 1650–60.
38. Rao AS, Camilleri M. Review article: metoclopramide and tardive dyskinesia. *Aliment Pharmacol Ther*. 2010 Jan; 31(1): 11–9.
39. Thielemans L, Depoortere I, Perret J, Robberecht P, Liu Y, Thijs T, *et al*. Desensitization of the human motilin receptor by motilides. *J Pharmacol Exp Ther*. 2005 Jun; 313(3): 1397–405.
40. Camilleri M, McCallum RW, Tack J, Spence SC, Gottesdiener K, Fiedorek FT. Efficacy and Safety of Relamorelin in Diabetics With Symptoms of Gastroparesis: A Randomized, Placebo-Controlled Study. *Gastroenterology*. 2017 Nov; 153(5): 1240-1250.e2.
41. Carbone F, Van den Houte K, Clevers E, Andrews CN, Papathanasopoulos A, Holvoet L, *et al*. Prucalopride in Gastroparesis: A Randomized Placebo-Controlled Crossover Study. *Am J Gastroenterol*. 2019 Aug; 114(8): 1265–74.
42. Talley NJ, Locke GR, Saito YA, Almazar AE, Bouras EP, Howden CW, *et al*. Effect of Amitriptyline and Escitalopram on Functional Dyspepsia: A Multicenter, Randomized Controlled Study. *Gastroenterology*. 2015 Aug; 149(2): 340-349.e2.
43. Hasler WL, Wilson LA, Nguyen LA, Snape WJ, Abell TL, Koch KL, *et al*. Opioid Use and Potency Are Associated With Clinical Features, Quality of Life, and Use of Resources in Patients With Gastroparesis. *Clinical Gastroenterology and Hepatology*. 2019 Jun 1; 17(7): 1285-1294.e1.
44. Mearin F, Camilleri M, Malagelada JR. Pyloric dysfunction in diabetics with recurrent nausea and vomiting. *Gastroenterology*. 1986 Jun; 90(6): 1919–25.
45. Gourcerol G, Tissier F, Melchior C, Touchais JY, Huet E, Prevost G, *et al*. Impaired fasting pyloric compliance in gastroparesis and the therapeutic response to pyloric dilatation. *Aliment Pharmacol Ther*. 2015 Feb; 41(4): 360–7.

46. Coleski R, Anderson MA, Hasler WL. Factors associated with symptom response to pyloric injection of botulinum toxin in a large series of gastroparesis patients. *Dig Dis Sci.* 2009 Dec; 54(12): 2634–42.
47. FriedenberG FK, Palit A, Parkman HP, Hanlon A, Nelson DB. Botulinum toxin A for the treatment of delayed gastric emptying. *Am J Gastroenterol.* 2008 Feb; 103(2): 416–23.
48. Arts J, Holvoet L, Caenepeel P, Bisschops R, Sifrim D, Verbeke K, *et al.* Clinical trial: a randomized-controlled crossover study of intrapyloric injection of botulinum toxin in gastroparesis. *Aliment Pharmacol Ther.* 2007 Nov 1; 26(9): 1251–8.
49. Weusten BLAM, Barret M, Bredenoord AJ, Familiari P, Gonzalez J-M, van Hooft JE, *et al.* Endoscopic management of gastrointestinal motility disorders - part 1: European Society of Gastrointestinal Endoscopy (ESGE) Guideline. *Endoscopy.* 2020 Jun; 52(6): 498–515.
50. Bae JS, Kim SH, Shin C-I, Joo I, Yoon JH, Lee H-J, *et al.* Efficacy of Gastric Balloon Dilatation and/or Retrievable Stent Insertion for Pyloric Spasms after Pylorus-Preserving Gastrectomy: Retrospective Analysis. *PLoS One.* 2015; 10(12): e0144470.
51. Maus MKH, Leers J, Herbold T, Bludau M, Chon S-H, Kleinert R, *et al.* Gastric Outlet Obstruction After Esophagectomy: Retrospective Analysis of the Effectiveness and Safety of Postoperative Endoscopic Pyloric Dilatation. *World J Surg.* 2016 Oct; 40(10): 2405–11.
52. Murray FR, Schindler V, Hente JM, Fischbach LM, Schnurre L, Deibel A, *et al.* Pyloric dilation with the eosophageal functional lumen imaging probe in gastroparesis improves gastric emptying, pyloric distensibility, and symptoms. *Gastrointestinal Endoscopy.* 2021 Mar; S0016510721002613.
53. Khashab MA, Besharati S, Ngamruengphong S, Kumbhari V, El Zein M, Stein EM, *et al.* Refractory gastroparesis can be successfully managed with endoscopic transpyloric stent placement and fixation (with video). *Gastrointest Endosc.* 2015 Dec; 82(6): 1106–9.

54. Khashab MA, Ngamruengphong S, Carr-Locke D, Bapaye A, Benias PC, Serouya S, *et al.* Gastric per-oral endoscopic myotomy for refractory gastroparesis: results from the first multicenter study on endoscopic pyloromyotomy (with video). *Gastrointest Endosc.* 2017 Jan; 85(1): 123–8.
55. Gonzalez JM, Benezech A, Vitton V, Barthet M. G-POEM with antro-pyloromyotomy for the treatment of refractory gastroparesis: mid-term follow-up and factors predicting outcome. *Aliment Pharmacol Ther.* 2017 Aug; 46(3): 364–70.
56. Rodriguez JH, Haskins IN, Strong AT, Plescia RL, Allemang MT, Butler RS, *et al.* Per oral endoscopic pyloromyotomy for refractory gastroparesis: initial results from a single institution. *Surg Endosc.* 2017 Dec; 31(12): 5381–8.
57. Vosoughi K, Ichkhanian Y, Benias P, Miller L, Aadam AA, Triggs JR, *et al.* Gastric per-oral endoscopic myotomy (G-POEM) for refractory gastroparesis: results from an international prospective trial. *Gut* [Internet]. 2021 Mar 19 [cited 2021 May 8]; Available from: <https://gut.bmj.com/content/early/2021/03/18/gutjnl-2020-322756>
58. Toro JP, Lytle NW, Patel AD, Davis SS, Christie JA, Waring JP, *et al.* Efficacy of laparoscopic pyloroplasty for the treatment of gastroparesis. *J Am Coll Surg.* 2014 Apr; 218(4): 652–60.
59. Landreneau JP, Strong AT, El-Hayek K, Tu C, Villamere J, Ponsky JL, *et al.* Laparoscopic pyloroplasty versus endoscopic per-oral pyloromyotomy for the treatment of gastroparesis. *Surg Endosc.* 2019 Mar; 33(3): 773–81.
60. Sarosiek I, Forster J, Lin Z, Cherry S, Sarosiek J, McCallum R. The addition of pyloroplasty as a new surgical approach to enhance effectiveness of gastric electrical stimulation therapy in patients with gastroparesis. *Neurogastroenterol Motil.* 2013 Feb; 25(2): 134-e80.
61. Abell T, McCallum R, Hocking M, Koch K, Abrahamsson H, Leblanc I, *et al.* Gastric electrical stimulation for medically refractory gastroparesis. *Gastroenterology.* 2003 Aug; 125(2): 421–8.
62. McCallum RW, Snape W, Brody F, Wo J, Parkman HP, Nowak T. Gastric electrical stimulation with Enterra therapy improves symptoms from diabetic

gastroparesis in a prospective study. *Clin Gastroenterol Hepatol*. 2010 Nov; 8(11):947–54; quiz e116.

63. McCallum RW, Sarosiek I, Parkman HP, Snape W, Brody F, Wo J, *et al*. Gastric electrical stimulation with Enterra therapy improves symptoms of idiopathic gastroparesis. *Neurogastroenterol Motil*. 2013 Oct; 25(10): 815-e636.

64. Ducrotte P, Coffin B, Bonaz B, Fontaine S, Bruley Des Varannes S, Zerbib F, *et al*. Gastric Electrical Stimulation Reduces Refractory Vomiting in a Randomized Crossover Trial. *Gastroenterology*. 2020 Feb; 158(3): 506-514.e2.

65. Gourcerol G, Coffin B, Bonaz B, Hanaire H, Varannes SBD, Zerbib F, *et al*. Impact of Gastric Electrical Stimulation on Economic Burden of Refractory Vomiting: A French Nationwide Multicentre Study. *Clinical Gastroenterology and Hepatology [Internet]*. 2020 Nov 12 [cited 2021 Mar 20]; 0(0). Available from: [https://www.cghjournal.org/article/S1542-3565\(20\)31544-5/abstract](https://www.cghjournal.org/article/S1542-3565(20)31544-5/abstract)

66. Hedjoudje A, Huet E, Leroi A, Desprez C, Melchior C, Gourcerol G. Efficacy of gastric electrical stimulation in intractable nausea and vomiting at 10 years: A retrospective analysis of prospectively collected data. *Neurogastroenterology & Motility*. 2020; 32(11): e13949.

67. Zoll B, Zhao H, Edwards MA, Petrov R, Schey R, Parkman HP. Outcomes of surgical intervention for refractory gastroparesis: a systematic review. *J Surg Res*. 2018 Nov; 231: 263–9.

Figure 1: Algorithm for management of gastroparesis by a strategy of therapeutic escalation

BTA: Botulinum Toxin A; G-POEM: Gastric-PerOral Endoscopic Myotomy

Appendix 1

Gastroparesis Cardinal Symptom Index (GCSI):

Symptom*	None	Very Mild	Mild	Moderate	Severe	Very Severe
1. Nausea (feeling sick to your stomach as if you were going to vomit or throw up)	0	1	2	3	4	5
2. Retching (heaving as if to vomit, but nothing comes up)	0	1	2	3	4	5
3. Vomiting	0	1	2	3	4	5
4. Stomach fullness	0	1	2	3	4	5
5. Not able to finish a normal-sized meal	0	1	2	3	4	5
6. Feeling excessively full after meals	0	1	2	3	4	5
7. Loss of appetite	0	1	2	3	4	5
8. Bloating (feeling like you need to loosen your clothes)	0	1	2	3	4	5
9. Stomach or belly visibly larger	0	1	2	3	4	5

GASTROPARESIS management

Etiological treatment

Symptomatic treatment

Dietary and pharmacological treatments

- Prokinetics (erythromycin, domperidone, metoclopramide)
- Antiemetics and painkillers

failure

Invasive treatments

Pylorus endoscopic dilatation

Pylorus BTA injection

Gastric pacemaker

failure

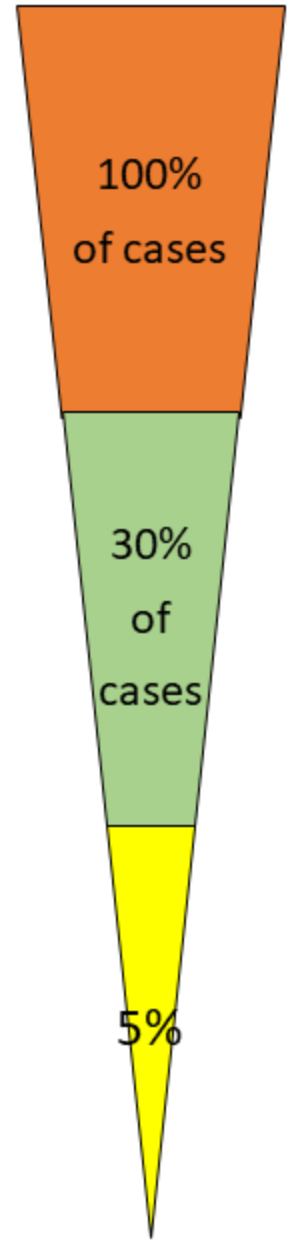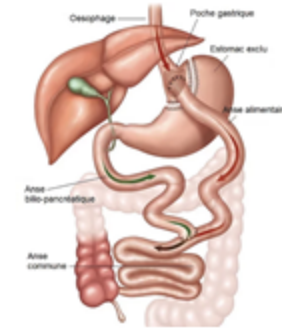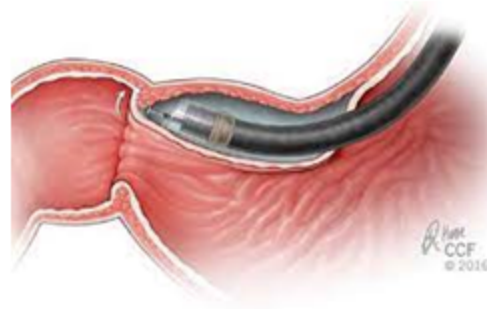
G-POEM

failure

Gastric bypass > Gastrectomy

With sero-muscular gastric biopsy samples

Pyloroplasty



S
T
E
P
-
U
P

S
T
R
A
T
E
G
Y