



HAL
open science

Early symptomatic neurosyphilis and ocular syphilis: A comparative study between HIV-positive and HIV-negative patients

Vero Rasoldier, J. Gueudry, C. Chapuzet, B. Bodaghi, M. Muraine, R. Tubiana, L. Paris, M. Pestel-Caron, F. Caron, E. Caumes

► To cite this version:

Vero Rasoldier, J. Gueudry, C. Chapuzet, B. Bodaghi, M. Muraine, et al.. Early symptomatic neurosyphilis and ocular syphilis: A comparative study between HIV-positive and HIV-negative patients. *Infectious Diseases Now*, 2021, 51 (4), pp.351-356. 10.1016/j.medmal.2020.10.016 . hal-03238856

HAL Id: hal-03238856

<https://normandie-univ.hal.science/hal-03238856v1>

Submitted on 2 Jun 2021

HAL is a multi-disciplinary open access archive for the deposit and dissemination of scientific research documents, whether they are published or not. The documents may come from teaching and research institutions in France or abroad, or from public or private research centers.

L'archive ouverte pluridisciplinaire **HAL**, est destinée au dépôt et à la diffusion de documents scientifiques de niveau recherche, publiés ou non, émanant des établissements d'enseignement et de recherche français ou étrangers, des laboratoires publics ou privés.

Early symptomatic neurosyphilis and ocular syphilis: A comparative study between HIV-positive and HIV-negative patients[☆]

V. Rasoldier^{a,*}, J. Gueudry^b, C. Chapuzet^a, B. Bodaghi^c, M. Muraine^b, R. Tubiana^{d,e}, L. Paris^f, M. Pestel-Caron^g, F. Caron^a, E. Caumes^{e,d,h}

^a CHU Charles Nicolle, Service des Maladies infectieuses et Tropicales, 1, rue de Germont, 76000 Rouen, France

^b CHU Charles Nicolle, Service d'ophtalmologie, 1, rue de Germont, 76000 Rouen, France

^c AP-HP, Hôpital la Pitié Salpêtrière, Service ophtalmologie, 47-83, boulevard de l'Hôpital, 75013 Paris, France

^d Sorbonne Université, AP-HP, Hôpitaux Universitaires Pitié-Salpêtrière Charles Foix, Service de Maladies infectieuses et Tropicales, 75013 Paris, France

^e AP-HP, Hôpital la Pitié Salpêtrière, Service des Maladies Infectieuses et Tropicales, 47-83, boulevard de l'Hôpital, 75013 Paris, France

^f AP-HP, Hôpitaux universitaires la Pitié Salpêtrière/Charles Foix, Pôle biologie et pathologie, Service de parasitologie, 47-83, boulevard de l'Hôpital, 75013 Paris, France

^g CHU Charles Nicolle, Institut de Biologie Clinique, Service de Bactériologie, 1, rue de Germont, 76000 Rouen, France

^h Sorbonne Université, INSERM, Institut Pierre Louis d'Épidémiologie et de Santé Publique (IPLESP), Paris, France

ARTICLE INFO

Article history:

Received 2 January 2020

Received in revised form 3 May 2020

Accepted 14 October 2020

Available online 22 October 2020

Keywords:

HIV

Syphilis

Neurosyphilis

Ocular syphilis

ABSTRACT

Objectives: Since the 2000s, there has been an increase in prevalence of neurosyphilis (NS) and ocular syphilis (OS). As data about symptomatic NS/OS is limited, this study aims to assess the characteristics of symptomatic NS/OS, according to HIV status.

Methods: We compared the clinical and biological presentation of early symptomatic NS/OS and its outcome in HIV-positive and HIV-negative patients.

Results: Ninety-six patients (93% men, 49% HIV-positive) were included from 2000 to 2016 in two centers, with 67 (69%) having OS, 15 (16%) NS, and 14 (14%) both. HIV-positive patients were younger ($P=0.006$) and more likely to be males having sex with males ($P=0.00048$) or to have a history of syphilis ($P=0.01$). Among 81 OS, there were 43 posterior uveitis (57%), and bilateral involvement was more common in HIV-positive patients (62% versus 38%, $P=0.045$). Among 29 NS there were 21 cases of cranial nerve involvement (72%), seven meningitis (24%) and 11 paresthesia (38%). Involvement of the VIIIth cranial nerve was the most common (16 cases). Treponemal tests were more commonly found positive in cerebrospinal fluid in HIV-positive patients (88% versus 76%, $P=0.04$). Visual acuity (VA) always improved after treatment (initial VA logMAR 0.8 ± 0.8 versus 0.1 ± 0.1 at 3 months), but 32% and 18% of the patients still had neurological or ocular impairment respectively six and 12 months after treatment. Non-treponemal serological reversion was observed in 43/50 patients (88%) at six months.

Conclusion: HIV infection has no consequence on the outcome of NS and OS. Sequelae are common, emphasizing the importance of prevention, and screening, and questioning enhanced treatment.

1. Introduction

Since the 2000s, there has been an increase in the prevalence of syphilis worldwide [1]. Such an increase parallels the improvement of HIV infection prognosis and management [2]. Several questions have been raised about the relationship between HIV infection and syphilis [3,4]. While case reports have made it possible to

hypothesize several differences between HIV-positive patients, and HIV-negative patients, large comparative studies have found no significant differences between them despite some exceptions [5].

It is noteworthy that during a case of syphilis the central nervous system (CNS) is invaded early by *Treponema pallidum* [6]. However there is no formal system for reporting ocular syphilis (OS) or neurosyphilis (NS). Historically in the Oslo study, of 1404 Scandinavian patients with early syphilis, 1.6% (23 patients) developed symptomatic early NS (with no data about OS) [7]. More recently from 2009 to 2015 in the USA, of 48,045 of the syphilis cases notified to CDC, 403 (0.8%) were NS [8]. In another US study, the prevalence of symptomatic NS was estimated at 1.8% amongst overall early

[☆] Presented orally at the JNI (Journées nationales de l'infectiologie 2019).

* Corresponding author at: CHU Charles Nicolle, Service des Maladies infectieuses et Tropicales, 1, rue de Germont, 76000 Rouen, France.

E-mail address: vero.rasoldier@chu-rouen.fr (V. Rasoldier).

syphilis cases reported to CDC over ten US states [9] while the estimated prevalence of OS was 0.65% amongst 35,547 syphilis cases in 2015 [9]. Overall the incidence and prevalence of NS/OS seems to average 1% in patients with early syphilis.

To date most studies of NS/OS, whether or not patients were infected with HIV, included a varying percentage of asymptomatic patients with biological definition of NS. Definition of NS varies according to the studies, and such studies include 13% to 62% asymptomatic forms for which the diagnosis of NS relied only on the results of cerebrospinal fluid (CSF) [4,10–13]. However, the positivity of the non-treponemal tests in the cerebrospinal fluid (CSF-VDRL), which is the gold standard for diagnosis of NS, may have a low sensitivity even in symptomatic patients [14,15]. On the other hand, patients with syphilis having neurological or ocular signs have to be treated as NS whatever the results of CSF testing [16–18]. Finally, there is no evidence to support variation from the European recommendations or CDC guidelines regarding the treatment of syphilis in patients without clinical neurological findings in whom it is not recommended to perform CSF analysis [16,17]. Overall studies focusing on only symptomatic patients with NS or OS are lacking.

We assessed the characteristics of early symptomatic NS and OS. We also evaluated whether HIV infection influenced the clinical, and biological characteristics of NS/OS as well as outcome in these patients.

2. Material and Methods

We included all consecutive cases of early symptomatic NS and OS diagnosed between 1st of January, 2000, and December 31st, 2016, in two Infectious Diseases departments of two French University hospitals (Charles Nicolle Hospital, Rouen, and La Pitié Salpêtrière, Paris).

NS was defined by the presence of neurological signs with a positive serology for syphilis (TPHA or EIA and VDRL), CSF inflammation AND a treponemal-test (T-test; i.e. TPHA or treponemal enzyme immunoassay) positive in CSF. OS was defined by ocular signs with positive serology for syphilis and no other cause for ocular involvement. A positive serology for syphilis was defined as positive treponemal and non-treponemal (NT-test, i.e. VDRL) blood tests. The diagnosis of early NS/OS relied on compatible neurological or ocular signs, with or without extra-neurological signs, but with evidence of seroconversion within the past year in the subgroup of patients followed up regularly, and no history of syphilis in the remaining patients, and lack of other cause for the neurological or ocular involvement.

Lumbar punctures were performed systematically in patients with neurological signs, and eventually in those with ocular signs. We assessed signs of CSF inflammation (i.e., having pleiocytosis > 5 cells/mm³ and/or elevated CSF-protein > 0,45 g/l), reactive T-test and/or reactive CSF-VDRL. A negative VDRL-CSF did not rule out the diagnosis of NS according to the most recent guidelines [16–18]. Latent and late NS/OS cases were not included.

HIV infection was always confirmed by a positive serum HIV enzyme linked immunosorbent assay (ELISA) and confirmed with a western blot.

Treatment success was defined by the improvement or complete remission of clinical signs or symptoms and a significant decrease (at least 4-fold) of the VDRL at one year.

Treatment failure was defined clinically as the persistence of NS/OS signs or symptoms. A non-significant decrease of the VDRL titer (i.e. less than 4-fold) in blood within 6 months of treatment was interpreted as failure of treatment only if the clinical signs persisted. Short-term outcome was evaluated at the end of the first month after treatment ended. Then patients were followed up to

one year after treatment. Sequelae were defined by the persistence of ophthalmological or neurological signs at one year.

Charts from patients were reviewed for the following data: age, gender, sexual orientation (distinguishing MSM from the others), history of syphilis, duration of symptoms, neurological signs, ophthalmological signs, and general findings, as well as CD4 cell count and HIV viral load in HIV infected patients, and results of blood and cerebrospinal fluid analysis, T-test and VDRL in blood and CSF, failure, recurrence and duration of follow up. Visual acuity (VA) at first examination and during follow up was collected in the ophthalmological department of Rouen's hospital.

We compared data between HIV-infected patients and others. Results are given in means with standard deviation (SD) or in median with first and third interquartile range (IQ1-3), and minimal-maximal (min-max). Categorical data was compared in univariate analysis using Fisher's exact test or Chi-2 test according to size population. Association between continuous variables was assessed by Student test. Ordinal variables were analyzed with the Wilcoxon test. Two-tailed *P*-values < 0.05 were considered to be significant. Online software for statistics was used [19].

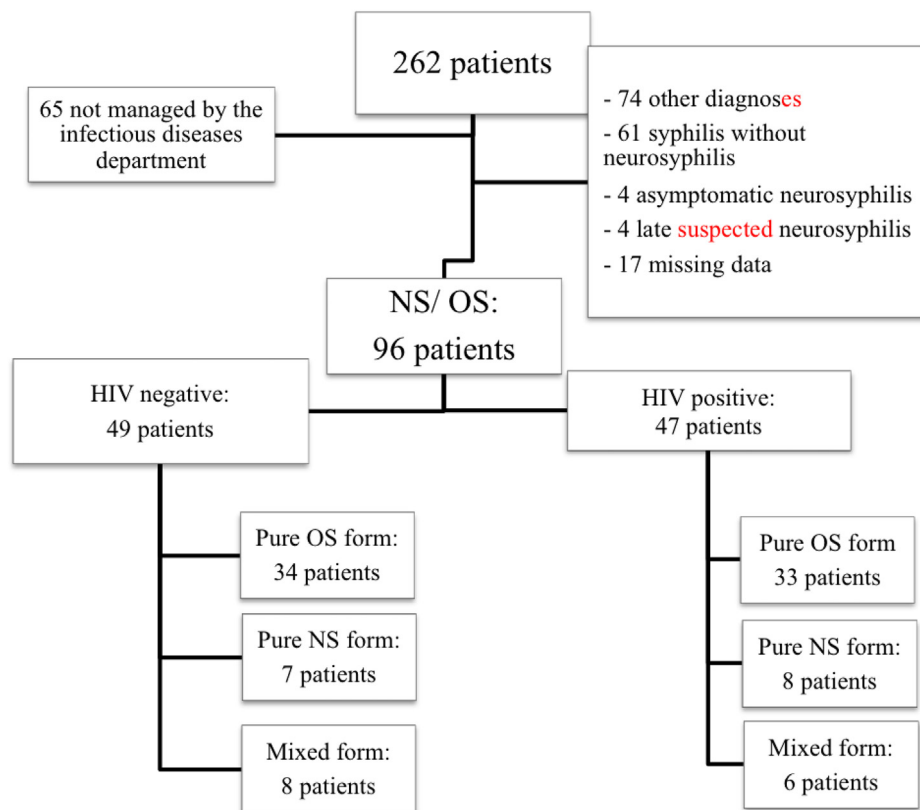
3. Results

From 2000 to 2016, early symptomatic NS/OS was diagnosed in 96 patients, 67 (69%) having OS, 15 (16%) having NS, and 14 (15%) having both (Fig. 1).

Their demographic characteristics according to HIV-status are described in Table 1. Mean time HIV diagnosis was 6.6 ± 7.2 years. Among 47 HIV patients, 24 (51%) had a CD4 rate < 350/mm³, 16 (34%) were under antiretroviral therapy and 18 (38.3%) had an undetectable viral load (definition depending on years between 20 and 200cp/ml) at initial diagnosis. A history of syphilis was more common in HIV-positive patients than in HIV-negative patients (17% versus 2%, *P*=0.01). The T-test in the CSF was significantly more often positive in HIV-positive patients (88% versus 76%, *P*=0.04), but there was no other CSF difference between the two groups. There was no difference in the antibiotic management and outcome up to one-year of follow-up between HIV-positive and negative patients.

4. Early symptomatic neurosyphilis and ocular syphilis characteristics

Neurological symptoms were found in 29 patients (30%) (Table 2). The main cranial nerves involved were the VIIIth (76%), Vth (19%), VIIth (10%), IIIrd and XIIth (5% each). Involvement was unilateral in 50% (data available for 18 of 21 patients). Eleven patients (38%) had paresthesia, unrelated to a sensitive cranial nerve involvement nor an identified CNS or medullar lesion. Location of the paresthesia was peripheral, located on chest belt for 2 patients, in the median nerve territory (3 first fingers of one hand) for one patient, bilateral lower limbs for 2, unilateral lower limb for 2 with radicular L5 pain for one. This latter patient also had paresthesia of the extremities and the scalp. One patient had widespread paresthesia. Among these 11 patients, two had signs of secondary syphilis plus VIIIth cranial nerve involvement, three had only signs of secondary syphilis, and four had only neurological signs (VIIIth involvement in 2 patients, VIIth in one patient and association of IIIrd, Vth and XIIth in one patient). One other HIV-positive patient had meningitis (10 cells, CSF-protein 0.49 g/l) with paresthesia of the lower limbs that disappeared with penicillin G. The last HIV-negative patient had only feet dysesthesia with a positive T-test in blood and CSF, and positive VDRL in blood. Symptoms quickly disappeared with penicillin G.



OS = ocular syphilis; NS = neurosyphilis

Fig. 1. Flow chart.

Table 1

Demographic characteristics according to HIV status in 96 patients with early neurosyphilis or ocular syphilis.

	Total (n = 96) n (%)	HIV+ (n = 47) n (%)	HIV- (n = 49) n (%)	P-value
Men	89 (93)	49 (98)	43 (88)	0.11
Age (mean ± SD)	45.3 ± 11.4	41.8 ± 8.8	48 ± 12	0.006
Caucasian	74 (77.1)	31 (66)	43 (88)	0.008
Sexual practices				
MSM	56 (58.3)	36 (76.6)	20 (41)	0.0005
Heterosexuality	30 (31.3)	8 (17)	22 (45)	0.0004
Unknown	10 (10.4)	3 (6.4)	7 (14)	0.3

N: number of cases; SD: standard deviation; MSM: men who have sex with men.

Table 2

Comparison of symptoms according to HIV status in 96 patients with early neurosyphilis or ocular syphilis.

	Total n(%)	HIV+ n(%)	HIV- n(%)	P-value
Neurological symptoms	29	33	34	0.4
Meningitis	7 (24)	4 (29)	3 (20)	
Cranial nerve affection	21 (72)	10 (71)	11 (73)	
Vasculitis	1 (3)	0	1 (7)	
Isolated paresthesias	11 (38)	5 (36)	6 (40)	
Ocular symptoms	81	39	42	1
Anterior uveitis	10 (13)	5 (14)	5 (13)	1
Intermediar uveitis	0	0	0	
Posterior uveitis	43 (57)	19 (53)	24 (62)	0,5
Panuveitis	18 (22)	10 (26)	8 (19)	0,6
Keratitis	0	0	0	
Optic neuritis	3 (4)	1 (3)	2 (5)	1
Bilateral involvement	39 (49%)	24 (62)	15 (38)	0,045
Visual impairment	76 (94)	35 (88)	41 (98)	0,1

Table 3

Cerebrospinal fluid characteristics according to HIV-status and clinical forms in 96 patients with early neurosyphilis (NS) or ocular syphilis (OS).

	All forms			Pure NS form			Pure OS form		
	All patients n = 96	HIV+ n = 47	HIV- n = 49	All patients n = 15	HIV+ n = 8	HIV- n = 7	All patients n = 67	HIV + n = 33	HIV- n = 34
Lumbar puncture performed, n	77	41	36	14	8	6	50	28	22
Pleiocytosis (/mm ³ ± SD)	42 ± 70	45 ± 70	37 ± 71	81 ± 121	75 ± 108	88 ± 147	29 ± 51	36 ± 60	21 ± 38
CSF-protein (g/l ± SD)	0.66 ± 0.45	0.70 ± 0.54	0.62 ± 0.32	0.92 ± 0.8	0.94 ± 0.97	0.9 ± 0.55	0.57 ± 0.29	0.62 ± 0.35	0.53 ± 0.23
Positive T-Test, n(%)	63 (83%)	37 (88%)*	25 (76%)*	14 (100%)	8 (100%)	6 (100%)	39 (78%)	24 (86%)**	15 (68%)**
Positive VDRL, n(%)	17 (22%)	10 (24%)	7 (21%)	4 (29%)	2 (25%)	2 (40%)	10 (20%)	7 (25%)	3 (14%)

n = number of cases; CSF = cerebrospinal fluid; HIV: Human Immunodeficiency Virus Status; T-Test: Treponemal test; SD: standard deviation.

* P = 0,04

** P = 0,025, significant difference between HIV-infected and HIV-uninfected group.

Table 4

Results of non-treponemal blood test (VDRL) according to HIV status on clinical form in 96 patients with early neurosyphilis (NS) or ocular syphilis (OS).

	VDRL results: median [range] (number of sampled patients)			
	All patients	HIV+	HIV-	P-value
All forms	32 [2–512] (94)	64 [4–512] (45)	32 [2–512] (47)	0.67
Pure NS forms	32 [4–256] (16)	32 [4–256] (9)	32 [4–128] (7)	0.51
Pure OS forms	32 [2–512] (65)	64 [8–512] (32)	32 [2–256] (33)	0.20
NS and OS forms	128 [16–512] (13)	87 [16–128] (6)	128 [16–512] (7)	0.21

One 37-year-old woman had stroke-like symptoms with right hemiparesis and facial paralysis, revealing multiple intracerebral lesions in imaging. Diagnosis was confirmed by a positive serology for syphilis, a positive VDRL-CSF and T-Test in CSF, and positive PCR of *Treponema pallidum* on cerebral biopsy. This was considered to be vasculitis [20].

Eighty-one patients (84%) had ophthalmological involvement. Posterior uveitis was the most common diagnosis (n = 43, 57%) before panuveitis (n = 18, 22%). Bilateral involvement was seen more often in HIV-infected patients than in those non-infected (24(62%) versus 15(38%) patients, P = 0.045).

Forty-three (44%) patients with NS/OS had no other symptoms of syphilis whereas 53 had signs of early syphilis, 49 (51%) had signs of secondary syphilis, and four had a syphilitic chancre. Among the 49 patients with signs of secondary syphilis, a cutaneous eruption was found in 46 patients (87%) and/or a mucous membrane involvement in 12 patients (22%).

5. Biological characteristics

Lumbar punctures were performed in 77 patients (Table 3). Among the 19 patients who did not have CSF analysis, 18 had OS. Pleiocytosis and CSF-protein levels were significantly higher in NS forms than in OS forms (respectively 81 ± 121 versus 29 ± 51; and 0.92 ± 0.8 versus 0.57 ± 0.29; P = 0.04 for both). VDRL in blood at initial diagnosis was not significantly different according to HIV status or NS pattern (Table 4). A positive VDRL-CSF was found in 4 of 14 patients with pure NS form (29%) when 100% of T-test in CSF was positive. For pure OS forms, the T-test in CSF was positive in 39 of 50 patients (78%) who had a lumbar punctures and the VDRL-CSF was positive for 10 (20%) of these patients.

6. Treatment and outcome

Ninety patients (95%) were treated with intra venous (IV) penicillin G (18 to 24 M UI per day), three patients with IV ceftriaxone 2 g per day, and one with oral doxycycline 200 mg per day. One patient received an intramuscular injection of benzathine benzylpenicillin

before oral doxycycline whereas another patient was not treated, and was lost to follow up.

The three patients treated with ceftriaxone had OS: one (HIV-positive) had a complete recovery at M3, one (HIV-positive) had a partial visual recovery after one year of follow-up and one (HIV-negative) had a partial visual recovery after 3 months and then was lost to follow-up. The only patient treated with doxycycline was HIV-positive, had OS and had a complete recovery after 21 days of treatment. After one month, among the 90 patients treated with IV penicillin G, 28 patients (31%) still had neurological or ocular symptoms. Among these 28 patients, penicillin was prolonged for one month in six patients, switched for ceftriaxone in one patient, and for doxycycline in two patients. Treatment duration was available in 93 patients as three were lost to follow-up. Ninety patients (97%) received at least 15 days of antibiotics. Duration of treatment was 15 days for 41 (44%) patients and 21 days for 40 (43%) patients. Nine patients still presented clinical signs of NS/OS and their treatment was extended to 28 days. The three remaining patients were treated less than 15 days because of noncompliance in two patients, and skin allergy at day 13 in one patient.

Six months after treatment, 18 (34%) of the 54 patients with follow-up still had clinical signs. After one year, 7 of the 40 evaluable patients (18%) had sequelae (Table 5).

VA evolution was analyzed in 26 patients. There was a constant improvement, at least partial, or stabilization of VA for every patient at three months follow-up (see web-only Supplementary Figure S3). After three months, no patients had a VA below 2/10 compared to 12 patients initially (40%), and 21 patients (81%) had a VA above 5/10 compared to 12 patients (40%) before treatment, but there was still five patients (19%) with an intermediary VA between 2/10 and 5/10 compared to 6 (20%) before treatment (Fig. 2).

VDRL blood tests were negative at six months in 43 of the 50 patients (86%) in whom this data was available, and in 37 of the 41 patients who could be evaluated after one year.

7. Discussion

It was found that HIV-positive patients with early symptomatic NS/OS were more likely to be younger, MSM, to have a history

Table 5

Evolution at 6 months and 12 months after treatment of non-treponema blood test (VDRL) according to HIV status and clinical evolution and initial cohort of 96 patients with early neurosyphilis or ocular syphilis.

	Negativation of VDRL at 6 months						Negativation of VDRL at 12 months					
	All patients		HIV+		HIV-		All patients		HIV+		HIV-	
	n/N	(%)	n/N	(%)	n/N	(%)	n/N	(%)	n/N	(%)	n/N	(%)
Overall evolution	34/42	(76)	17/20	(85)	18/22	(82)	32/36	(89)	16/20	(80)	16/16	(100)
Complete recovery	21/24	(88)	12/13	(86)	9/11	(82)	21/22	(95)	12/13	(92)	9/9	(100)
Any sequelae	12/15	(80)	4/5	(80)	9/10	(90)	10/12	(83)	3/5	(60)	7/7	(100)
Reinfection	0/3	(0)	0/2	(0)	0/1	(0)	0/2	(0)	0/2	(0)		

n: number of patients with negative VDRL at 6 or 12 months; N: total number of patients with clinical and biological data available at 6 or 12 months.

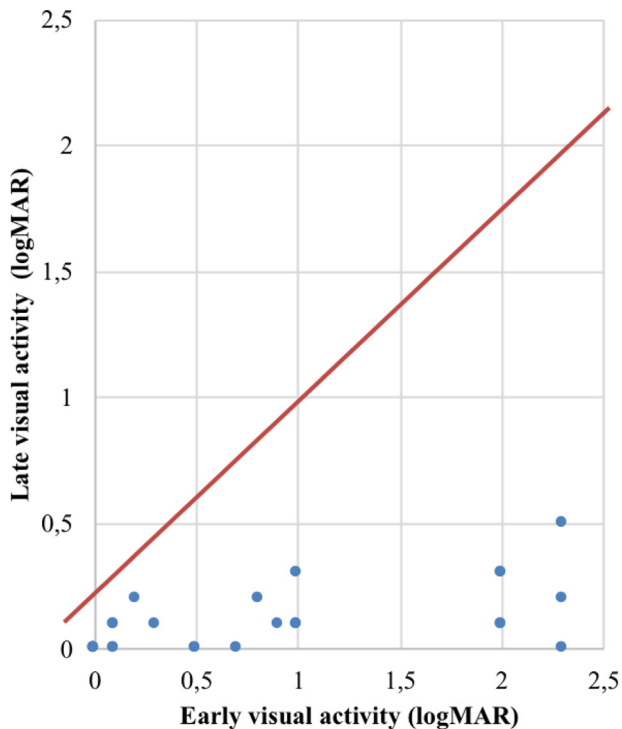


Fig. 2. Evolution of visual acuity after treatment by logMAR scale in a sub cohort of 26 patients with early ocular syphilis (the higher logMAR score, the lower the acuity).

of syphilis, bilateral ocular involvement and a positive T-test in the CSF compared to HIV-negative patients. There was no other difference between the two groups.

Similar epidemiological differences between HIV-positive and negative patients were also found in several studies. A younger age is found in three other studies: 39 versus 55 years ($P=0.001$) in 41 OS [21], 44 years versus 53 years ($P=0.002$) in 66 OS [21], and 38 years versus 49 years ($P=0.003$) in 46 NS [15]. In contrast no age difference was found in the studies focusing on all forms of syphilis [5,22]. Otherwise comparative studies usually find that HIV-positive patients were more often MSM [5,21,23] and have a history of syphilis [5,11,22].

The most recent study compared neurological and ocular signs in HIV-positive and HIV-negative patients but HIV-positive patients with no neurological symptoms but considered at risk for NS (ie. $RPR \geq 1:32$ and $CD4 \leq 350/\mu l$) were also included [24]. Unfortunately the authors did not specify how many HIV-positive asymptomatic cases with the latter criteria were included. Of 385 HIV-positive patients and 81 HIV-negative patients, HIV-negative patients had more hearing loss (30.8% versus 17.2%, $P=0.006$), sensory loss (8.8% versus 3.7%, $P=0.047$) and gait (26.3% versus 16.5%, $P=0.041$) than HIV-positive patients. However such results cannot

be compared to ours our population study only included symptomatic patients with NS in both groups.

In this post HAART area, of our 47 HIV-positive patients, 39 (83%) had eye involvement. We reported more patients with posterior uveitis (58%) than panuveitis (24%). This contrast with other studies where panuveitis was the leading form of OS, found in 41% of 41 patients and 42% of 66 patients respectively [21,23]. However, this is similar to the results of another study on 21 OS cases seen from 2012 to 2015 where posterior uveitis (69%) was more common than panuveitis (14%) [25]. We do not explain why the proportion of panuveitis was lower than in previous reports, but we hypothesize that the minimal signs associated with involvement of anterior segment could have been missed by the physicians previously.

We found a significant increase in bilateral eye involvement among HIV-positive compared to HIV-negative patients. Similarly, some studies found a higher prevalence of bilateral involvement in HIV-positive patients, ranging from 63% of 83 OS [13] to 83% of 13 uveitis [26]. In contrast in the British cohort of 41 OS such a difference was not evidenced [21].

The main manifestation of early symptomatic NS was cranial nerve involvement of the VIIIth cranial nerve (76% of the cases of NS). Very few studies detailed the proportion of each cranial nerve involvement in NS, and those that do are relatively old. The largest review of cranial nerve involvement in NS was performed in 1946, included 195 patients and found a predominance of VIIIth (23%) and VIIth (23%), followed by IInd (15%), IIIrd and VIth (12%), but other cranial nerves (Vth, IXth-Xth, IVth, XIIth, Ist, XIth) were involved [27]. Therefore the involvement of a cranial nerve, mainly the VIIth or VIIIth, in a person with at-risk sexual behavior should raise the diagnosis of NS.

We surprisingly identified 11 patients (38% of NS) who had paresthesia neither associated with a sensitive nerve defect nor a CNS focal lesion. Among these patients, two patients had only paresthesias as neurological symptoms (associated with biological meningitis) raising the question of overlapping of early and late NS patterns with early tabes. This is unlikely as our criteria for early syphilis were stringent. However such symptom would need more investigation. Meanwhile the diagnosis of syphilis should be raised in any episode of paresthesias in a patient at risk.

Only 17 patients (22%) of 96 whom had a lumbar punctures had positive VDRL-CSF. In the literature, VDRL-CSF has been described with variable sensitivities depending on studies from 10.7 to 27% [14,15,24,28]. Thus, it is admitted that CSF-VDRL alone is not enough to confirm neurosyphilis [16], and should be interpreted along with other clinical and biological parameters.

Furthermore, we chose to include positive T-test in CSF as mandatory for diagnosis of pure form NS. The latest 2014 European guidelines on syphilis management state that "a positive CSF T-test does not confirm the diagnosis of NS but a negative CSFT-test result is highly unlikely in neurosyphilis" [16]. Intra-venous penicillin G is still the first-line antibiotic for NS/OS [16-18]. Treatments other than penicillin give inconstant results and are not considered as efficient as penicillin [29,30]. We did not treat enough patients

with ceftriaxone or doxycycline to feed this debate. However it has been showed that doxycyclin could be efficient in patients with OS [30]. Of note only 19% of our 63 patients with OS who underwent lumbar punctures had biological signs of NS. Therefore oral doxycyclin could be considered in at least 80% of the patients with OS and comparative studies are needed in order to retain intravenous penicillin for the cases of NS.

We found a high rate of sequelae (18% at 12 months) in contrast to previous studies where the criteria of judgement were biological (decrease of VDRL in the blood and/or in the CSF) and not clinical. The sequelae included vertigo, visual loss, or persistent paresthesias. In contrast to usual recommendations [16–18], no CSF follow-up was done in our study for three different reasons. Some of our patients had OS with no lumbar puncture at onset. Other patients were lost to follow-up, or refused another lumbar puncture as they were cured. However clinical outcome seems more important and we showed a high rate of sequelae.

Our study has some limitations. First, 58% of our patients were lost to follow-up at one year. However this rate is similar to that found in other retrospective studies where it varies from 34% to 64% [3,5,11]. Secondly, we chose to distinguish OS and NS although treatment of OS is associated with that of NS in usual guidelines [16–18]. Our results support that NS and OS could be considered separately as 22% of our patients diagnosed with OS had a negative T-test in the CSF, and 80% had no biological signs of NS. Moreover sclera, cornea, vitreous an retinal vessels do not derive from the neuroepithelium which forms the central nervous system during the embryogenesis [31]. Lastly doxycycline could be considered in patients with OS [30]. Finally, lumbar puncture was not systematic in OS, reason why we did not have CSF data for every patient. It was considered to be an invasive procedure, which was avoidable, as the treatment of OS and NS remains the same.

In conclusion early symptomatic NS/OS is increasing, with a large majority of OS. Paresthesias and cranial nerve involvement in a patient at risk of syphilis should raise the diagnosis of NS. HIV-infection does not appear to confer any change in the outcome of NS and OS in this post-HAART era. The high rate of sequelae emphasizes the importance of prevention and screening, and calls for the evaluation of an enhanced treatment either by associating corticosteroids or by using higher doses or more prolonged courses of treatment.

Ethical Approval

All procedures performed in studies involving human participants were in accordance with the 1964 Helsinki declaration and its later amendments.

Author contributions

V.R. performed the literature review, the statistical analysis and wrote the article.

J.G., B.B. and M.M. provided the ophthalmological data.

J.G. helped on the classification and analysis of ophthalmological data.

C.C., R.T. provided clinical data.

L.P., M.P.C. provided biological data and helped on their analyses.

F.C. supervised V.R. in writing tables.

E.C. supervised V.R. in performing the literature review and writing the article.

Disclosure of interest

The authors declare that they have no competing interest.

References

- [1] Ndeikoundam N, Viriot D, Fournet N, et al. Bacterial sexually transmitted infections in France: recent trends and patients' characteristics in 2016. *Euro Surveill* 2019;24:1–8.
- [2] Trickey A, May MT, Vehreschild J-J, et al. Survival of HIV-positive patients starting antiretroviral therapy between 1996 and 2013: a collaborative analysis of cohort studies. *Lancet HIV* 2017;4:e349–56.
- [3] Ghanem KG, Erbeling EJ, Wiener ZS, Rompalo AM. Serological response to syphilis treatment in HIV-positive and HIV-negative patients attending sexually transmitted diseases clinics. *Sex Transm Infect* 2007;83:97–101.
- [4] Marra CM, Maxwell CL, Tantaló L, et al. Normalization of cerebrospinal fluid abnormalities after neurosyphilis therapy: does HIV status matter? *Clin Infect Dis* 2004;38:1001–6.
- [5] Farhi D, Benhaddou N, Grange P, Zizi N, et al. Clinical and serologic baseline and follow-up features of syphilis according to HIV status in the post-HAART era. *Medicine (Baltimore)* 2009;88:331–40.
- [6] Lukehart SA, Hook EW, Baker-Zander SA, Collier AC, Critchlow CW, Handsfield HH. Invasion of the central nervous system by *Treponema pallidum*: implications for diagnosis and treatment. *Ann Intern Med* 1988;109:855–62.
- [7] Clark EG, Danbolt N. The Oslo study of the natural history of untreated syphilis: an epidemiologic investigation based on a restudy of the Boeck-Bruusgaard material; a review and appraisal. *J Chronic Dis* 1955;2:311–44.
- [8] de Voux A, Kidd S, Torrone EA. Reported Cases of Neurosyphilis Among Early Syphilis Cases—United States, 2009 to 2015. *Sex Transm Dis* 2017;45(1).
- [9] Oliver SE, Aubin M, Atwell L, et al. Ocular Syphilis – Eight Jurisdictions, United States, 2014–2015. *MMWR Morb Mortal Wkly Rep* 2016;65:1185–8.
- [10] Katz DA, Berger JR, Duncan RC. Neurosyphilis. A comparative study of the effects of infection with human immunodeficiency virus. *Arch Neurol* 1993;50:243–9.
- [11] Flood JM, Weinstock HS, Guroy ME, et al. Neurosyphilis during the AIDS epidemic, San Francisco, 1985–1992. *J Infect Dis* 1998;177:931–40.
- [12] Wang Z, Liu L, Shen Y-Z, et al. The clinical and laboratory features of neurosyphilis in HIV-infected patients: A retrospective study in 92 patients. *Medicine (Baltimore)* 2018;97:e0078.
- [13] Conde-Sendín MA, Amela-Peris R, et al. Current clinical spectrum of neurosyphilis in immunocompetent patients. *Eur Neurol* 2004;52:29–35.
- [14] Golden MR, Marra CM, Holmes KK. Update on Syphilis: Resurgence of an Old Problem. *JAMA* 2003;290:1510–4.
- [15] Davis LE, Schmitt JW. Clinical significance of cerebrospinal fluid tests for neurosyphilis. *Ann Neurol* 1989;25:50–5.
- [16] Janier M, Hegyi V, Dupin N, et al. 2014 European guideline on the management of syphilis. *J Eur Acad Dermatol Venereol JEADV* 2014;28:1581–93.
- [17] Centers for Disease Control Prevention. Sexually Transmitted Diseases: Summary of 2015 CDC Treatment Guidelines. *J Miss State Med Assoc* 2015;56:372–5.
- [18] Wong T, Fonseca K, Chernesky MA, Garceau R, Levett PN, Serhir B. Canadian Public Health Laboratory Network laboratory guidelines for the diagnosis of neurosyphilis in Canada. *Can J Infect Dis Med Microbiol* 2015;26:18A–22A.
- [19] BiostaTGV - Statistiques en ligne. <http://marne.u707.jussieu.fr/biostatgv/?module=tests>.
- [20] Girszyn N, Fares J, Proust F, et al. Le berger et la blanche ingénue. *Rev Med Interne* 2011;32(12):770–2.
- [21] Mathew RG, Goh BT, Westcott MC. British Ocular Syphilis Study (BOSS): 2-year national surveillance study of intraocular inflammation secondary to ocular syphilis. *Invest Ophthalmol Vis Sci* 2014;55:5394–400.
- [22] Rolfs RT, Joesoef MR, Hendershot EF, Rompalo AM, Augenbraun MH, Chiu M, et al. A randomized trial of enhanced therapy for early syphilis in patients with and without human immunodeficiency virus infection. The Syphilis and HIV Study Group. *N Engl J Med* 1997;337:307–14.
- [23] Hoogewoud F, Frumholtz L, Loubet P, et al. Prognostic Factors in Syphilitic Uveitis. *Ophthalmology* 2017;124:1808–16.
- [24] Davis AP, Stern J, Tantaló L, et al. How Well Do Neurologic Symptoms Identify Individuals With Neurosyphilis? *Clin Infect Dis* 2018;66:363–7.
- [25] Pratas AC, Goldschmidt P, Lebeaux D, et al. Increase in Ocular Syphilis Cases at Ophthalmology Reference Center, France, 2012–2015. *Emerg Infect Dis* 2018;24:193–200.
- [26] Shalaby IA, Dunn JP, Semba RD, Jabs DA. Syphilitic uveitis in human immunodeficiency virus-infected patients. *Arch Ophthalmol Chic Ill* 1990;108:715–73.
- [27] Merritt HH, Adams RD, Solomon HC. Neurosyphilis. Oxford University Press; 1946. p. 443.
- [28] Smibert OC, Abbinga S, Spelman DW, Jenney AWJ. Neurosyphilis: Concordance between cerebrospinal fluid analysis and subsequent antibiotic strategy for patients undergoing evaluation of a diagnosis of neurosyphilis. *Int J Infect Dis* 2019;82:73–6.
- [29] Shann S, Wilson J. Treatment of neurosyphilis with ceftriaxone. *Sex Transm Infect* 2003;79:415–6.
- [30] Amode R, Makhloufi S, Calin R, Caumes E. Oral doxycycline for syphilitic uveitis: a case report highlighting potential efficacy. *J Antimicrob Chemother* 2018;73:1999–2000.
- [31] Tuddenham S, Ghanem KG. Ocular syphilis: opportunities to address important unanswered questions. *Sex Transm Infect* 2016;92:563–5.