



HAL
open science

Sudden rotation and technique for repositioning Add-On® piggy-back sulcus toric intraocular lenses

G. Boutillier, J. Gueudry, S. Aouidid, M. Muraine

► To cite this version:

G. Boutillier, J. Gueudry, S. Aouidid, M. Muraine. Sudden rotation and technique for repositioning Add-On® piggy-back sulcus toric intraocular lenses. *Journal Français d'Ophtalmologie*, 2021, 44 (5), pp.e287-e290. 10.1016/j.jfo.2020.07.015 . hal-03238757

HAL Id: hal-03238757

<https://normandie-univ.hal.science/hal-03238757>

Submitted on 27 May 2021

HAL is a multi-disciplinary open access archive for the deposit and dissemination of scientific research documents, whether they are published or not. The documents may come from teaching and research institutions in France or abroad, or from public or private research centers.

L'archive ouverte pluridisciplinaire **HAL**, est destinée au dépôt et à la diffusion de documents scientifiques de niveau recherche, publiés ou non, émanant des établissements d'enseignement et de recherche français ou étrangers, des laboratoires publics ou privés.

Sudden rotation and technique for repositioning Add-On® piggy-back sulcus toric intraocular lenses



Rotation brutale d'un implant torique de sulcus piggy-back de type Add-On® et technique de repositionnement

Introduction

Sulcus intraocular lenses (IOLs) have proved effective in the surgical correction of severe astigmatism in pseudophakic eyes after penetrating keratoplasty [1,2] and in cases of refractive error after cataract surgery [3]. Three types of sulcus implant are currently available: Sulcoflex® (Rayner, Worthing, United Kingdom), an acrylic monobloc implant with open C-shaped haptics; AddOn® (1stQ GmbH, Mannheim, Germany), an acrylic hydrophile with four closed haptics; Add-On® (HumanOptics, Erlangen, Germany), composed of silicon, with two C-shaped haptics made of polymethylacrylate (PMMA) (Fig. 1). The haptics of the toric forms of Sulcoflex® and Add-On® (HumanOptics, Erlangen, Germany) lenses are modified and crenelated to prevent postoperative rotation and ensure the stable correction of astigmatism. Their geometry has been specifically designed to facilitate adaptation to all forms of sulcus. However, although the spherical and/or multifocal forms of these implants have been widely used and described [1,3], the use of their toric forms to correct postoperative astigmatism has been the subject of only a few case reports and a single study of a series of twenty patients. In this latter series, Thomas reported the occurrence of five cases (25% of the patients in the series) of postoperative rotation requiring simple repositioning [1].

Here we report two novel cases of sudden and severe rotation of Add-On® IOLs (HumanOptics, Erlangen, Germany). We also describe a technique to stabilize these implants in the long term.

Case 1

The first patient was a 55-year-old man with posterior chamber IOL and a history of penetrating keratoplasty on the left eye for the treatment of advanced keratoconus. After surgery, he displayed regular, residual, symmetric corneal astigmatism of 12 D, which was treated with an Add-On® IOL (HumanOptics, Erlangen, Germany) 12 D cylindrical and -5 D spherical. The IOL was placed in the sulcus at an angle of 67°. Preoperative refraction was + 5–9 × 160°, and,

at one month after surgery, the patient had recovered a visual acuity of 20/32 with a refraction of + 1–2 × 30°. Two months after surgery, the patient presented to the emergency department for a sudden decrease in visual acuity (occurring in less than 24 hours), limited to 20/400, with no identified trigger factor. Refraction was + 5–11 × 135°. Slit-lamp examination showed the implant to be centrally positioned but at an angle of 112°, corresponding to a rotation of 45° anticlockwise (Fig. 2a). The patient had surgery to correct this rotation, in which the implant was realigned along the correct axis and fixed in place by suture to the iris (Fig. 2b), according to the modified McCannel technique (Siepser knot), to prevent recurrence. We used a slightly modified protocol of this technique, in which we passed behind the arm of the implant. The rigidity of the polymethylacrylate (PMMA) of the haptic made it possible to fix it in place and to pass a needle carrying Prolène® 10.0 (Ethicon, Issy-les-Moulineaux, France) suture behind the arm and through the iris. One month after repositioning the implant, the patient had a visual acuity of 20/32, with a refraction of + 0.75–1.75 × 20°. His visual acuity three months after surgery was 20/25, with a correction of + 0.75–1 × 15°, and examination of the anterior segment revealed that the implant was stably positioned along the correct axis. Two years later, refraction and visual acuity remained stable.

Case 2

The second patient was a 76-year-old man with astigmatism who had cataract surgery on his right eye, with the insertion of a spherical implant into the posterior chamber. He subsequently presented a residual postoperative refraction of -3.25 × 20°, which was treated with an Add-On® (HumanOptics, Erlangen, Germany) cylindrical + 4 D toric implant positioned at an angle of 112°. One month after surgery, the patient had recovered a visual acuity of 20/25 without correction. Two months after the intervention, the patient presented to the emergency department for a sudden decrease in uncorrected visual acuity in the absence of a known trigger factor. However, with a correction of + 3–5 × 0°, the patient had a visual acuity of 20/20. Examination of the anterior segment revealed that the implant was lying on the 161° axis, corresponding to a rotation of 49° anticlockwise (Fig. 3a). The patient underwent an intervention to realign the implant along its initial axis and to fix it in place by suture to the iris as described above (Fig. 3b and Video). The patient had an uncorrected distance visual acuity of 20/25 at one month and of 20/20 (with -0.25–0.50 × 165°) at one year.

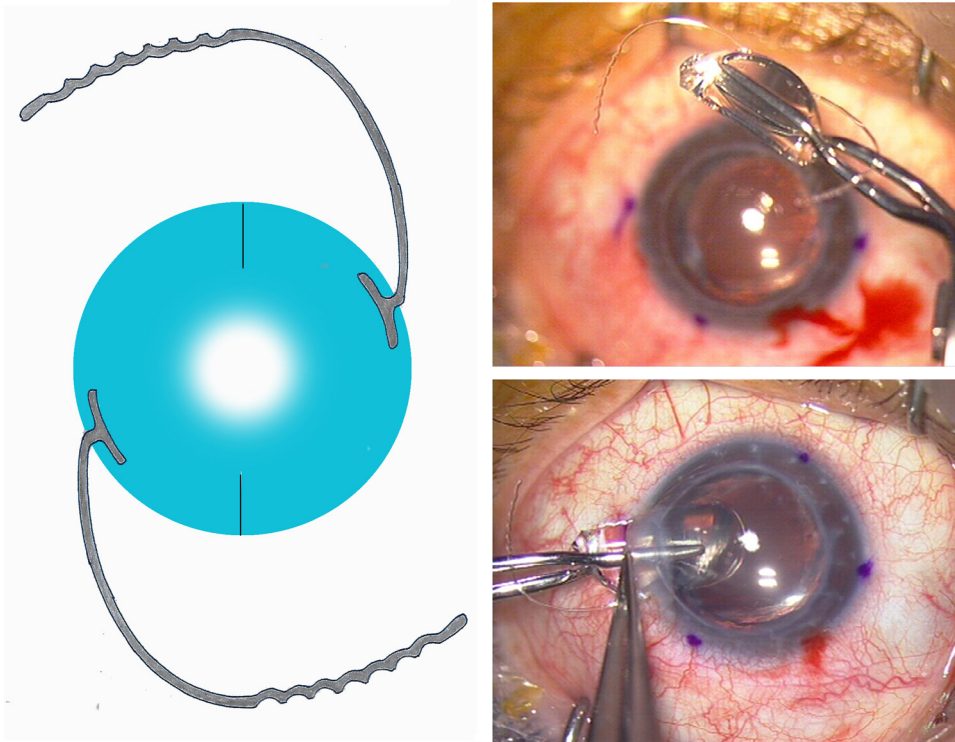


Figure 1. The toric piggy-back IOL Add-On® (HumanOptics, Erlangen, Germany). Implantation in one case of severe astigmatism following penetrating keratoplasty.

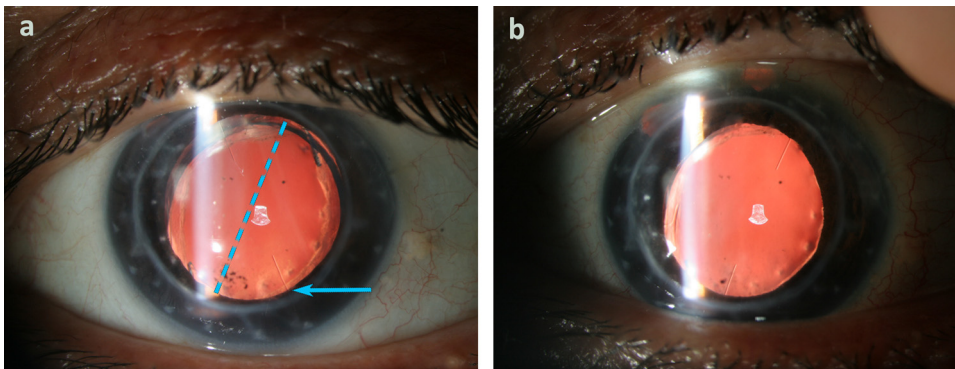


Figure 2. a: 45° spontaneous anticlockwise rotation of the piggy-back IOL (blue arrow indicates axis of 112°); blue line indicates initial axis; b: position of the IOL after realignment and fixation with Siepser knot on the initial axis.

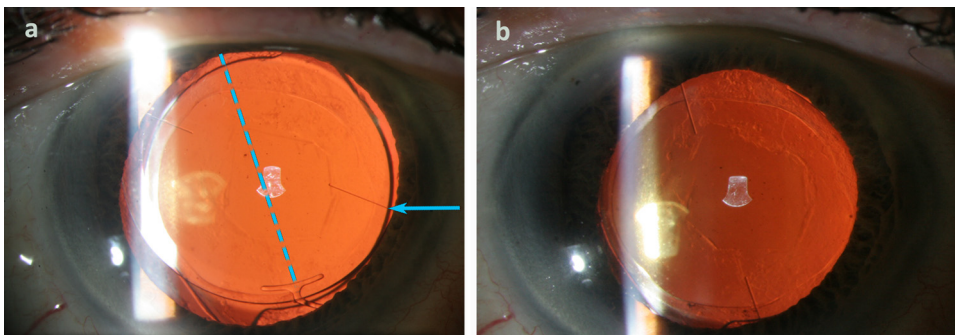


Figure 3. a: Add-On® IOL on the axis of 161° corresponding to an anticlockwise rotation of 49° (initial axis at 112°); b: Add-On® IOL on the correct axis of 112° after repositioning and fixation with Siepser knot.

Discussion

Disabling postoperative astigmatism may occur in patients undergoing cataract surgery. This is especially the case with refractive error or if astigmatism is not compensated by a toric implant or, more frequently, after corneal transplantation in combined procedures. Whatever the type of toric implant used, the postoperative refractive result is optimal only if the implant is aligned precisely along the axis of astigmatism. Defective alignment has long been known to decrease the power of the implant to correct astigmatism. We know that a 10° error in the alignment of the axis can lead to a 34 % decrease in the correction of astigmatism, and a rotation of 30° cancels out any corrective effect [4].

Unlike capsular bag implants, sulcus implants are in an open space and can therefore rotate either soon after surgery or subsequently. The sulcus does not close, so the implant is not imprisoned and can therefore move freely. It can thus rotate at any time, as reported for anterior chamber implants.

To prevent this complication, manufacturers of sulcus implants have developed anchoring systems ensuring a much higher degree of postoperative stability. The toric version of Add-On® implants (HumanOptics, Erlangen, Germany) uses a system of undulations at the ends of the haptics and an increased total diameter of the implant to ensure contact with the sulcus for all eye diameters. Despite these improvements, Thomas [1] observed five cases of rotation in his study of twenty-one Add-On® implants (HumanOptics, Erlangen, Germany) used to treat residual ametropia after penetrating keratoplasty. The implant was repositioned in these five patients, but rotated again in two cases. However, no detail was provided concerning the timing of the rotation, its suddenness, or the direction of rotation. This study shows that simple repositioning can be insufficient (two out of five cases of repositioning presented a recurrence of the rotation).

Interestingly, in both our cases, the open-haptic implants rotated in an anticlockwise direction, as reported in the past for anterior chamber implants [5], for which 80% of cases of rotation were also anticlockwise. Simple rubbing of the eyes may lead to movement of the implant in some cases. Rotation of the implant is thus possible, and appears to occur in an anticlockwise direction. We describe here in detail the cases of two patients displaying a rotation of the implant two months after this intervention. This rotation of around 45° in both cases occurred over the space of 24 hours and may thus be considered as sudden. The geometry of the haptics of the implants used causes them to turn in an anticlockwise direction.

Ophthalmological surgeons should be aware of this complication, particularly as it is possible to fix the implant so that it cannot rotate. The suture of posterior chamber implants to the iris is well known, mostly carried out with the McCannel technique. This technique is used for suturing a subluxated bag implant to the iris [6], fixing luxated posterior chamber implants to the iris [7], suturing implants to the iris in aphakic eyes with no capsular support [8], and repairing eyes with iris coloboma or after eye trauma [9]. However, no technique has ever been described for the fixation of add-on sulcus implants. Therefore, we adapted this type of suture to our two cases. The simple repositioning of

the implant would not have prevented recurrence. Thus we considered that it was necessary to fix the implant definitively. It was possible to use this technique because the patients were fitted with Add-On® (HumanOptics, Erlangen, Germany) sulcus implants, which have PMMA haptics visible through the iris.

Conclusion

Sulcus toric implants are subject to a risk of rotation despite their crenelated haptics, like the anterior chamber implants, which frequently rotated anticlockwise. In cases of rotation, the implant should be repositioned along the correct axis and fixed in place definitively, so as to prevent any subsequent sudden rotation. Through the two cases reported here, we describe a novel technique for the fixation of add-on sulcus toric implants.

Acknowledgments

The authors are grateful to Nikki Sabourin-Gibbs, Rouen University Hospital, for her help in editing the manuscript.

Disclosure of interest

The authors declare that they have no competing interest.

Appendix A. Supplementary data

Supplementary data associated with this article can be found, in the online version, at <https://doi.org/10.1016/j.jfo.2020.07.015>.

References

- [1] Thomas BC, Auffarth GU, Reiter J, Holzer MP, Rabsilber TM. Implantation of three-piece silicone toric additive IOLs in challenging clinical cases with high astigmatism. *J Refract Surg* 2013;29:187–93.
- [2] Linz K, Auffarth GU, Kretz FTA. Implantation of a sulcus-fixated toric additive intraocular lens in a case of high astigmatism after a triple procedure. *Klin Monatsblätter Für Augenheilkd* 2014;231:788–92.
- [3] Basarir B, Kaya V, Altan C, Karakus S, Pinarci EY, Demirok A. The use of a supplemental sulcus fixated IOL (HumanOptics Add-On IOL) to correct pseudophakic refractive errors. *Eur J Ophthalmol* 2012;22:898–903.
- [4] Jin H, Limberger I-J, Ehmer A, Guo H, Auffarth GU. Impact of axis misalignment of toric intraocular lenses on refractive outcomes after cataract surgery. *J Cataract Refract Surg* 2010;36:2061–72.
- [5] Pérez-Santonja JJ, Alió JL, Jiménez-Alfaro I, Zato MA. Surgical correction of severe myopia with an angle-supported phakic intraocular lens. *J Cataract Refract Surg* 2000;26:1288–302.
- [6] Michaeli A, Soiberman U, Loewenstein A. Outcome of iris fixation of subluxated intraocular lenses. *Graefes Arch Clin Exp Ophthalmol* 2012;250:1327–32.
- [7] Chang DF. Siepser slipknot for McCannel iris-suture fixation of subluxated intraocular lenses. *J Cataract Refract Surg* 2004;30:1170–6.
- [8] Condon GP, Masket S, Kranemann C, Crandall AS, Ahmed IIK. Small-incision iris fixation of foldable intraocular lenses in the absence of capsule support. *Ophthalmology* 2007;114:1311–8.
- [9] Cionni RJ, Karatza EC, Osher RH, Shah M. Surgical technique for congenital iris coloboma repair. *J Cataract Refract Surg* 2006;32:1913–6.

G. Boutillier^{a,*}, J. Gueudry^a, S. Aouidid^b,
M. Muraine^a

^a *Service d'ophtalmologie, CHU de Rouen, 1, rue
de Germont, 76031 Rouen cedex, France*

^b *Service d'ophtalmologie, clinique Saint-Hilaire,
2, place Saint-Hilaire, 76000 Rouen, France*

* Corresponding author.

E-mail address: guillaume.boutillier@chu-rouen.fr

(G. Boutillier)

Available online 12 February 2021

<https://doi.org/10.1016/j.jfo.2020.07.015>