



HAL
open science

The Microbiology of suppurative Pilonidal Sinus Disease: another link with Hidradenitis Suppurativa

H. Guet-Revillet, Maïa Delage, É Riverain-Gillet, J-P Jais, M-N Ungeheueur, P-H Consigny, N. Lemarchand, V. de Parades, Aude Nassif, O. Join-Lambert

► **To cite this version:**

H. Guet-Revillet, Maïa Delage, É Riverain-Gillet, J-P Jais, M-N Ungeheueur, et al.. The Microbiology of suppurative Pilonidal Sinus Disease: another link with Hidradenitis Suppurativa. 9TH CONFERENCE OF THE EUROPEAN HIDRADENITIS SUPPURATIVA FOUNDATION, Feb 2020, Athènes, Greece. hal-02911693

HAL Id: hal-02911693

<https://normandie-univ.hal.science/hal-02911693v1>

Submitted on 4 Aug 2020

HAL is a multi-disciplinary open access archive for the deposit and dissemination of scientific research documents, whether they are published or not. The documents may come from teaching and research institutions in France or abroad, or from public or private research centers.

L'archive ouverte pluridisciplinaire **HAL**, est destinée au dépôt et à la diffusion de documents scientifiques de niveau recherche, publiés ou non, émanant des établissements d'enseignement et de recherche français ou étrangers, des laboratoires publics ou privés.

Background

Intergluteal lesions are associated with Hidradenitis Suppurativa (HS) in up to 27% of cases and there are accumulating evidences suggesting that pilonidal sinus disease (PSD) may be a variant form of Hidradenitis suppurativa¹. The microbiology of HS lesions has been recently characterized, showing that a specific anaerobic flora is associated with a vast majority of HS lesions²⁻⁵.

Aim of the study

To characterize the microbiology of suppurative PSD compared to HS gluteal lesions.

Methods

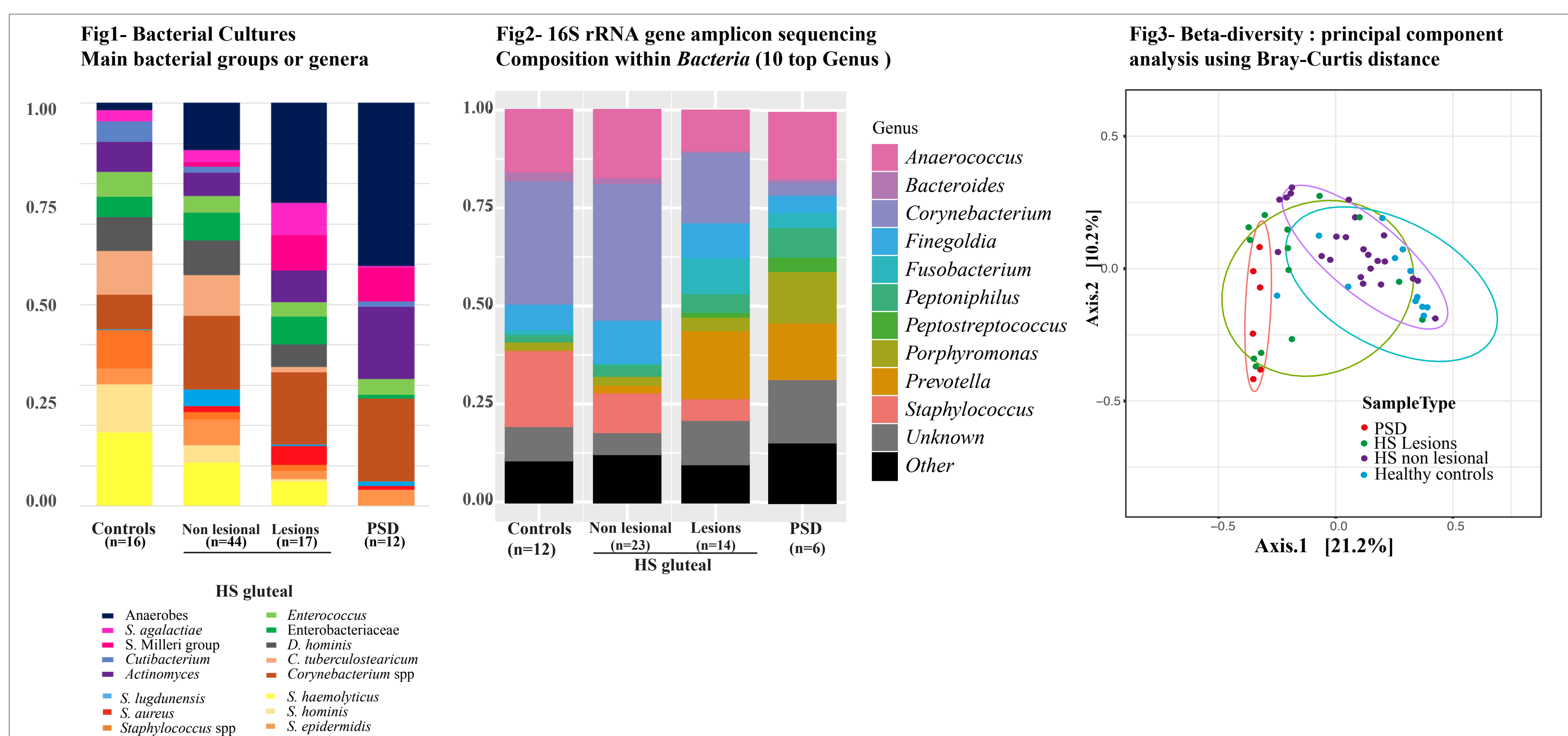
Cross-sectional study realised in Paris, France. We compared the microbiology of 12 suppurative PSD to that of 17 intergluteal HS lesions, of 44 clinically non affected HS gluteal skinfold and of 16 in healthy subjects. Patients with PSD had no other skin lesions and were recruited at the Saint-Joseph Hospital Leopold Bellan clinic, a surgical specialized center in Paris. HS subjects and controls were recruited at the Dermatology Unit of the Centre Médical and at the ICAReB Platform of the Institut Pasteur, respectively.

All sample were obtained by pus or surface skin swabbing, except for PSD samples that were obtained during surgery. No patients received antibiotics during the month preceding inclusion. All samples were analysed by prolonged bacterial cultures. 16S ribosomal RNA gene amplicon sequencing was performed on 50 randomly selected samples including 6 PSD samples.

Results

Bacterial culture results (Fig 1). The microbiology of PSD was typical of anaerobic abscesses, consisting in **strict anaerobes (40%), Actinomyces spp (18%), pyogenic streptococci (9%),** associated with *Corynebacterium* spp (21%). This microbiological profile was similar to that of HS gluteal lesions.

16S ribosomal gene amplicon sequencing sequencing results (Fig 2 and 3). *Corynebacterium*, *Staphylococcus*, *Anaerococcus* and *Finigoldia* were the most abundant genera in unaffected gluteal HS skinfolds and controls. The microbiome of PSDs and HS gluteal lesions was predominantly anaerobic, *Prevotella*, *Porphyromonas*, *Fusobacterium*, and *Peptoniphilus* being the main taxa. The relative abundance of skin commensals (*Staphylococcus* and *Corynebacterium*) was higher in HS lesions skin samples, probably due to the sampling method.



Discussion and conclusion

The microbiology of suppurative PSD is typical of polymicrobial anaerobic abscesses and similar to that of gluteal HS lesions. As previously reported in HS²⁻⁵, *Prevotella* and *Porphyromonas* are the main anaerobic taxa, establishing a new link between the two diseases and suggesting common pathophysiological features.

References

- 1- Benhadou et al, Br J Dermatol, 2019
- 2- Guet-revillet et al Emerging Infect Dis, 2014
- 3- Guet-revillet et al, Clin Infect Dis, 2017
- 4- Ring et al, JAMA Dermatol, 2017
- 5- Ring et al, JEADV, 2019