



HAL
open science

Reversal of a Blunted Follicle-Stimulating Hormone by Chemotherapy in an Inhibin B–Secreting Adrenocortical Carcinoma

Stéphanie Espiard, Najiba Lahlou, Mathilde Sibony, Estelle Louiset, Marie Bienvenu, Jérôme Bertherat, Bertrand Dousset, Lionel Groussin, Rossella Libé

► **To cite this version:**

Stéphanie Espiard, Najiba Lahlou, Mathilde Sibony, Estelle Louiset, Marie Bienvenu, et al.. Reversal of a Blunted Follicle-Stimulating Hormone by Chemotherapy in an Inhibin B–Secreting Adrenocortical Carcinoma. *Journal of the Endocrine Society*, 2017, 1 (1), pp.46-50. 10.1210/js.2016-1009 . hal-01945843

HAL Id: hal-01945843

<https://normandie-univ.hal.science/hal-01945843v1>

Submitted on 6 Jan 2025

HAL is a multi-disciplinary open access archive for the deposit and dissemination of scientific research documents, whether they are published or not. The documents may come from teaching and research institutions in France or abroad, or from public or private research centers.

L'archive ouverte pluridisciplinaire **HAL**, est destinée au dépôt et à la diffusion de documents scientifiques de niveau recherche, publiés ou non, émanant des établissements d'enseignement et de recherche français ou étrangers, des laboratoires publics ou privés.

Reversal of a Blunted Follicle-Stimulating Hormone by Chemotherapy in an Inhibin B–Secreting Adrenocortical Carcinoma

Stéphanie Espiard,^{1*} Najiba Lahlou,^{2*} Mathilde Sibony,³ Estelle Louiset,⁶
Marie Bienvenu,⁴ Jérôme Bertherat,^{1,7} Bertrand Dousset,^{5,7} Lionel Groussin,^{1,7*}
and Rossella Libé^{1,8*}

*Departments of ¹Endocrinology, ²Hormonology, ³Pathology, ⁴Nuclear Medicine, and
⁵Endocrine Surgery, Cochin Hospital, 75014 Paris, France;*

*⁶Institut National de la Santé et de la Recherche Médicale Unité 982, Laboratory of Neuronal and
Neuroendocrine Differentiation and Communication, Institute for Research and Innovation in
Biomedicine, France University of Rouen, 76130 Mont-Saint-Aignan, France;*

*⁷Institut National de la Santé et de la Recherche Médicale Unité 1016, Centre National de la Recherche
Scientifique Unité Mixte de Recherche 8104, Université Paris-Descartes, Institut Cochin, 75014 Paris,
France; and*

⁸French Network for Adrenal Cancer, Cochin Hospital, 75014 Paris, France

Context: Adrenocortical carcinomas (ACCs) are revealed in 60% of cases by steroid hypersecretion. Alternatively, it is uncommon to observe a paraneoplastic syndrome due to a peptide oversecretion.

Case Description: We describe a 60-year-old man with a right adrenal mass. Hormonal evaluation showed an ACTH-independent Cushing syndrome. Surprisingly, follicle-stimulating hormone (FSH) levels were suppressed and blunted during gonadotropin-releasing hormone stimulation, despite normal luteinizing hormone levels. Levels of inhibin B, which negatively regulates the pituitary FSH, were very high. Given the atypical hormonal findings, an adrenal mass biopsy was performed, which allowed the diagnosis of an adrenocortical tumor (positive for steroidogenic factor-1 immunostaining). Moreover, an intense α -inhibin subunit immunostaining was observed. Because of the presence of metastases, the patient received mitotane and chemotherapy (etoposide and cisplatin). After 2 cycles, the inhibin B dropped. After 5 cycles, tumor size was reduced by 15%. Inhibin B levels remained low, and basal and gonadotropin-releasing hormone–stimulated FSH levels normalized. The patient underwent tumor resection, and pathology confirmed the ACC diagnosis (Weiss score of 9). The intensity of the α -inhibin subunit immunostaining was significantly decreased.

Conclusions: We report the case of an inhibin B–secreting ACC in which the response to chemotherapy and mitotane was associated with a normalization of inhibin B secretion, allowing the reversal of the blunted FSH secretion. Inhibin B should be measured in case of suppressed FSH levels despite normal luteinizing hormone levels and may be considered a tumoral marker in some ACCs, even during treatment follow-up.

Copyright © 2017 by the Endocrine Society

This article has been published under the terms of the Creative Commons Attribution License (CC BY-NC-ND; <https://creativecommons.org/licenses/by-nc-nd/4.0/>).

Freeform/Key Words: inhibin B, adrenocortical carcinoma, tumor marker

Adrenocortical carcinoma (ACC) is a rare malignancy of the adrenal gland with a poor prognosis, especially in metastatic stages, with a 5 year overall survival of 0% to 15%, depending on the series. ACC presents with symptoms caused by hormone production (glucocorticoids, androgens, mineralocorticoids, or estrogens) in ~60% of the cases [1].

*These authors contributed equally to this study.

Abbreviations: ACC, adrenocortical carcinoma; FSH, follicle-stimulating hormone; GnRH, gonadotropin-releasing hormone; IGF2, insulin-like growth factor 2; LH, luteinizing hormone

On the contrary, peptide oversecretion has rarely been reported. Because the insulin-like growth factor 2 (*IGF2*) gene is overexpressed in most sporadic ACCs, circulating levels of IGF2 were quantified in patients with adrenal tumors. However, these levels were similar in benign and malignant adrenal tumors and showed no correlation with overall or progression-free survival [2]. In exceptional cases, ACCs can produce and secrete big-IGF2, leading to hypoglycemia, as reported in 1 out of 78 patients with non-islet cell tumor hypoglycemia [3].

Hofland *et al.* [4] found that the serum inhibin pro- α C might be a helpful diagnostic tool to discriminate ACCs from benign adrenal tumors and might serve as a tumor marker for ACCs during treatment follow-up. Inhibin pro- α C is the precursor form of inhibin α -subunit (encoded by *INH1A*). Inhibin A and B are 2 dimeric peptidic hormones belonging to the transforming growth factor- β family and consist of the common α -subunit dimerized with a β -subunit (β A-subunit for inhibin A and β B-subunit for inhibin B). β -Subunits are ubiquitously expressed, whereas the α -subunit is only expressed in the ovary, testis, placenta, and adrenal cortex [5]. Circulating inhibin B comes from gonad and negatively regulates the pituitary follicle-stimulating hormone (FSH) secretion [6].

In this study, we describe the case of a patient presenting with an ACC and a blunted FSH related to a tumoral secretion of inhibin B, which was reversed after chemotherapy.

1. Case Presentation

A 60-year-old man had been admitted to the hospital for a right intermittent abdominal pain for 1 week. The computed tomography showed a retroperitoneal mass (145 × 100 mm) associated with peritoneal and lung metastases and pulmonary hilar lymph nodes [Fig. 1(A)]. The patient was transferred to the endocrine unit. His previous medical history included hypertension that was treated in the last year by β -blocker, spironolactone, and thiazide diuretic. The magnetic resonance imaging was in favor of an adrenal mass and showed a venous tumor thrombus in vena cava and in renal vein. ¹⁸F-fluorodeoxyglucose positron emission tomography showed an uptake of the retroperitoneal mass (standardized uptake value maximum adrenal/liver ratio of 3.7), the peritoneal metastases, and the pulmonary hilar lymph nodes, suggesting a malignant tumor [Fig. 1(B)]. Clinically, there was no evidence of Cushing syndrome and no alteration of general conditions. Hormonal investigation showed ACTH-independent hypercortisolism with a suppressed ACTH < 2 pmol/L (range, 2 to 13) and 24 hours urinary-free cortisol at 441 nmol/24 h (range, 69 to 248). Surprisingly, the follicle stimulating hormone (FSH) levels were suppressed (0.14 IU/L; normal, 1 to 12) and remained blunted during gonadotropin-releasing hormone (GnRH) stimulation, whereas basal (3.7 IU/L; normal, 0.8 to 12) and stimulated luteinizing hormone (LH) levels were normal (Fig. 2). To explain this dissociation between low FSH levels and normal LH levels, measurement of inhibin B was performed and revealed very high levels (1100 pg/mL; normal, 28 to 294). Estradiol (168.5 pmol/L; normal, 36 to 220), testosterone (13.3 nmol/L; normal, 8.3 to 34.5), dehydroepiandrosterone sulfate (4.9 μ mol/L; normal, 4.5 to 8.5), 17-hydroxyprogesterone (13.5 nmol/L; normal, 8.3 to 34.5), and inhibin A (2 pg/mL; normal, 0.5 to 2.5) levels were normal. Given the atypical hormonal findings, a percutaneous mass biopsy was performed to have a pathological diagnosis. Immunohistochemistry showed a strong nuclear staining for steroidogenic factor-1, favoring the diagnosis of adrenocortical tumor. Labeling of ACC sections with an anti-inhibin α -subunit antibody revealed an intense and diffuse immunostaining consistent with the high inhibin B levels [Fig. 1(C)]. Given the metastatic disease (European Network for the Study of Adrenal Tumors stage 4), the patient was treated with mitotane and chemotherapy (etoposide and cisplatin), in agreement with the international recommendation [1]. After 2 cycles, although mitotane levels were not yet in the therapeutic range (7.56 mg/L, therapeutic levels > 14 mg/L), inhibin B levels dropped (15 pg/mL). After 5 cycles, both the ACC and the pulmonary hilar lymph node sizes were reduced by 15%, suggesting a stabilization of the disease. Inhibin B levels remained low (10 pg/mL) and basal and GnRH-stimulated FSH levels were normalized (Fig. 2). The patient underwent a tumor resection and the pathology confirmed the ACC diagnosis (Weiss score of 9), with positive

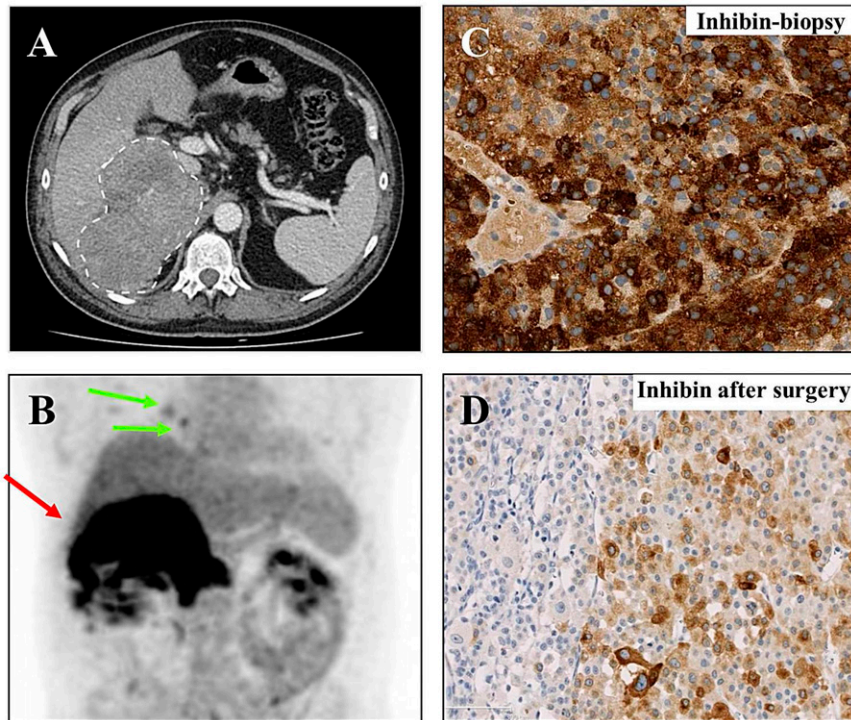


Figure 1. (A) Computed tomography scan at diagnosis showing a retroperitoneal mass (145 × 100 mm) (white dotted line). (B) ^{18}F -fluorodeoxyglucose positron emission tomography before mitotane and chemotherapy showing an uptake localized to pulmonary hilar lymph nodes (green arrows) and retroperitoneal mass with a maximum standardized uptake value of 10.2 and an adrenal/liver maximum standardized uptake value ratio of 3.7 (red arrow). (C) Biopsy: α -inhibin subunit immunostaining of the retroperitoneal mass (original magnification, $\times 20$). (D) α -Inhibin subunit immunostaining of adrenal mass after surgery (original magnification, $\times 20$).

steroidogenic factor-1 immunostaining. The intensity of the α -inhibin subunit immunostaining was significantly decreased and showed a different pattern than the one observed in the earlier biopsy [Fig. 1(D)].

2. Discussion

In this study, we report a case of an inhibin B–secreting ACC with complete normalization of inhibin levels after chemotherapy. Inhibin B hypersecretion leading to selective FSH suppression was previously documented in 2 patients with adrenocortical tumor: a 39-year-old man presenting with a feminizing adrenocortical adenoma [7], and a 30-year-old man presenting with an ACC causing abdominal pain and loss of libido [8]. In both cases, immunohistochemistry showed positive α -inhibin staining [7, 8]. In these 2 male patients, the high inhibin B levels were associated with high estradiol [7, 8] and estrone levels [7], whereas in the case described in this study, estradiol and testosterone were both normal. In the previous 2 cases, inhibin B levels were 1.5- to 2-fold above the upper limit of normal, whereas in this case the levels were 4.5-fold above the upper limit of normal. These observations suggest that inhibin B hypersecretion is sufficient to inhibit FSH, independently of estradiol and testosterone, and that inhibin B is the main physiologic negative feedback regulator of FSH secretion [8].

Secretion of inhibin B by ACCs may be underdiagnosed and underreported. Indeed, Hofland *et al.* [4] showed an increase of inhibin B in 3 out of 9 ACCs and an increase of inhibin pro- αC in 59% among 32 studied ACCs, whereas inhibin A was never increased, as observed in the present case. In this study, the observed decrease of inhibin pro- αC levels after surgery or mitotane led the authors to suggest using this peptide as a tumor marker during treatment and follow-up of ACCs.

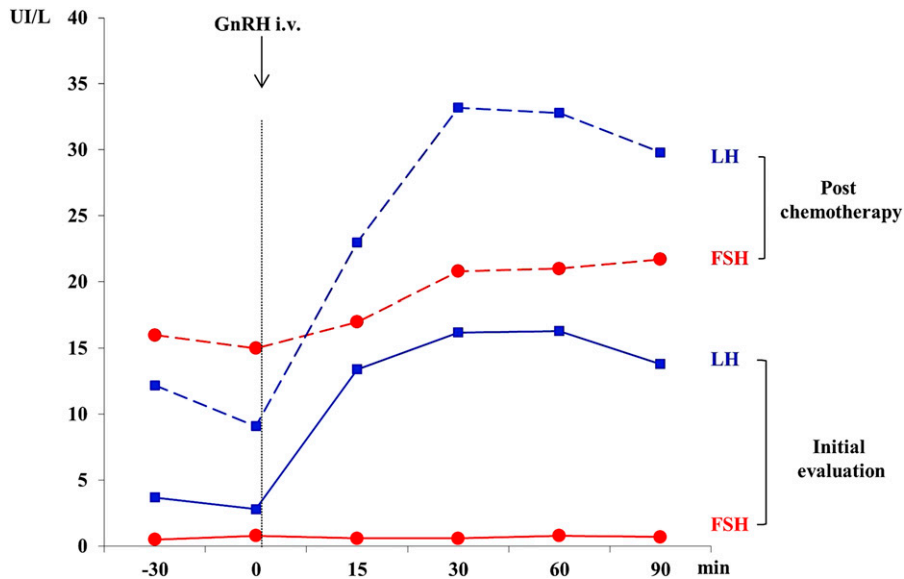


Figure 2. GnRH stimulation test: FSH response (red line) and LH response (blue line) at initial evaluation (solid line) and after chemotherapy (dotted line).

This case illustrates disease stabilization after mitotane and chemotherapy treatment, associated with a decrease in serum inhibin B levels. Interestingly, the decrease in circulating inhibin B levels was associated with a decrease of α -inhibin subunit immunostaining in the resected carcinoma, compared with the biopsy.

A tumoral elevation of serum inhibin B is mainly observed in ovarian tumors. An inhibin B increase is detected in ~90% of granulosa cell tumors (stromal sex-cord tumors) and in 60% of mucinous cystadenocarcinoma (epithelial ovarian tumors). Inhibin is less frequently increased in nonmucinous epithelial tumors (elevation of total inhibin in 15% to 35%). Some cases of Sertoli cell tumors may present an inhibin B hypersecretion, which correlates with a poor prognosis and a high risk of recurrence [9].

3. Conclusion

A decrease of FSH levels with normal LH levels should evoke inhibin B secretion in the context of an adrenal tumor. In this study, we report treatment of an ACC with a combination of chemotherapy and mitotane that leads to a decrease of inhibin B levels, a normalization of basal and stimulated FSH levels, as well as a reduction in tumor volume.

Acknowledgments

Address all correspondence to: Rossella Libé, MD, French Network for Adrenal Cancer, Department of Endocrinology, Cochin Hospital, 123 Boulevard Port Royal, 75014 Paris, France. E-mail: rossella.libe@aphp.fr

Disclosure Summary: The authors have nothing to disclose.

References and Notes

- Fassnacht M, Kroiss M, Allolio B. Update in adrenocortical carcinoma. *J Clin Endocrinol Metab.* 2013; **98**(12):4551–4564.
- Patel D, Ellis R, Howard B, Boufrajech M, Gara SK, Zhang L, Quezado MM, Nilubol N, Kebebew E. Analysis of IGF and IGFBP as prognostic serum biomarkers for adrenocortical carcinoma. *Ann Surg Oncol.* 2014;**21**(11):3541–3547.

3. Fukuda I, Hizuka N, Ishikawa Y, Yasumoto K, Murakami Y, Sata A, Morita J, Kurimoto M, Okubo Y, Takano K. Clinical features of insulin-like growth factor-II producing non-islet-cell tumor hypoglycemia. *Growth Horm IGF Res.* 2006;**16**(4):211–216.
4. Hofland J, Feelders RA, van der Wal R, Kerstens MN, Haak HR, de Herder WW, de Jong FH. Serum inhibin pro- α C is a tumor marker for adrenocortical carcinomas. *Eur J Endocrinol.* 2012;**166**(2):281–289.
5. Meunier H, Rivier C, Evans RM, Vale W. Gonadal and extragonadal expression of inhibin alpha, beta A, and beta B subunits in various tissues predicts diverse functions. *Proc Natl Acad Sci USA.* 1988;**85**(1): 247–251.
6. Suresh PS, Rajan T, Tsutsumi R. New targets for old hormones: inhibins clinical role revisited. *Endocr J.* 2011;**58**(4):223–235.
7. Kuhn JM, Lefebvre H, Duparc C, Pellerin A, Luton JP, Strauch G. Cosecretion of estrogen and inhibin B by a feminizing adrenocortical adenoma: impact on gonadotropin secretion. *J Clin Endocrinol Metab.* 2002;**87**(5):2367–2375.
8. Fragoso MCBV, Kohek MBF, Martin RM, Latronico AC, Lucon AM, Zerbini MC, Longui CA, Mendonca BB, Domenice S. An inhibin B and estrogen-secreting adrenocortical carcinoma leading to selective FSH suppression. *Horm Res.* 2007;**67**(1):7–11.
9. Risbridger GP, Schmitt JF, Robertson DM. Activins and inhibins in endocrine and other tumors. *Endocr Rev.* 2001;**22**(6):836–858.