



**HAL**  
open science

## **Intraadrenal Corticotropin in Bilateral Macronodular Adrenal Hyperplasia**

Estelle Louiset, Céline Duparc, Jacques Young, Sylvie Renouf, Milène Tetsi Nomigni, Isabelle Boutelet, Rossella Libé, Zakariae Bram, Lionel Groussin, Philippe Caron, et al.

### ► To cite this version:

Estelle Louiset, Céline Duparc, Jacques Young, Sylvie Renouf, Milène Tetsi Nomigni, et al.. Intraadrenal Corticotropin in Bilateral Macronodular Adrenal Hyperplasia. *New England Journal of Medicine*, 2013, 369 (22), pp.2115 - 2125. <10.1056/NEJMoa1215245>. <hal-01908272>

**HAL Id: hal-01908272**

**<https://normandie-univ.hal.science/hal-01908272v1>**

Submitted on 30 Oct 2018

**HAL** is a multi-disciplinary open access archive for the deposit and dissemination of scientific research documents, whether they are published or not. The documents may come from teaching and research institutions in France or abroad, or from public or private research centers.

L'archive ouverte pluridisciplinaire **HAL**, est destinée au dépôt et à la diffusion de documents scientifiques de niveau recherche, publiés ou non, émanant des établissements d'enseignement et de recherche français ou étrangers, des laboratoires publics ou privés.



HAL Authorization

## ORIGINAL ARTICLE

# Intraadrenal Corticotropin in Bilateral Macronodular Adrenal Hyperplasia

Estelle Louiset, Ph.D., Céline Duparc, Ph.D., Jacques Young, M.D., Ph.D., Sylvie Renouf, Ph.D., Milène Tetsi Nomigni, M.Sc., Isabelle Boutelet, Ph.D., Rossella Libé, M.D., Zakariae Bram, M.Sc., Lionel Groussin, M.D., Ph.D., Philippe Caron, M.D., Antoine Tabarin, M.D., Ph.D., Fabienne Grunenberger, M.D., Sophie Christin-Maitre, M.D., Ph.D., Xavier Bertagna, M.D., Ph.D., Jean-Marc Kuhn, M.D., Youssef Anouar, Ph.D., Jérôme Bertherat, M.D., Ph.D., and Hervé Lefebvre, M.D., Ph.D.

## ABSTRACT

**BACKGROUND**

Bilateral macronodular adrenal hyperplasia is a rare cause of primary adrenal Cushing's syndrome. In this form of hyperplasia, hypersecretion of cortisol suppresses the release of corticotropin by pituitary corticotrophs, which results in low plasma corticotropin levels. Thus, the disease has been termed corticotropin-independent macronodular adrenal hyperplasia. We examined the abnormal production of corticotropin in these hyperplastic adrenal glands.

**METHODS**

We obtained specimens of hyperplastic macronodular adrenal tissue from 30 patients with primary adrenal disease. The corticotropin precursor proopiomelanocortin and corticotropin expression were assessed by means of a polymerase-chain-reaction assay and immunohistochemical analysis. The production of corticotropin and cortisol was assessed in 11 specimens with the use of incubated explants and cell cultures coupled with hormone assays. Corticotropin levels were measured in adrenal and peripheral venous blood samples from 2 patients.

**RESULTS**

The expression of proopiomelanocortin messenger RNA (mRNA) was detected in all samples of hyperplastic adrenal tissue. Corticotropin was detected in steroidogenic cells arranged in clusters that were disseminated throughout the adrenal specimens. Adrenal corticotropin levels were higher in adrenal venous blood samples than in peripheral venous samples, a finding that was consistent with local production of the peptide within the hyperplastic adrenals. The release of adrenal corticotropin was stimulated by ligands of aberrant membrane receptors but not by corticotropin-releasing hormone or dexamethasone. A semiquantitative score for corticotropin immunostaining in the samples correlated with basal plasma cortisol levels. Corticotropin-receptor antagonists significantly inhibited *in vitro* cortisol secretion.

**CONCLUSIONS**

Cortisol secretion by the adrenals in patients with macronodular hyperplasia and Cushing's syndrome appears to be regulated by corticotropin, which is produced by a subpopulation of steroidogenic cells in the hyperplastic adrenals. Thus, the hypercortisolism associated with bilateral macronodular adrenal hyperplasia appears to be corticotropin-dependent. (Funded by the Agence Nationale de la Recherche and others.)

From INSERM Unité 982, Laboratory of Neuronal and Neuroendocrine Differentiation and Communication, Institute for Research and Innovation in Biomedicine, and Rouen University, Mont-Saint-Aignan (E.L., C.D., S.R., M.T.N., I.B., Z.B., J.-M.K., Y.A., H.L.), the Department of Endocrinology, Hôpital Bicêtre, Assistance Publique-Hôpitaux de Paris (AP-HP), University Paris Sud, INSERM Unité 693, Le Kremlin-Bicêtre (J.Y.), INSERM Unité 1016, Institut Cochin (R.L., L.G., X.B., J.B.), the Department of Endocrinology AP-HP, Hôpital Cochin (L.G., X.B., J.B.), Université Paris Descartes (L.G., X.B., J.B.), Centre National de la Recherche Scientifique Unité Mixte de Recherche 8104 (L.G., X.B., J.B.), and the Department of Endocrinology, Hôpital Saint-Antoine, AP-HP (S.C.-M.), Paris; the Department of Endocrinology and Metabolic Diseases, Centre Hospitalier Universitaire Larrey, Toulouse (P.C.); the Department of Endocrinology, Hôpital Haut Lévêque, Centre Hospitalier Universitaire de Bordeaux, Pessac (A.T.); Service de Médecine Interne et Nutrition, Centre Hospitalier Régional Universitaire de Strasbourg, Strasbourg (F.G.); and the Department of Endocrinology, Diabetes, and Metabolic Diseases, Rouen University Hospital, Rouen (J.M.K., H.L.) — all in France. Address reprint requests to Dr. Lefebvre at INSERM Unité 982, Department of Endocrinology, Institute for Research and Innovation in Biomedicine (IRIB), University Hospital of Rouen, 76031 Rouen CEDEX, France, or at herve.lefebvre@chu-rouen.fr.

N Engl J Med 2013;369:2115-25.

DOI: 10.1056/NEJMoa1215245

Copyright © 2013 Massachusetts Medical Society.

**C**HRONIC EXCESS OF GLUCOCORTICOIDs may lead to a constellation of symptoms that include central obesity and arterial hypertension, termed Cushing's syndrome, which is associated with increased mortality. In 10 to 20% of cases, Cushing's syndrome is caused by primary adrenal cortisol hypersecretion.<sup>1</sup> Among patients with primary hypersecretion of adrenal cortisol, bilateral macronodular adrenal disease is extremely rare, representing less than 2% of all cases of Cushing's syndrome. Hypersecretion of cortisol by the enlarged adrenal glands suppresses the release of corticotropin by the anterior pituitary, leading to low plasma levels of corticotropin. For this reason, the disease has also been called corticotropin-independent macronodular adrenal hyperplasia.

An understanding of the pathophysiology of corticotropin-independent macronodular adrenal hyperplasia has long been elusive. The persistence of cortisol hypersecretion despite suppressed plasma corticotropin levels was considered to be the result of an autonomous process. However, several studies published over the past two decades have shown that hyperplastic adrenal glands display abnormal expression of various membrane receptors that are involved in the control of cortisol production.<sup>2-6</sup> These aberrant receptors include ectopic receptors for glucose-dependent insulinotropic peptide, luteinizing hormone, and catecholamines and abnormally active eutopic receptors such as the vasopressin type 1a<sup>5</sup> and serotonin type 4 receptors.<sup>7-10</sup> The molecular defects that have been characterized in samples of hyperplastic adrenals also include activating mutations in the genes that encode the corticotropin receptor,<sup>11</sup> G-protein subunit  $\alpha_s$ ,<sup>12</sup> and phosphodiesterase 11A,<sup>13</sup> as well as the aberrant expression of bioactive signals in the adrenocortical cells, which leads to the formation of intra-adrenal regulatory loops.<sup>7</sup>

We previously described aberrant expression of corticotropin in a single case of corticotropin-independent macronodular adrenal hyperplasia,<sup>14</sup> which suggests that ectopic production of the peptide in the adrenal cortex may have induced adrenocortical hyperplasia and hypercortisolism. There were subsequent reports of two additional cases of macronodular adrenal hyperplasia associated with ectopic localization of corticotropin in adrenocortical cells.<sup>15,16</sup> The ectopic production of corticotropin by adrenocortical cells has also been observed in an adrenocortical-pituitary

hybrid tumor causing Cushing's syndrome.<sup>17</sup> In the present study, we examined corticotropin production in adrenal glands from a series of patients with macronodular adrenal hyperplasia and decreased levels of peripheral corticotropin.

## METHODS

### DIAGNOSIS OF CUSHING'S SYNDROME

We studied 30 patients with macronodular adrenal hyperplasia associated with subclinical or overt Cushing's syndrome (Table S1 in the Supplementary Appendix, available with the full text of this article at NEJM.org); 2 patients had familial disease (Patients 18 and 19), and 28 had sporadic disease. The diagnosis of primary adrenal Cushing's syndrome was based on standard biologic criteria, including an increase in 24-hour urinary cortisol excretion; abolition of the relationship between the circadian rhythm and levels of plasma cortisol; lack of cortisol suppression after the administration of dexamethasone (Table S2 in the Supplementary Appendix); and decreased basal levels of plasma corticotropin (<10 ng per liter [2.2 nmol per liter]). The diagnosis of subclinical Cushing's syndrome was established on the basis of an abnormal cortisol response to the administration of 1 mg of dexamethasone (cortisol level, >18  $\mu$ g per liter [50 nmol per liter]). We also searched for potentially aberrant membrane receptors, as previously reported.<sup>7</sup>

### SPECIMEN COLLECTION AND CORTICOTROPIN MEASUREMENT

Specimens of hyperplastic macronodular adrenal tissue were collected at surgery from 13 patients (prospective study, Patients 1 through 13) and were processed for subsequent *in vitro* experiments. For the remaining 17 patients (retrospective study, Patients 14 through 30), immunohistochemical or molecular studies were performed on fixed and frozen samples. Control specimens included fragments of seven normal adrenals obtained from patients undergoing expanded nephrectomy for kidney cancer and from four cortisol-producing adenomas. Plasma corticotropin levels were measured in samples of right and left adrenal and peripheral venous blood from Patients 12 and 13 (three samples were obtained from each site in each patient). The same procedure was followed for the 5 control patients with aldosterone-producing adenomas. We used a solid-phase, two-site sequential chemiluminescence

immunometric assay (Siemens Healthcare Diagnostics Products) with a lower limit of detection of 2 ng per liter (0.44 nmol per liter). The results are expressed as means  $\pm$ SE.

#### IN VITRO STUDIES

Synthesis and secretion of corticotropin in the hyperplastic adrenal glands were investigated with the use of reverse-transcriptase–polymerase-chain-reaction (RT-PCR) assays and immunohistochemical analyses and by means of cell-culture experiments and incubated adrenal explants. Genetic studies were performed to search for mutations of *PDE11A* (encoding phosphodiesterase 11A) and *GNAS* (encoding G-protein subunit  $\alpha_s$ ).<sup>12</sup> Details of the methods used for these studies are provided in the Material and Methods section and Tables S3 through S6 in the Supplementary Appendix.

#### STUDY OVERSIGHT

The protocols for the collection of adrenal samples and the experimental procedures were approved by the regional ethics committees. Written informed consent was obtained from all patients. The authors vouch for the accuracy and completeness of the data.

## RESULTS

#### PATIENTS

The 30 patients ranged in age from 34 to 76 years; 21 had overt Cushing's syndrome (Table 1). Clinical and biologic characteristics of the patients are summarized in Tables S1 and S2 in the Supplementary Appendix. No patient had a history of cancer.

#### CORTICOTROPIN EXPRESSION

Messenger RNA (mRNA) encoding the corticotropin precursor proopiomelanocortin was detected in all 26 hyperplastic adrenal samples tested by means of conventional and real-time RT-PCR. Values ranged from 4.2 to 62.6 pg of proopiomelanocortin mRNA per 1 ng of cyclophilin mRNA (median, 32.5) (Fig. 1A).

Immunohistochemical analysis of hyperplastic adrenal samples from 25 patients with anti-corticotropin antibodies revealed the presence of immunoreactive cells in the subcapsular region of the adrenals, the hyperplastic macronodules, or both (Fig. S1A in the Supplementary Appendix). Isolated corticotropin-positive cells were observed in only 4 of the 25 available samples (16%); in

the other 21 samples (84%), they were arranged in clusters. Corticotropin immunoreactivity was detected in the two subpopulations of cells in hyperplastic samples — spongiocytes, which were characterized by abundant cytoplasm and lipid droplets, and small compact cells (Fig. 1B). Semi-quantitative evaluation of immunolabeling of the spongiocytes and compact cells showed moderate immunostaining (in 9 samples [36%] and 8 samples [32%], respectively) or intense immunostaining (in 11 samples [44%] and 14 samples [56%], respectively). The immunostaining was focal for spongiocytes in 18 samples (72%) and for compact cells in 17 samples (68%) (Fig. S1B and S1C in the Supplementary Appendix). Corticotropin-immunopositive cells were also labeled by antibodies against prohormone convertase 1 (in all 14 available samples), a peptidase known to cleave the precursor protein proopiomelanocortin into active corticotropin, and by antibodies against the granule-specific protein secretogranin II (in all 10 available samples) (Fig. S2 in the Supplementary Appendix). No corticotropin immunostaining was detected in the cortex of six normal adrenal glands or in four cortisol-secreting adenomas (Fig. S3 in the Supplementary Appendix).

Adrenocortical cells that were immunopositive for corticotropin were negative for the chromaffin tissue marker chromogranin A (in all 6 samples studied) (Fig. 2A and 2B); CD45, which allows labeling of leukocytes (in all 4 samples studied) (Fig. 2C and 2D); and HLA-DR (in all 5 samples studied) (Fig. S4 and S5 in the Supplementary Appendix). Staining of sections of hyperplastic adrenal tissue with antibodies to T-box factor, pituitary (TPIT), a transcription factor specifically involved in the differentiation of the corticotroph pituitary lineage,<sup>20,21</sup> produced no signal in 5 of 7 samples examined (Fig. 2E and 2F). There was weak immunostaining in the cytoplasm of corticotropin-positive cells in 2 samples and in some cell cords of the normal adrenal cortex (Fig. S6 in the Supplementary Appendix). The expression levels of TPIT mRNA were similar in the samples of normal and macronodular hyperplastic adrenal tissue but appeared to be much lower than the expression levels in a sample from a corticotrophic adenoma of the pituitary. Corticotropin-positive cells were stained intensely by antibodies against markers of steroidogenic differentiation, including steroidogenic factor 1 (in all 5 available samples); scavenger receptor class B type I, the high-density lipoprotein receptor (in all 14 available samples);

**Table 1. Clinical Characteristics and Genetic and Molecular Evaluations in Patients with Adrenal Hyperplasia.\***

Patient No.	Sex	Age yr	Overt Cushing's Syndrome	<i>PDE11A</i> (germline)	<i>GNAS</i> (somatic)	<i>POMC</i> mRNA†
1‡	Female	34	Yes	Normal	Normal	Not quantified
2‡	Female	45	Yes	Not analyzed	Not analyzed	62.6
3‡	Female	54	Yes	Not analyzed	Not analyzed	5.4
4	Female	66	Yes	Not analyzed	Not analyzed	57.4
5‡	Female	45	No	Normal	Normal	48.2
6‡	Female	66	No	Y727C	Not analyzed	27.4
7‡	Male	64	Yes	Normal	Normal	40.3
8‡	Male	43	Yes	Not analyzed	Not analyzed	46.4
9‡	Male	46	Yes	Not analyzed	Not analyzed	8.5
10‡	Female	43	Yes	Normal	Normal	8.2
11‡	Female	71	No	Normal	Normal	Not analyzed
12	Female	69	No	Not analyzed	Not analyzed	12.3
13	Female	42	Yes	Not analyzed	Not analyzed	Not analyzed
14‡	Female	49	Yes	Normal	Normal	62.3
15‡	Female	41	Yes	R52T	Not analyzed	50.1
16	Female	60	Yes	Not analyzed	Not analyzed	4.2
17	Female	56	Yes	Not analyzed	Not analyzed	38.7
18‡	Female	58	Yes	Not analyzed	Not analyzed	27.3
19	Female	67	Yes	Not analyzed	Not analyzed	Not analyzed
20‡	Female	73	Yes	Not analyzed	Not analyzed	Not quantified
21‡	Male	74	Yes	Not analyzed	Not analyzed	9.5
22‡	Female	63	Yes	Not analyzed	Not analyzed	35.2
23‡	Female	50	No	Not analyzed	Not analyzed	54.0
24	Male	66	No	Not analyzed	Not analyzed	20.2
25	Female	53	Yes	Not analyzed	Not analyzed	43.2
26‡	Male	59	No	Normal	Normal	33.1
27	Female	37	No	Not analyzed	Not analyzed	Not quantified
28‡	Female	41	Yes	Normal	Normal	Not quantified
29‡	Female	30	Yes	Normal	Not analyzed	31.0
30	Male	76	No	Not analyzed	Not analyzed	Not analyzed

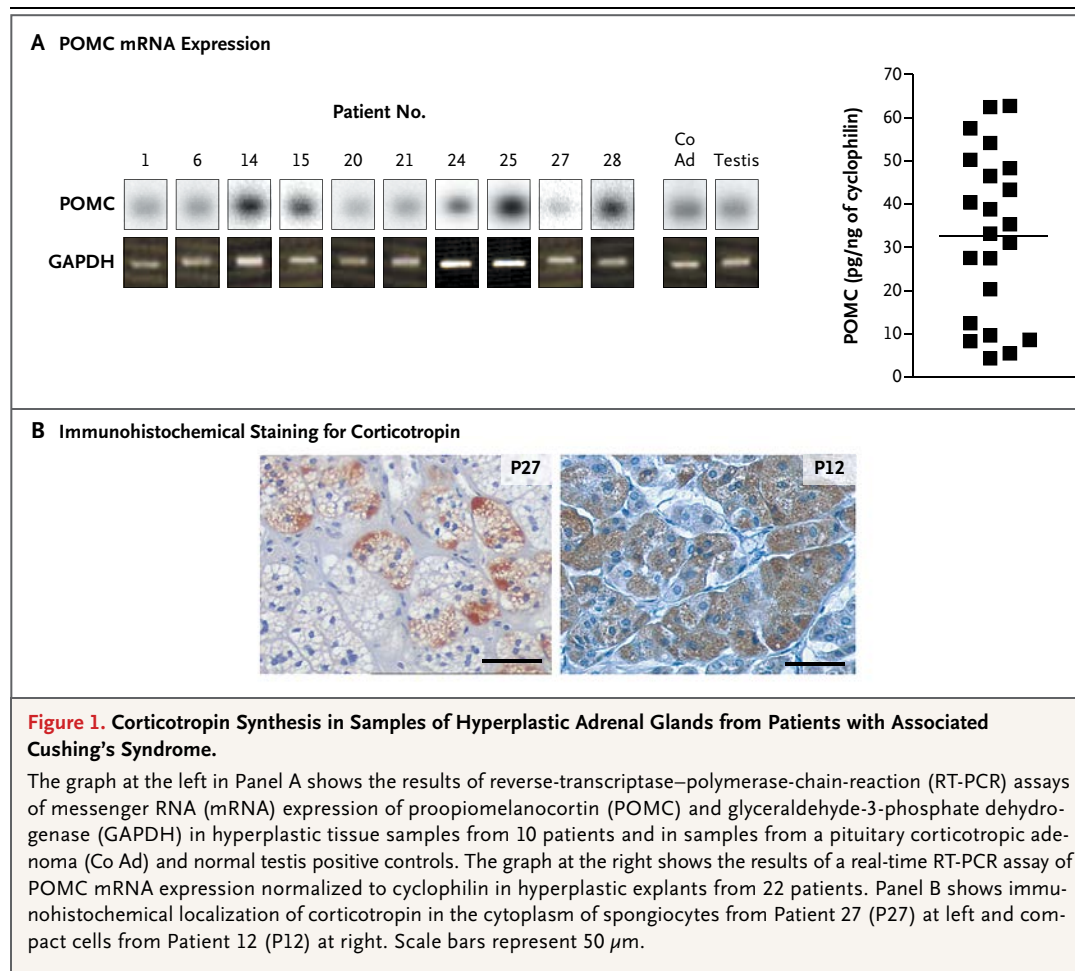
\* *PDE11A* denotes the gene encoding phosphodiesterase 11A, and *GNAS* the gene encoding the G-protein subunit  $\alpha_s$  (*GS $\alpha$* ).

† Messenger RNA (mRNA) expression levels for *POMC*, the gene encoding proopiomelanocortin, which were measured with the use of real-time reverse-transcriptase–polymerase-chain-reaction assays, have been expressed as picograms per nanogram of cyclophilin.

‡ Data have previously been reported for 20 of the patients, as follows: Patient 1<sup>7-9,18</sup>; Patients 2 and 3<sup>7,8</sup>; Patients 5, 6, and 7<sup>8</sup>; Patient 8<sup>10</sup>; Patient 9<sup>9,14</sup>; Patient 10<sup>13</sup>; Patient 11<sup>8</sup>; Patient 14<sup>7,18</sup>; Patient 15<sup>13</sup>; Patient 18<sup>9</sup>; Patients 20 through 23<sup>9</sup>; Patients 26 and 28<sup>18</sup>; and Patient 29.<sup>13</sup>

and the key steroidogenic enzyme 17 $\alpha$ -hydroxylase (in all 14 available samples) (Fig. 2G through 2L). Corticotropin-synthesizing cells were also immunopositive for the Leydig cell marker insulin-like

3 (in all 8 available samples) (Fig. S7 in the Supplementary Appendix). Conversely, insulin-like 3 immunoreactivity was not detected in samples of normal adrenal cortex tissue.

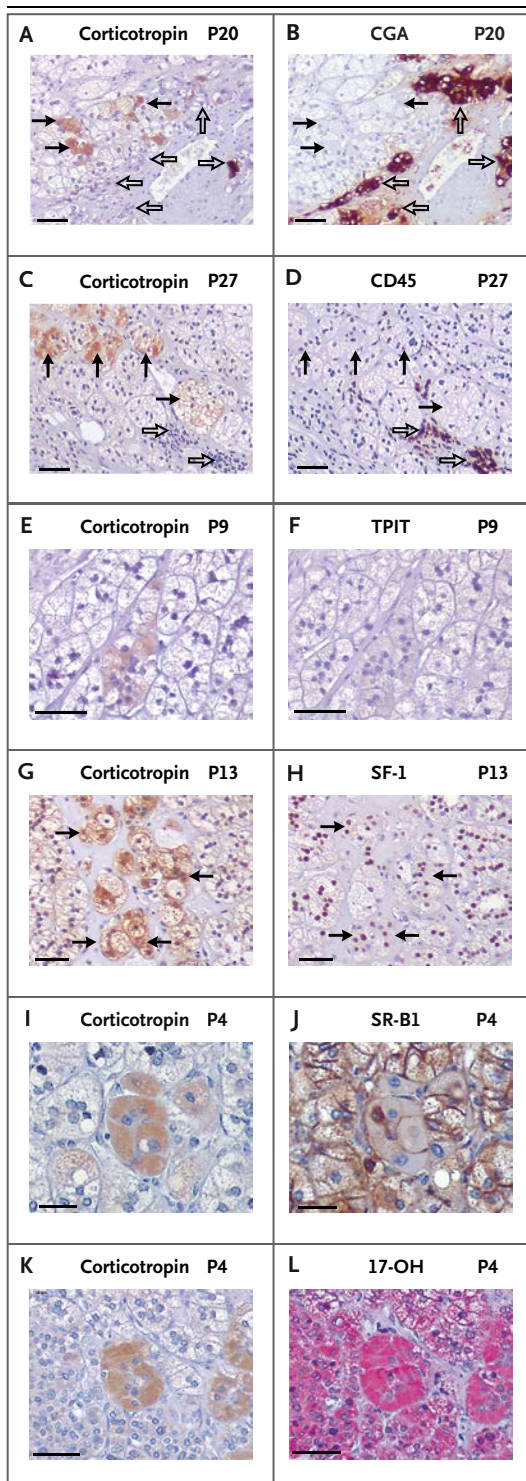


**CORTICOTROPIN SECRETION**

In two patients with adrenocortical hyperplasia (Patients 12 and 13), plasma corticotropin levels in the right and left adrenal veins were higher than those in the peripheral veins ( $26.6 \pm 5.5$  and  $15.0 \pm 2.0$  pg per milliliter [ $5.9 \pm 1.2$  and  $3.3 \pm 0.4$  pmol per liter], respectively, vs.  $2.0 \pm 0.5$  pg per milliliter [ $0.4 \pm 0.1$  pmol per liter] in Patient 12, and  $54.0 \pm 3.6$  and  $36.0 \pm 3.0$  pg per milliliter [ $11.9 \pm 0.8$  and  $7.9 \pm 0.7$  pmol per liter], respectively, vs.  $4.6 \pm 1.2$  pg per milliliter [ $1.0 \pm 0.3$  pmol per liter] in Patient 13). However, in patients with an aldosterone-producing adenoma, plasma corticotropin levels were similar in the adrenal and peripheral veins (Fig. 3A).

In vitro incubation studies revealed that all adrenocortical hyperplasia explants spontaneously released corticotropin in a pulsatile fashion, with a frequency of  $3.85 \pm 0.23$  pulses per hour (Fig. 3B). Cortisol production was significantly correlated with corticotropin release in 7 of

11 explants (64%). Conditioned medium removed after the incubation of explants from Patients 4, 5, 7, 10, and 11 stimulated corticosterone secretion in samples of cultured adrenocortical cells from rats. After subtraction of the concentrations of corticosterone in the added medium, the net steroidogenic responses of the cells were positively correlated with the measured corticotropin levels produced by the explants (Fig. S8A in the Supplementary Appendix). Corticostatin, a corticotropin-receptor antagonist, inhibited the stimulatory action of conditioned medium on the cultured rat cells (Fig. S8B in the Supplementary Appendix). Both spontaneous cortisol secretion and corticotropin-induced cortisol secretion by hyperplastic explants were reduced by the two melanocortin 2 receptor (MC2R) antagonists corticostatin and corticotropin(7–38), the corticotropin fragment corresponding to amino acids 7 to 38 of the peptide (Fig. 3C and 4B, and Table S7



**Figure 2. Immunohistologic Characterization of Corticotropin-Producing Cells in Hyperplastic Adrenal Samples from Patients with Associated Cushing's Syndrome.**

Immunohistochemical labeling of consecutive sections of hyperplastic tissue reveals antibodies against corticotropin (Panels A, C, E, G, I, and K), chromogranin A (CGA) (Panel B), CD45 (Panel D), and T-box factor, pituitary (TPIT) (Panel F), as well as antibodies against markers of steroidogenic differentiation, including steroidogenic factor 1 (SF-1) (Panel H), scavenger-receptor class B type 1 (SR-B1) (Panel J), and 17 $\alpha$ -hydroxylase (17-OH) (Panel L). Black arrows denote cells that are positive for corticotropin, and open arrows cells that are positive for CGA (Panel B) or CD45 (Panel D). Immunostaining was revealed with the use of diaminobenzidine (brown) or permanent red (pink). Patient numbers are indicated as P1, P2, and so on. Scale bars represent 50  $\mu$ m.

mRNA and steroidogenic enzyme mRNA expression levels are shown in the Results section and in Fig. S9 and S10, respectively, in the Supplementary Appendix.)

When hyperplastic explants from patients with abnormal plasma cortisol responses to glucose-dependent insulinotropic peptide, serotonin, and human chorionic gonadotropin were incubated with these same compounds, corticotropin secretion increased. Similarly, these compounds provoked a marked and prolonged increase in cortisol release (Fig. 4A, and Table S7 and Fig. S11 in the Supplementary Appendix). The effect of glucose-dependent insulinotropic peptide on cortisol secretion was significantly reduced in the presence of the MC2R antagonist corticotropin(7–38) (Fig. 4B). Corticotropin-releasing hormone ( $10^{-7}$  M), dexamethasone ( $10^{-6}$  M), and the glucocorticoid receptor antagonist mifepristone ( $10^{-6}$  M) had no significant effect on the secretion of corticotropin by hyperplastic explants (data not shown).

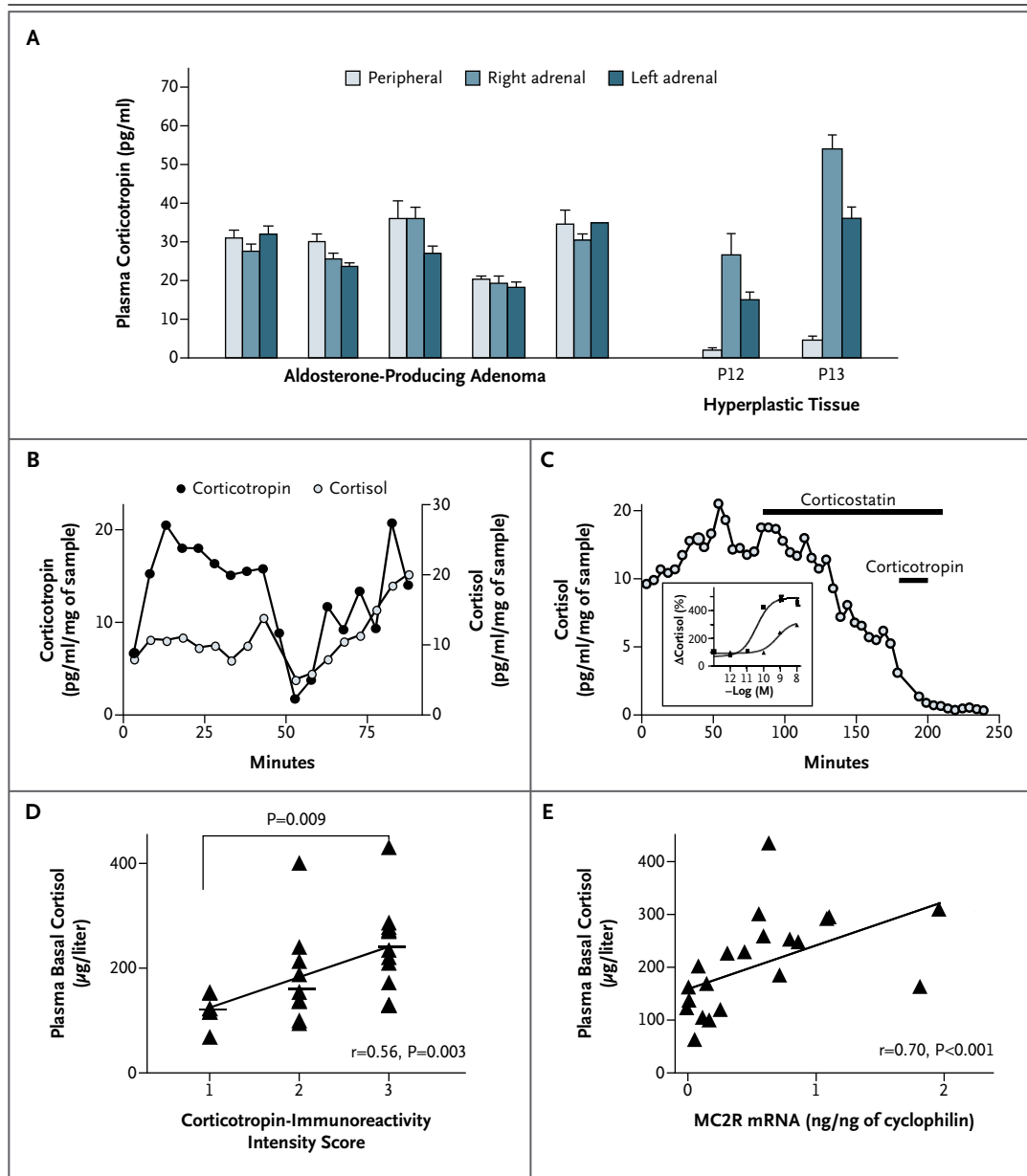
#### GENETIC STUDIES

We searched for somatic mutations of *GNAS*. No mutations were found (Table 1).

#### DISCUSSION

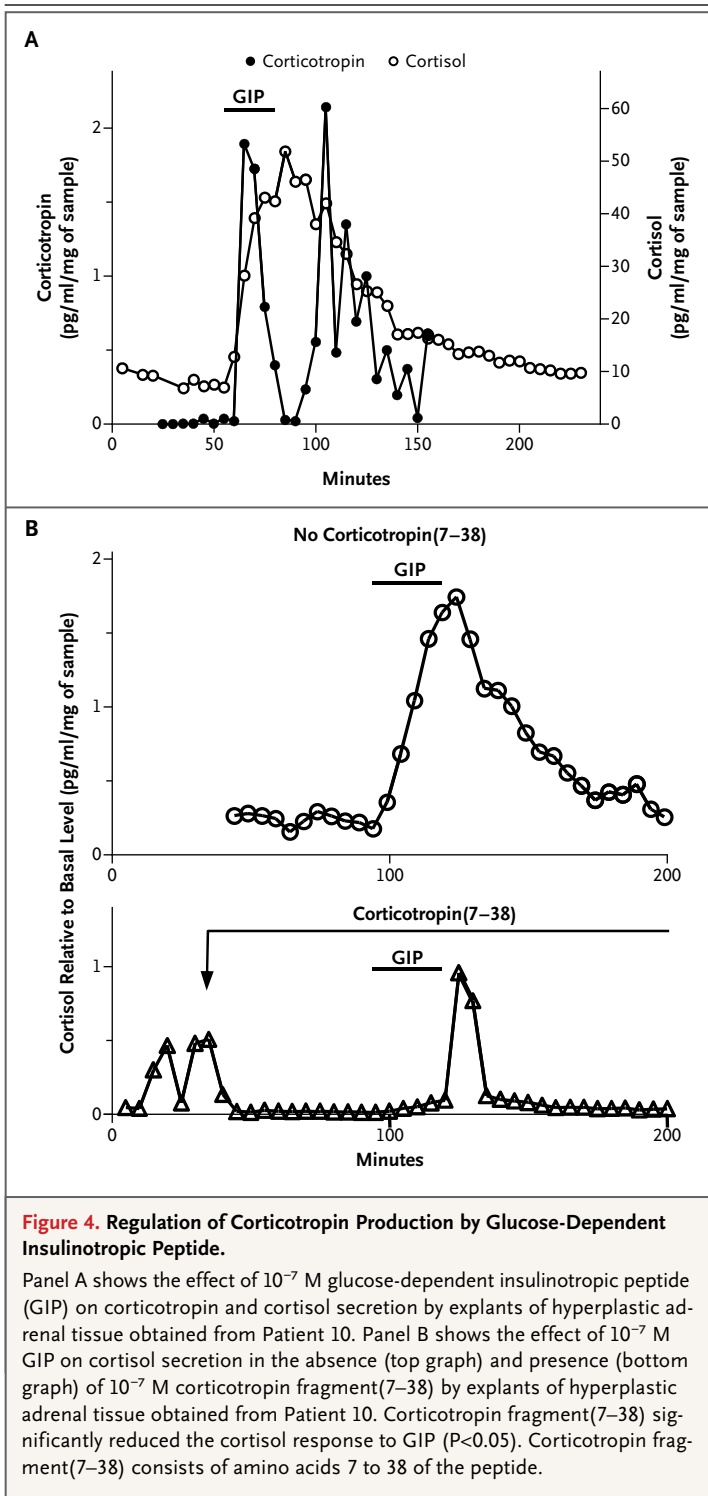
We sought to detect abnormal expression of corticotropin in a series of patients with Cushing's syndrome and what has been called "corticotropin-independent" bilateral macronodular adrenal hyperplasia. The mRNA encoding the corticotropin precursor proopiomelanocortin was detected in all hyperplastic adrenal samples studied. In addition,

in the Supplementary Appendix). In addition, basal cortisol levels correlated positively with both the histologic corticotropin intensity scores (Fig. 3D) and MC2R mRNA expression levels (Fig. 3E) in the hyperplastic samples studied. (MC2R



**Figure 3. Corticotropin Secretion by Hyperplastic Adrenals in Patients with Associated Cushing's Syndrome.**

In Panel A, plasma corticotropin levels are shown in blood samples from the peripheral and right and left adrenal veins in five controls with aldosterone-producing adenomas and in two patients with adrenal hyperplasia (Patients 12 and 13 [P12 and P13]). Each data point represents the mean ( $\pm$ SE) value for measurements in three successive blood samples taken from each vein. In Panel B, the kinetics of corticotropin and cortisol secretion by explants of hyperplastic adrenal tissue from Patient 3 are shown. Corticotropin secretion was correlated with cortisol production (3.84 pulses per hour,  $r=0.50$ ,  $P=0.04$ ). In Panel C, the action of the melanocortin 2–receptor (MC2R) antagonist corticostatin ( $2 \times 10^{-7}$  M) is shown as it affects spontaneous cortisol secretion and secretion induced by corticotropin ( $10^{-10}$  M) in explants of hyperplastic adrenal tissue obtained from Patient 4. The inset shows the effect of increasing doses of corticotropin (from  $10^{-12}$  to  $10^{-8}$  M) on cortisol production in a culture of adrenocortical cells from Patient 4 in the absence (squares) or presence (triangles) of corticostatin ( $2 \times 10^{-7}$  M). In Panels D and E, basal (8 a.m.) plasma cortisol levels are shown to be positively correlated with intensity scores for corticotropin immunoreactivity (Panel D) and MC2R mRNA expression (Panel E) in the 22 patients studied. Each data point represents a measurement in one patient.



hyperplastic specimens expressed prohormone convertase type 1, which suggests that adrenals affected by macronodular adrenal hyperplasia may generate bioactive corticotropin after pro-

cessing its precursor. Immunohistochemical studies confirmed the presence of corticotropin in adrenocortical cells that were distributed heterogeneously throughout the specimens, a finding that is consistent with the marked variability in levels of proopiomelanocortin mRNA expression.

Several cell types (e.g., chromaffin cells, lymphocytes, and pituitary corticotrophs) have been reported to produce corticotropin.<sup>22,23</sup> We examined the phenotype of corticotropin-positive cells by means of immunohistochemical analysis, using antibodies against markers for these various cell types. We observed that corticotropin expression in the hyperplastic adrenal samples did not result from adrenal chromaffin-like, lymphocyte-like, or pituitary corticotroph-like cell differentiation. The corticotropin-containing cells exhibited the morphologic characteristics of steroidogenic cells and were also consistently labeled by antibodies to steroidogenic factor 1, a transcription factor that triggers steroidogenic differentiation<sup>24</sup>; the receptor for the high-density lipoprotein scavenger receptor class B type 1, which plays an important role in maintaining the supply of cholesterol for adrenal steroidogenesis<sup>25</sup>; and  $17\alpha$ -hydroxylase, a key enzyme in the synthesis of cortisol and androgens.

Major-histocompatibility-complex class II antigens, which are normally expressed in the inner layer of the adrenal cortex,<sup>26</sup> were not expressed by the corticotropin-positive cells. Conversely, the expression of insulin-like 3,<sup>27</sup> a marker of Leydig and luteal cells, by corticotropin-positive cells, together with the well-demonstrated occurrence of corticotropin in steroid-producing gonadal cells,<sup>28,29</sup> suggests that abnormal synthesis of corticotropin may be a trait of gonadal-like differentiation. Because adrenocortical and gonadal stem cells both derive from the mesonephros, we speculate that the presence of gonadal-like cells in the adrenal glands may result from the abnormal differentiation of certain steroidogenic-cell progenitors or from the defective migration of some gonadal stem cells during embryogenesis. This pathologic process may represent the counterpart of the presence of adrenal rests in the gonads, a phenomenon that has been well documented in the testis.<sup>30</sup>

The molecular defect that causes macronodular adrenal hyperplasia may be complex, and the disease is a heterogeneous disorder that can be associated with various genetic defects at germline or somatic levels.<sup>12,13,31</sup> In the present study,

two patients had previously been shown to carry germline mutations in *PDE11A*, a gene associated with macronodular adrenal hyperplasia.<sup>13,18</sup> Since all the hyperplastic adrenal specimens examined contained corticotropin-positive cells, we speculate that the abnormal expression of corticotropin by some adrenocortical cells may represent a secondary pathophysiological process that is common to diverse molecular defects and is seen in both sporadic and familial cases.

The presence of corticotropin in cytoplasmic granules and its association with secretogranin II immunoreactivity suggest that corticotropin may be released within the adrenal cortex through exocytosis. Our *in vitro* results show that corticotropin can be secreted by hyperplastic explants. The release of corticotropin by the adrenal glands was also observed *in vivo* in two patients, both of whom had higher plasma levels of corticotropin in the adrenal veins than in the peripheral veins. Thus, it is conceivable that in some patients with macronodular hyperplasia and markedly elevated cortisol levels,<sup>32</sup> detectable plasma corticotropin levels are due to ectopic production of the peptide by the hyperplastic glands. A case report by Hiroi et al.<sup>17</sup> about a patient with an adrenocortical-pituitary hybrid adenoma and paradoxically normal plasma corticotropin levels supports this idea. In that patient, adrenal corticotropin production was detected on adrenal-vein catheterization, and surgical removal of the neoplasm suppressed corticotropin levels.

Our results also suggest that in patients with macronodular adrenal hyperplasia, overt hypercortisolism, and unsuppressed plasma corticotropin levels, corticotropin secretion by the adrenal glands should be considered and explored by sampling the adrenal veins rather than by catheterizing the inferior petrosal sinus.<sup>17</sup> Our observation that adrenocortical explants released corticotropin, together with cortisol, in a pulsatile fashion is consistent with a study showing that cortisol production is pulsatile in patients with Cushing's syndrome due to bilateral macronodular adrenal hyperplasia<sup>33</sup> and with previous observations showing a relationship between intraadrenal oscillators and the expression of "clock genes."<sup>34</sup>

Our observation that cortisol levels correlated positively with corticotropin levels in conditioned medium from adrenal explants raises the possibility that corticotropin, when produced by some steroidogenic cells, may stimulate cortisol secre-

tion through a paracrine mechanism. This hypothesis is supported by our *in vitro* findings: conditioned medium from hyperplastic adrenal explants stimulated the production of corticosterone in cultured rat adrenocortical cells, an effect that was inhibited by an MC2R-receptor antagonist, indicating that intraadrenal corticotropin is actually bioactive; corticotropin-receptor antagonists reduced the production of cortisol in hyperplastic explants. In addition, basal plasma cortisol levels correlated positively with both the histologic corticotropin scores and MC2R expression levels in hyperplastic adrenal samples. These results suggest that in macronodular adrenal hyperplasia, intraadrenal corticotropin plays an important role in the regulation of cortisol secretion. We speculate that the recently developed corticotropin-receptor antagonists might provide an alternative treatment for hypercortisolism associated with adrenal macronodular hyperplasia. Ectopic synthesis of corticotropin by adrenocortical cells may also be involved in the development of hyperplasia through the angiogenic and anti-apoptotic actions of the peptide on the adrenocortical tissue.<sup>35</sup>

When we examined the effect of classic regulators of pituitary corticotropin secretion on the release of corticotropin by hyperplastic explants, we found that corticotropin-releasing hormone had no substantial action. Similarly, dexamethasone and the glucocorticoid-receptor antagonist mifepristone did not affect the release of corticotropin, indicating that cortisol is not involved in a feedback mechanism that inhibits the production of corticotropin in adrenal hyperplastic tissues. Conversely, we observed that corticotropin production was stimulated by regulatory factors that activate aberrant membrane receptors expressed by hyperplastic tissues (i.e., glucose-dependent insulinotropic peptide, serotonin, and human chorionic gonadotropin) (see the Discussion section in the Supplementary Appendix).

In conclusion, the present study shows that in patients with bilateral macronodular adrenal hyperplasia and Cushing's syndrome, cortisol production is controlled both by aberrant membrane receptors and by corticotropin that is produced within the adrenocortical tissue, which appears to act as a local amplifier of the action of these receptors. From a pathophysiological point of view, the term "corticotropin-independent," which has been used to designate cases of bilateral ad-

renal macronodular hyperplasia with hypercortisolism and low plasma corticotropin levels, appears to be inappropriate. The disease instead seems to be a cause of primary adrenal Cushing's syndrome in association with the ectopic expression of corticotropin within the adrenal cortex. Thus, the term "bilateral macronodular adrenal hyperplasia" would seem to be a better and more accurate description of the disease.<sup>36</sup>

Supported by grants from INSERM Unité 982, Agence Nationale de la Recherche (Programme blanc 2010, GePAH project), Centre Hospitalier Universitaire de Rouen, Réseau COMETE, Assistance Publique-Hôpitaux de Paris, and Conseil Régional de Haute-Normandie.

Disclosure forms provided by the authors are available with the full text of this article at NEJM.org.

We thank Drs. Françoise Gobet, Gaëlle Barrande, Yves Reznik, Frederique Tissier, and Patricia Vergani for their collaboration; Dr. Jacques Drouin for his gift of anti-TPIT antibodies; and Huguette Lemonnier, Arnaud Arabo, and Fernande René-Corail for their technical assistance.

## REFERENCES

- Newell-Price J, Bertagna X, Grossman AB, Nieman LK. Cushing's syndrome. *Lancet* 2006;367:1605-17.
- Lacroix A, Tremblay J, Rousseau G, Bouvier M, Hamet P. Propranolol therapy for ectopic beta-adrenergic receptors in adrenal Cushing's syndrome. *N Engl J Med* 1997;337:1429-34.
- Reznik Y, Allali-Zerah V, Chayvialle JA, et al. Food-dependent Cushing's syndrome mediated by aberrant adrenal sensitivity to gastric inhibitory polypeptide. *N Engl J Med* 1992;327:981-6.
- Lacroix A, Bolté E, Tremblay J, et al. Gastric inhibitory polypeptide-dependent cortisol hypersecretion — a new cause of Cushing's syndrome. *N Engl J Med* 1992;327:974-80.
- Mune T, Murase H, Yamakita N, et al. Ectopic overexpression of vasopressin v1a receptor in adrenocorticotropin-independent macronodular adrenal hyperplasia. *J Clin Endocrinol Metab* 2002;87:5706-13.
- De Groot JWB, Links TP, Themmen APN, et al. Aberrant expression of multiple hormone receptors in ACTH-independent macronodular adrenal hyperplasia causing Cushing's syndrome. *Eur J Endocrinol* 2010;163:293-9.
- Bertherat J, Contesse V, Louiset E, et al. In vivo and in vitro screening for illegitimate receptors in adrenocorticotropin-independent macronodular adrenal hyperplasia causing Cushing's syndrome: identification of two cases of gonadotropin/gastric inhibitory polypeptide-dependent hypercortisolism. *J Clin Endocrinol Metab* 2005;90:1302-10.
- Louiset E, Contesse V, Groussin L, et al. Expression of serotonin7 receptor and coupling of ectopic receptors to protein kinase A and ionic currents in adrenocorticotropin-independent macronodular adrenal hyperplasia causing Cushing's syndrome. *J Clin Endocrinol Metab* 2006;91:4578-86.
- Cartier D, Lihmann I, Parmentier F, et al. Overexpression of serotonin4 receptors in cisapride-responsive adrenocorticotropin-independent bilateral macronodular adrenal hyperplasia causing Cushing's syndrome. *J Clin Endocrinol Metab* 2003;88:248-54.
- Assie G, Louiset E, Sturm N, et al. Systematic analysis of G protein-coupled receptor gene expression in adrenocorticotropin-independent macronodular adrenocortical hyperplasia identifies novel targets for pharmacological control of adrenal Cushing's syndrome. *J Clin Endocrinol Metab* 2010;95:E253-E262.
- Swords FM, Baig A, Malchoff DM, et al. Impaired desensitization of a mutant adrenocorticotropin receptor associated with apparent constitutive activity. *Mol Endocrinol* 2002;16:2746-53.
- Fragoso MC, Domenice S, Latronico AC, et al. Cushing's syndrome secondary to adrenocorticotropin-independent macronodular adrenocortical hyperplasia due to activating mutations of GNAS1 gene. *J Clin Endocrinol Metab* 2003;88:2147-51.
- Vezzosi D, Libé R, Baudry C, et al. Phosphodiesterase 11A (PDE11A) gene defects in patients with ACTH-independent macronodular adrenal hyperplasia (AIMAH): functional variants may contribute to genetic susceptibility of bilateral adrenal tumors. *J Clin Endocrinol Metab* 2012;97:E2063-E2069.
- Lefebvre H, Duparc C, Chartrel N, et al. Intraadrenal adrenocorticotropin production in a case of bilateral macronodular adrenal hyperplasia causing Cushing's syndrome. *J Clin Endocrinol Metab* 2003;88:3035-42.
- Mazzucco TL, Thomas M, Martinie M, et al. Cellular and molecular abnormalities of a macronodular adrenal hyperplasia causing beta-blocker-sensitive Cushing's syndrome. *Arg Bras Endocrinol Metabol* 2007;51:1452-62.
- Iwata M, Oki Y, Okazawa T, et al. A rare case of adrenocorticotropin hormone (ACTH)-independent macroadrenal hyperplasia showing ectopic production of ACTH. *Intern Med* 2012;51:2181-7.
- Hiroi N, Chrousos GP, Kohn B, et al. Adrenocortical-pituitary hybrid tumor causing Cushing's syndrome. *J Clin Endocrinol Metab* 2001;86:2631-7.
- Libé R, Fratticci A, Coste J, et al. Phosphodiesterase 11A (PDE11A) and genetic predisposition to adrenocortical tumors. *Clin Cancer Res* 2008;14:4016-24.
- Vezzosi D, Cartier D, Régnier C, et al. Familial adrenocorticotropin-independent macronodular adrenal hyperplasia with aberrant serotonin and vasopressin adrenal receptors. *Eur J Endocrinol* 2007;156:21-31.
- Lamolet B, Pulichino AM, Lamonerie T, et al. A pituitary cell-restricted T box factor, Tpit, activates POMC transcription in cooperation with Pitx homeoproteins. *Cell* 2001;104:849-59.
- Vallette-Kasic S, Figarella-Branger D, Grino M, et al. Differential regulation of proopiomelanocortin and pituitary-restricted transcription factor (TPIT), a new marker of normal and adenomatous human corticotrophs. *J Clin Endocrinol Metab* 2003;88:3050-6.
- Suda T, Tomori N, Tozawa F, et al. Immunoreactive corticotropin and corticotropin-releasing factor in human hypothalamus, adrenal, lung cancer, and pheochromocytoma. *J Clin Endocrinol Metab* 1984;58:919-24.
- Meyer WJ III, Smith EM, Richards GE, Cavallo A, Morrill AC, Blalock JE. In vivo immunoreactive adrenocorticotropin (ACTH) production by human mononuclear leukocytes from normal and ACTH-deficient individuals. *J Clin Endocrinol Metab* 1987;64:98-105.
- Parker KL, Schimmer BP. Steroidogenic factor 1: a key determinant of endocrine development and function. *Endocr Rev* 1997;18:361-77.
- Connelly MA. SR-BI-mediated HDL cholesteryl ester delivery in the adrenal gland. *Mol Cell Endocrinol* 2009;300:83-8.
- Marx C, Bornstein SR, Wolkersdorfer GW, Peter M, Sippell WG, Scherbaum WA. Relevance of major histocompatibility complex class II expression as a hallmark for the cellular differentiation in the human adrenal cortex. *J Clin Endocrinol Metab* 1997;82:3136-40.
- Ivell R, Balvers M, Domagalski R, Ungefroren H, Hunt N, Schulze W. Relaxin-like factor: a highly specific and constitutive new marker for Leydig cells in the human testis. *Mol Hum Reprod* 1997;3:459-66.
- de Keyzer Y, Lenne F, Massias JF, et al. Pituitary-like proopiomelanocortin transcripts in human Leydig cell tumors. *J Clin Invest* 1990;86:871-7.
- Lacaze-Masmonteil T, de Keyzer Y,

- Luton JP, Kahn A, Bertagna X. Characterization of proopiomelanocortin transcripts in human nonpituitary tissues. *Proc Natl Acad Sci U S A* 1987;84:7261-5.
30. Claahsen-van der Grinten HL, Hermus ARMM, Otten BJ. Testicular adrenal rest tumours in congenital adrenal hyperplasia. *Int J Pediatr Endocrinol* 2009;23:209-20.
31. Hsiao H-P, Kirschner LS, Bourdeau I, et al. Clinical and genetic heterogeneity, overlap with other tumor syndromes, and atypical glucocorticoid hormone secretion in adrenocorticotropin-independent macronodular adrenal hyperplasia compared with other adrenocortical tumors. *J Clin Endocrinol Metab* 2009;94:2930-7.
32. Swain JM, Grant CS, Schlinkert RT, et al. Corticotropin-independent macronodular adrenal hyperplasia: a clinicopathologic correlation. *Arch Surg* 1998;133:541-5.
33. van Aken MO, Pereira AM, Van Thiel SW, et al. Irregular and frequent cortisol secretory episodes with preserved diurnal rhythmicity in primary adrenal Cushing's syndrome. *J Clin Endocrinol Metab* 2005;90:1570-7.
34. Kalsbeek A, van der Spek R, Lei J, Endert E, Buijs RM, Fliers E. Circadian rhythms in the hypothalamo-pituitary-adrenal (HPA) axis. *Mol Cell Endocrinol* 2012;349:20-9.
35. Thomas M, Keramidas M, Monchaux E, Feige J-J. Dual hormonal regulation of endocrine tissue mass and vasculature by adrenocorticotropin in the adrenal cortex. *Endocrinology* 2004;145:4320-9.
36. Stratakis CA, Boikos SA. Genetics of adrenal tumors associated with Cushing's syndrome: a new classification for bilateral adrenocortical hyperplasias. *Nat Clin Pract Endocrinol Metab* 2007;3:748-57.

Copyright © 2013 Massachusetts Medical Society.

**CLINICAL TRIAL REGISTRATION**

The *Journal* requires investigators to register their clinical trials in a public trials registry. The members of the International Committee of Medical Journal Editors (ICMJE) will consider most reports of clinical trials for publication only if the trials have been registered. Current information on requirements and appropriate registries is available at [www.icmje.org/faq\\_clinical.html](http://www.icmje.org/faq_clinical.html).