



HAL
open science

Steroidogenic enzyme profile in an androgen-secreting adrenocortical oncocytoma associated with hirsutism

Milène Tetsi Nomigni, Sophie Ouzounian, Alice Benoit, Jacqueline Vadrot, Frédérique Tissier, Sylvie Renouf, Hervé Lefebvre, Sophie Christin-Maitre, Estelle Louiset

► To cite this version:

Milène Tetsi Nomigni, Sophie Ouzounian, Alice Benoit, Jacqueline Vadrot, Frédérique Tissier, et al.. Steroidogenic enzyme profile in an androgen-secreting adrenocortical oncocytoma associated with hirsutism. *Endocrine Connections*, 2015, 4 (2), pp.117 - 127. <10.1530/EC-15-0014>. <hal-01901890>

HAL Id: hal-01901890

<https://normandie-univ.hal.science/hal-01901890v1>

Submitted on 23 Oct 2018

HAL is a multi-disciplinary open access archive for the deposit and dissemination of scientific research documents, whether they are published or not. The documents may come from teaching and research institutions in France or abroad, or from public or private research centers.

L'archive ouverte pluridisciplinaire **HAL**, est destinée au dépôt et à la diffusion de documents scientifiques de niveau recherche, publiés ou non, émanant des établissements d'enseignement et de recherche français ou étrangers, des laboratoires publics ou privés.



Distributed under a Creative Commons CC BY-NC 4.0 - Attribution - Non-commercial use - International License



Steroidogenic enzyme profile in an androgen-secreting adrenocortical oncocytoma associated with hirsutism

Milène Tetsi Nomigni^{1,2}, Sophie Ouzounian³, Alice Benoit⁴, Jacqueline Vadrot⁵, Frédérique Tissier⁶, Sylvie Renouf^{1,2}, Hervé Lefebvre^{1,2,7}, Sophie Christin-Maitre^{3,8} and Estelle Louiset^{1,2}

¹INSERM, U982, Laboratory of Neuronal and Neuroendocrine Differentiation and Communication, Institute for Research and Innovation in Biomedicine, Mont-Saint-Aignan, France

²University of Rouen, Mont-Saint-Aignan, France

³Department of Endocrinology, Hôpital Saint-Antoine, Assistance Publique-Hôpitaux de Paris, Paris, France, Departments of ⁴Endocrinology, Diabetes and Metabolic Diseases, and ⁵Pathology, Hôpital Sud Francilien, Corbeil-Essonnes, France

⁶Department of Pathology, Assistance Publique des Hôpitaux de Paris, Hôpital Pitié Salpêtrière, Pierre-et-Marie Curie University, Paris, France

⁷Department of Endocrinology, Diabetes and Metabolic Diseases, Rouen University Hospital, 76000 Rouen, France

⁸INSERM, U933, Paris, France

Correspondence should be addressed to H Lefebvre
Email
 herve.lefebvre@chu-rouen.fr

Abstract

Hirsutism induced by hyperandrogenism can be associated with polycystic ovary syndrome, 21-hydroxylase (OH) deficiency or androgen-secreting tumors, including ovarian and adrenal tumors. Adrenal androgen-secreting tumors are frequently malignant. Adrenal oncocytomas represent rare causes of hyperandrogenism. The aim of the study was to investigate steroidogenic enzyme expression and steroid secretion in an androgen-secreting adrenal oncocytoma in a young woman presenting with hirsutism. Hyperandrogenism was diagnosed on the basis of elevated plasma Δ 4-androstenedione and testosterone levels. Pelvic ultrasound was normal, CT scanning revealed a right adrenal mass. Androgens were assessed in adrenal and ovarian vein samples and proved a right adrenal origin. Adrenalectomy normalized androgen levels and the adrenal tumor was diagnosed as an oncocytoma. Real time-PCR, immunohistochemistry and cell culture studies were performed on tumor explants to investigate the steroid secretion profile. Among enzymes required for cortisol synthesis, 17α -OH and 3β -hydroxysteroid dehydrogenase 2 (3β -HSD2) were highly expressed whereas 21-OH and 11β -OH were weakly produced at the mRNA and/or protein levels. Enzymes involved in testosterone production, 17β -HSD5 and 17β -HSD3, were also detected. ACTH receptor was present in the tissue. Cortisol, Δ 4-androstenedione and testosterone secretions by cultured cells were increased by ACTH. These results provide the first demonstration, to our knowledge, of abnormal expression profile of steroidogenic enzymes in an adrenocortical oncocytoma. Our results also indicate that Δ 4-androstenedione hypersecretion resulted from high 17α -OH and 3β -HSD2 expression in combination with low expression of 21-OH and

Key Words

- ▶ hirsutism
- ▶ androgen-producing oncocytoma
- ▶ Δ 4-androstenedione
- ▶ testosterone
- ▶ cortisol



11 β -OH. Testosterone production was ascribed to occurrence of 17 β -HSD5 and 17 β -HSD3. Finally, our results indicate that androgen secretion was stimulated by ACTH.

Endocrine Connections
(2015) 4, 117–127

Introduction

Hirsutism is defined as excessive growth of terminal hair on the face and body of a female with a typical male-pattern distribution. Idiopathic hirsutism remains a diagnosis of exclusion, as hyperandrogenism needs to be eliminated. Polycystic ovary syndrome (PCOS) is the most common cause of hyperandrogenism (1, 2, 3). According to the Rotterdam criteria, diagnosis of PCOS is determined on the basis of chronic anovulation, polycystic ovaries, clinical and/or biochemical evidence of hyperandrogenism, after exclusion of other pathologies such as 21-hydroxylase (OH) deficiency, androgen-secreting tumors or Cushing's syndrome (4). Androgen-secreting tumors are typically ovarian or adrenal tumors. They represent less than 0.2% of hyperandrogenism (5, 6). They are commonly associated with high testosterone levels (7, 8). High plasma levels of testosterone associated with normal dehydroepiandrosterone sulfate (DHEAS) concentration are indicative of ovarian hyperthecosis or androgen-secreting ovarian tumors such as Leydig–Sertoli tumors (9, 10, 11). In contrast, high levels of DHEAS are indicative of adrenocortical adenoma of zona reticularis (ZR). In most cases, adrenal androgen-secreting tumors are malignant. In particular, concomitant androgen and cortisol oversecretion is highly suggestive of adrenocortical carcinoma (12). In very few cases, androgen-secreting adrenal lesions have been identified as bilateral macronodular hyperplasia (13, 14), adenoma (15), primary pigmented nodular adrenocortical disease (16), pheochromocytoma (17) and oncocytic neoplasms (18, 19, 20). In particular, rare cases of androgen-secreting oncocytic tumors have been described in female children (18, 19) and postmenopausal women (20), whereas in women of reproductive age, the great majority of adrenal oncocytomas are nonfunctional (21).

We report herein a very unusual case of hyperandrogenism, in a young woman presenting with an adrenocortical oncocytoma. We have investigated the expression pattern of steroidogenic enzymes and determined the steroid secretion profile using cultured oncocytic cells. We could demonstrate that the oncocytic cells co-secreted cortisol and androgens, harboring therefore an intermediate steroidogenic phenotype between those of zona fasciculata (ZF) and ZR cells.

Patient and methods

Patient

A 34-year-old patient, originating from Senegal, was admitted to our endocrine unit for hirsutism. Her only medical history was an atrophy of the right kidney, revealed incidentally on an abdominal ultrasound, with normal renal function. Her menarche occurred at the age of 13. She had regular menses up to the age of 31. Since then, she presented with spaniomenorrhoea as her cycles were every 40–50 days. Her hirsutism, which appeared 3 years before her visit, was mild, as her Ferriman and Gallway score reached 17. She was overweight (BMI 28 kg/m²). Her systolic and diastolic blood pressure levels were 110 and 80 mmHg, respectively. She had no clinical signs of hypercorticism. In the follow-up of her kidney atrophy, a computerized tomography (CT)-scan revealed the presence of a right adrenal lesion measuring 26 mm. Venous blood sampling from right and left adrenals, ovaries and periphery were performed. As a right adrenal origin was confirmed, a right adrenalectomy was performed.

Tissue collection

The adrenal gland was obtained at surgery and immediately dissected by the pathologist. Adrenal explants were frozen for RT-PCR analysis, fixed in formalin for histological study or immersed in culture medium until cell dissociation. Seven normal adrenals (control tissues) were obtained from patients undergoing expanded nephrectomy for kidney cancer. The protocol of collection of the tissues and the experimental procedures were approved by the regional ethics committees, and written informed consent was obtained from all subjects. Human adrenal and testis poly A⁺ RNA (Clontech, Ozyme, Montigny-le-Bretonneux, France) were also used as control tissues.

Real-time RT-PCR

Total RNAs were extracted from two samples of the adrenocortical tumor and seven normal adrenals by using Tri-Reagent (Sigma–Aldrich, Saint-Quentin-Fallavier,



France) and purified on Nucleospin RNAII (Macherey–Nagel, Hoerd, France). Purified RNA and polyA⁺ RNA were converted into cDNA by using ImProm-II RT System (Promega). Real-time PCR amplifications were performed using SYBR Green I Master Mix (Applied Biosystems) in an ABI-PRISM 7900 System (Applied Biosystems) with specific primers (Table 1). Quantification of cDNAs in each tissue-derived sample was normalized to *PPIA* (cyclophilin) cDNAs. Samples were analyzed in duplicates in three different experiments.

Immunohistochemistry

Immunohistochemical studies were performed on formalin-fixed and deparaffinized tissue sections from two different fragments of the oncocytoma (ten sections per tissue sample) and seven normal adrenals. Sections were heated at 95 °C in 10 mM citrate buffer (pH=6; 20 min) for antigen retrieval. They were then treated with peroxidase and alkaline phosphatase blocking reagent (Dako Corporation, Les Ulis, France). Sections were incubated for 30 min with primary antibodies against 17 α -OH (1:2000; provided by Drs V Luu The and G Pelletier, Laval University Medical Center, Quebec, Canada), hydroxy-delta-5-steroid dehydrogenase/3 beta/steroid delta-isomerase 2 (3 β -HSD2; 1:100; Proteintech, Euromedex, Souffelweyersheim, France), 21-OH (1:250; Sc-48466; Santa Cruz Biotechnology), 17 β -hydroxysteroid dehydrogenase 5 (17 β -HSD5; 1:100; Sigma–Aldrich), 17 β -HSD3 (1:300; Sc-66415; Santa Cruz Biotechnology), melanocortin 2 receptor (MC2R; 1:50; Clone RB22805, Abgent,

Maidenhead, UK) or luteinizing hormone receptor (C-term) (1:200; Acris, Interchim, Montluçon, France). The sections were then incubated with anti-rabbit, anti-mouse or anti-donkey immunoglobulin streptavidin–biotin complex coupled to peroxidase (Dako Corporation) or alkaline phosphatase (Beckman Coulter, Roissy, France). Immunoreactivities were revealed with diaminobenzidine (Dako Corporation) or NovaRED (Vector Laboratories, Clinisciences, Nanterre, France). The tissue sections were counterstained with hematoxylin. Semiquantitative evaluation of immunoreactions was performed using a histological score which integrates both the percentage of positive cells (graded as 0: no staining, 1: <10%, 2: 11–50%, 3: 51–80% and 4: >80% of the cells) and staining intensity (graded as 0: no staining, 1: weak, 2: moderate and 3: strong staining).

Cell culture

Adrenocortical adenoma explants were immersed in DMEM supplemented with 1% antibiotic–antimycotic solution (Fisher Scientific, Illkirch-Graffenstaden, France) until cell dispersion. Tissue samples were stirred for 45 min at 37 °C in culture medium containing collagenase type 1A (60 mg/ml; Sigma–Aldrich) and desoxyribonuclease 1 type 4 (4 mg/ml; Sigma–Aldrich) in a 5% CO₂–95% air atmosphere. Dispersed adrenocortical cells were cultured at a density of 10⁶ cells/ml at 37 °C in a 5% CO₂–95% air atmosphere with 100% relative humidity in culture medium (50% DMEM, 50% Ham–F12; Life Technologies, Inc.) supplemented with 1% insulin–transferrin–selenium

Table 1 Primer sequences and GenBank accession numbers for real-time RT-PCR.

Gene name	Accession number	Sequence primer	Product size (bp)
<i>PPIA</i> ^a	NM_021130.3	F: 5'-ATGGCACTGGTGGCAAGTCC-3' R: 5'-TTGCCATTCTGGACCCAAA-3'	241
<i>CYP17A1</i>	NM_000102.3	F: 5'-AGCCGCACCAACTATCAGTGAC-3' R: 5'-TCACCGATGCTGGAGTCAACGTTG-3'	134
<i>CYP21A2</i>	NM_000500.7	F: 5'-GAGTTCTGTGAGCGCA-3' R: 5'-CACGTCCACAATTTGGAT-3'	201
<i>CYP11B1</i>	NM_000497.3	F: 5'-AGGAGACCTTGCGGCTCTACC-3' R: 5'-GAACACGCGCACCAATGTC-3'	110
<i>CYB5A</i>	NM_148923.3	F: 5'-CTGGAAGAGCATCCTGGTGG-3' R: 5'-CCGGAGGCTTGTTAACTTTGG-3'	169
<i>AKR1C3</i>	NM_003739.5	F: 5'-TCCGACCAGCCTTGAAAACCTCA-3' R: 5'-CCCAGGTGGTACAGAGATCCACTATGTC-3'	162
<i>HSD17B3</i>	NM_000197.1	F: 5'-TGGGACAGTGGGCAGTGA-3' R: 5'-CGAGTACGCTTTCCCAATCC-3'	56
<i>HSD3B2</i>	NM_000198.3	F: 5'-TTGGACAAGGCCTTCAGAC-3' R: 5'-ACAGGCGGTGTGGATGAC-3'	150

F, forward; R, reverse.

^aReference gene.

solution (Gibco) and 5% FCS (Bio-Whittaker, Walkersville, MD, USA). Incubation experiments were conducted in quadruplicate for 24 h after 2 days in culture with fresh DMEM (control experiments) or DMEM with different concentrations of human chorionic gonadotrophin (hCG, Organon, Eragny-sur-Epte, France) or adrenocorticotrophic hormone (ACTH(1–24)) (Sigma–Aldrich). Cells were incubated with each secretagogue for 24 h at 37 °C. Cortisol, Δ 4-androstenedione and testosterone secretions were quantified by RIA procedure using specific antibodies (Sigma–Aldrich) and tritiated steroid hormones (Perkin Elmer, Villebon-sur-Yvette, France) according to the manufacturer's instructions. Cross-reactivity of cortisol antibodies for Δ 4-androstenedione and testosterone was 0.5 and 5%, respectively. Cross-reactivity of Δ 4-androstenedione antibodies for testosterone was 4.5%. Cross-reactivity of testosterone antibodies for Δ 4-androstenedione and cortisol was 1.7 and <0.1%, respectively. RIA sensitivities were 15, 3 and 16 pg for cortisol, Δ 4-androstenedione and testosterone, respectively. Results are expressed as mean \pm s.e.m., and statistical significance was assessed by Bonferroni's test after one-way ANOVA.

Results

Adrenal origin of hyperandrogenism

Hormonal evaluation revealed high levels of Δ 4-androstenedione and testosterone (Table 2). ACTH stimulation test excluded 21-OH deficiency and was indicative of corticotropic insufficiency. Questioning revealed that the patient was using, on a daily basis, a whitening cream containing corticosteroids. Pelvic magnetic resonance imaging (MRI) revealed normal-sized ovaries, measuring for the right and the left 3.8 \times 2.7 and 4 \times 2.4 cm, respectively. No follicle larger than 16 mm could be visualized and the ovarian stroma was normal. Pituitary MRI was normal. Adrenal CT scan showed a 26 mm lesion of the right adrenal, with a density of 10 Hounsfield units and a wash-out higher than 60% (Fig. 1A). Urinary level of catecholamines was normal.

The patient was asked to stop using the steroid cream, one week before adrenal vein sampling. As shown in Fig. 1B, adrenal vein sampling indicated that Δ 4-androstenedione and testosterone excess was related to the right adrenal gland. Laparoscopic adrenalectomy was performed. Just after surgery, her testosterone level dropped to 1.6 nmol/l (normal value (N): 0.35–1.85). Her hirsutism decreased within 3 months. Three years later, her testosterone level was 1.10 nmol/l and Δ 4-androstenedione 4.8 nmol/l (N: 2–7.5).

Table 2 Plasma hormone concentrations at diagnosis.

Parameter	Value	Normal value
FSH (IU/l)	2.6	2–13
LH (IU/l)	2.1	1.5–11
Estradiol (pmol/l)	1060	80–370
Total testosterone (nmol/l)	5	0.35–1.85
SHBG (nmol/l)	33	40–80
Bioavailable testosterone (nmol/l)	1.1	0.06–0.25
Androstenedione (nmol/l)	24.3	2–7
Baseline 17-OH progesterone (nmol/l)	3.2	1–5
17-OHP post ACTH (nmol/l)	7.6	<25
DHEAS (μ mol/l)	1.2	1.5–7
Cortisol 0800 h (nmol/l)	175	220–610
Cortisol 60' post ACTH (nmol/l)	345	>540
ACTH (pg/ml)	5	9–52
Prolactin (ng/ml)	15	2–20
TSH (mIU/l)	1.86	0.15–3.7
Fasting glycaemia (mmol/l)	5.6	3.9–6.1
HbA1c (%)	6.6	4.3–6.1

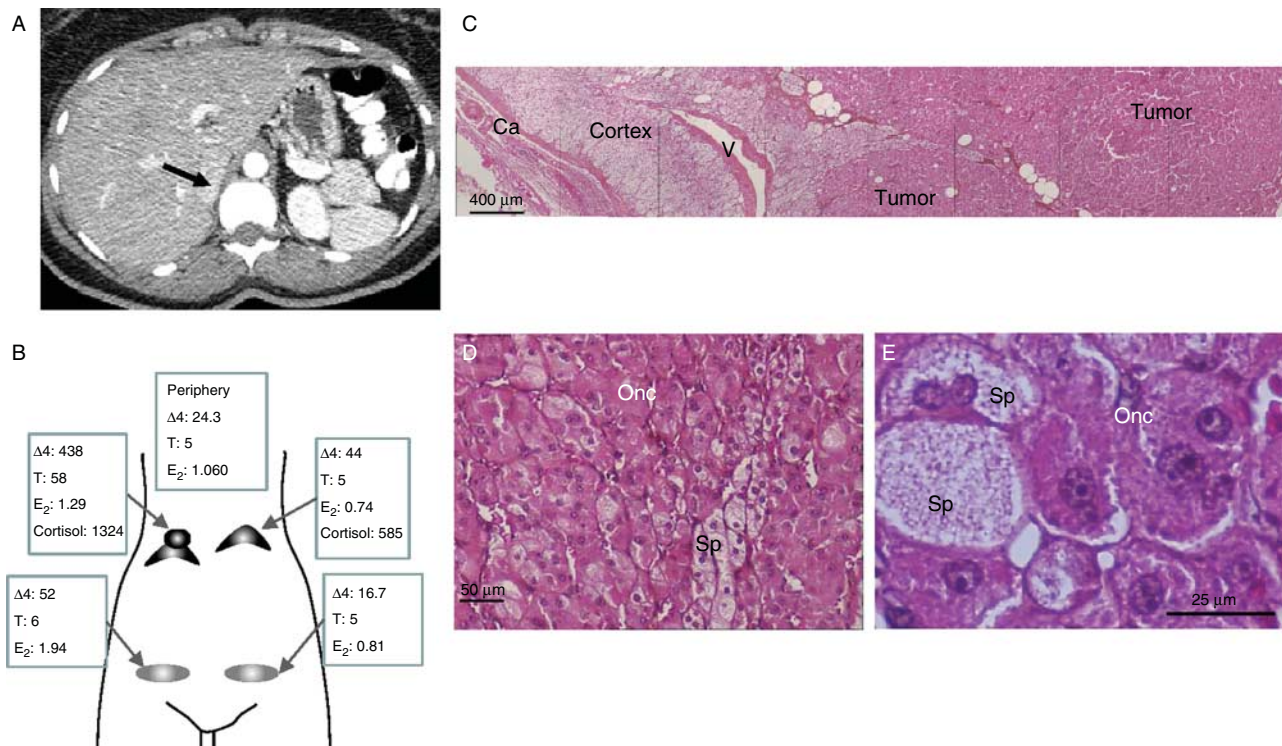
Pathological examination

At gross examination, the right adrenal showed a 2.6 \times 2.5 cm yellow nodule. Microscopically, the tumor was composed of eosinophilic cells with abundant granular cytoplasm characteristic from oncocytic cells (Fig. 1C, D and E). The Weiss score was evaluated at 2 (nuclear grade, \leq 25% spongiocytic cells) and the Lin Weiss and Bisceglia score (22) did not show any major or minor criterion. This adrenocortical tumor was classified as an oncocytoma.

Expression of steroidogenic enzymes

Expression of genes encoding different steroidogenic enzymes was determined by real-time RT-PCR in normal adrenal cortices and the adenoma tissue. In parallel, immunohistochemistry was performed to localize steroidogenic enzymes in the tissue sections from the patient in comparison with normal adrenal tissues.

Among genes encoding enzymes responsible for cortisol biosynthesis, *CYP17A1* (encoding 17 α -OH) and *CYP11B1* mRNAs (11 β -OH) were detected at higher levels than *HSD3B2* (3 β -HSD2) and *CYP21A2* (21-OH) in normal adrenals (Fig. 2A). *CYP17A1* and *HSD3B2* expression levels were quite similar in the adenoma samples to those observed in control tissues. In contrast, expression of *CYP21A2* and *CYP11B1* were much lower in the oncocytoma than in normal tissues. As expected, intense 17 α -OH and 3 β -HSD2 immunoreactivities were present in ZF of normal adrenals (Fig. 2B). In the adenoma, very intense immunostaining for 17 α -OH and 3 β -HSD2 was detected in almost all oncocytic cells and heterogeneous

**Figure 1**

(A) Abdominal CT scan showing a nodule of the right adrenal gland (arrow) reaching 26 mm in diameter. (B) Plasma concentrations of cortisol, Δ 4-androstenedione (Δ 4), testosterone (T) and/or estradiol (E_2) in blood samples from peripheral, right and left adrenal and ovary veins expressed in nmol/L. (C, D and E) Microscopic views of the adrenal tissue (HES

coloration) at low (C) and high (D and E) magnifications showing the adenoma tissue adjacent to residual cortex. The adenoma was composed of oncocytic cells with abundant granular cytoplasm. Some spongiocytic cells from the residual cortex were present between tumor lobules. Ca, capsule; V, vein; Onc, oncocytic cells; Sp, spongiocytic cells.

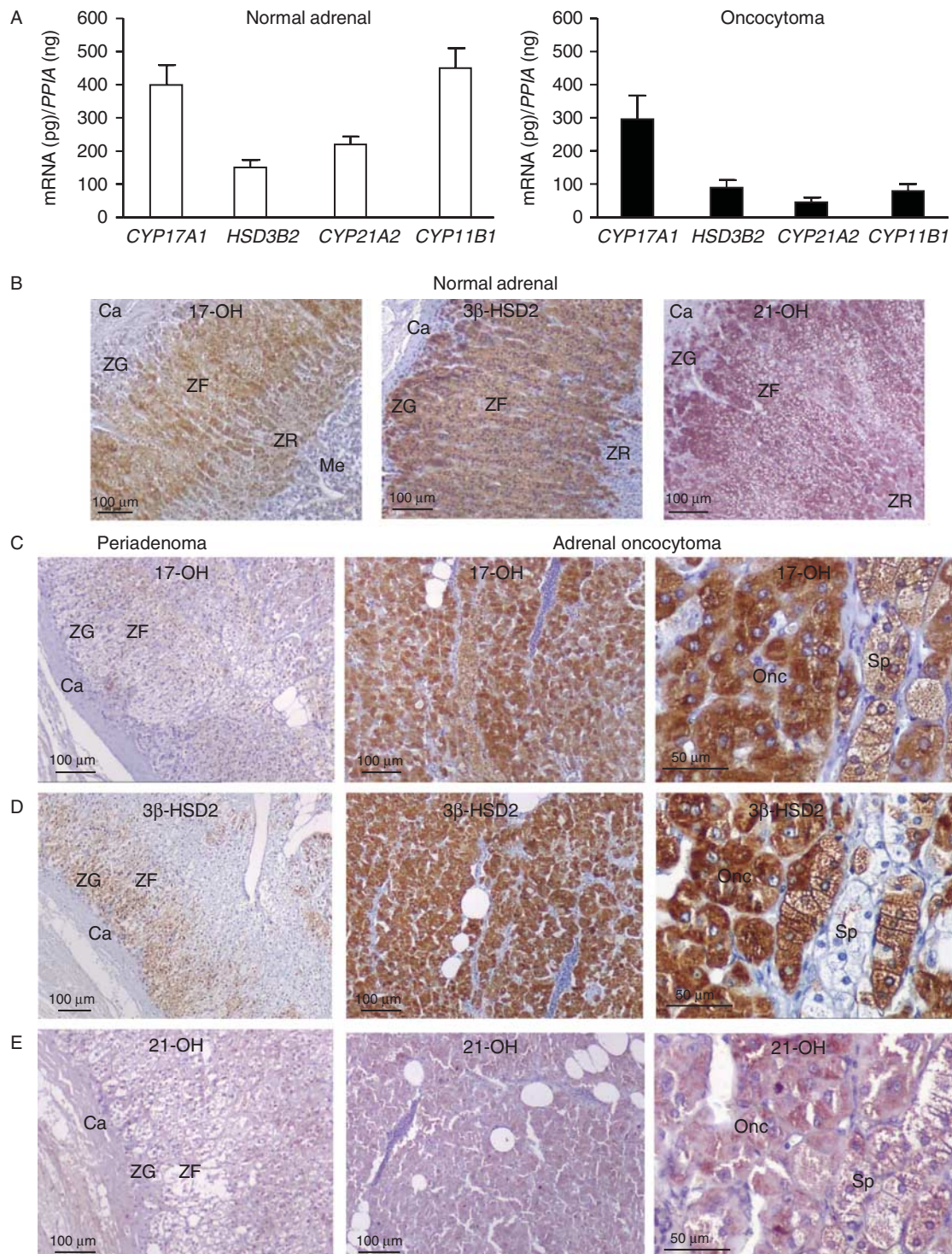
immunolabeling was observed in spongiocytic cells (Fig. 2C and D). Immunostaining for 21-OH was weaker in the adenoma than in normal adrenals (Fig. 2B and E). The remaining peritumoral cortex showed little or no immunolabeling for 17α -OH, 3β -HSD2 and 21-OH, indicating that steroidogenesis was downregulated in the residual tissue (Fig. 2C, D and E). Globally, abundant 17α -OH and 3β -HSD2 signals in combination with rare 21-OH and 11β -OH immunoreactivities in the adenoma were indicative of modest cortisol biosynthesis and accumulation of 17-hydroxyprogesterone (17-OHP) in oncocytic cells (Table 3). However, detection in the adenoma tissue of *CYP5A* gene transcripts encoding cytochrome B5 (Fig. 3A), the allosteric factor required for the 17,20-lyase activity of 17α -OH, indicated that 17-OHP could be actively metabolized into Δ 4-androstenedione by tumor cells.

Among transcripts encoding the different isoforms of 17β -HSD, which are enzymes catalyzing the conversion

of Δ 4-androstenedione into testosterone, *AKR1C3* mRNA (encoding 17β -HSD5) levels were higher than those of *HSD17B3* (encoding 17β -HSD3) in both the adenoma and normal adrenal tissues (Fig. 3A). Both 17β -HSD5 and 17β -HSD3 immunoreactivities were observed in zona glomerulosa and ZR of normal adrenals (Fig. 3B). In the adrenocortical lesion, weak labeling for 17β -HSD5 and intense 17β -HSD3 immunostaining were detected in clusters of oncocytic cells (Fig. 3C and Table 3). Expression of *CYP19A1* encoding aromatase, the estrogen synthesizing enzyme, was low and variable in normal adrenal samples and was negligible in the adenoma tissue (not shown).

Steroid hormone secretion

Cultured adrenocortical cells derived from the adenoma secreted for 24 h significant amounts of Δ 4-androstenedione (4.1 ± 0.3 ng/ 10^6 cells), testosterone

**Figure 2**

Expression pattern of cortisol-synthesizing enzymes in normal adrenals and the androgen-secreting oncocytoma. (A) Expression mRNA levels of *CYP17A1*, *HSD3B2*, *CYP21A2* and *CYP11B1* normalized to *PPIA* (cyclophilin) in normal adrenals (white bars) and two samples from the adrenocortical tumor (black bars). (B, C, D and E) Immunohistochemical localization of 17 α -hydroxylase/17,20 lyase (17 α -OH), 3 β -hydroxysteroid dehydrogenase

(3 β -HSD2) and 21-OH in normal adrenal (B), periadrenoma tissue (C, D and E left) and the adrenocortical oncocytoma at low (C, D and E middle) and high magnifications (C, D and E right). Ca, capsule; ZG, zona glomerulosa; ZF, zona fasciculata; ZR, zona reticularis; Me, medulla; Onc, oncocytic cells; Sp, spangiocytic cells.

Table 3 Scores of steroidogenic enzyme immunoreactivities in normal and tumor adrenocortical tissues.

Steroidogenic enzyme immunoreactivities	Normal adrenal			Adrenocortical tumor	
	ZG	ZF	ZR	Periadenoma	Oncocytoma
17 α -OH	0	7	5	2	7
3 β -HSD2	7	7	2	4	7
21-OH	7	7	2	0	4
17 β -HSD5	5	0	5	0	4
17 β -HSD3	3	0	5	0	5

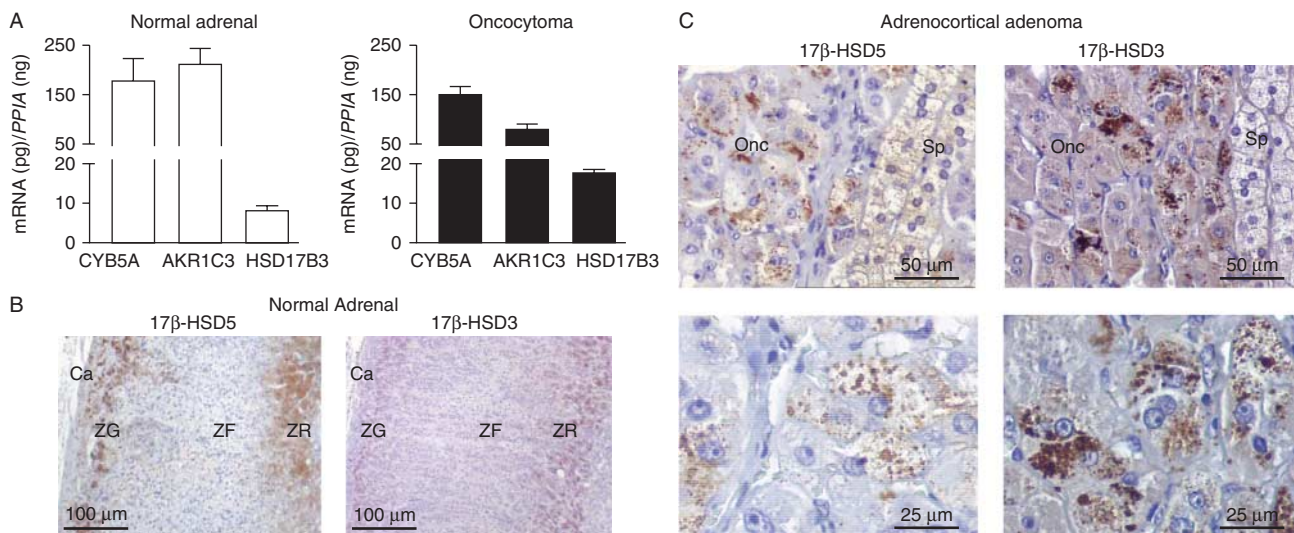
Histological score integrates the extent (graded as 0: no staining, 1: <10%, 2: 11–50%, 3: 51–80% and 4: >80% of the cells) and staining intensity (graded as 0: no staining, 1: weak, 2: moderate and 3: strong staining).

(2.3 ± 0.2 ng/ 10^6 cells) and cortisol (24.3 ± 2.5 ng/ 10^6 cells) (Fig. 4A). Incubation of cells with increasing concentrations of ACTH (10^{-12} – 10^{-9} M) provoked dose-dependent stimulations of $\Delta 4$ -androstenedione ($+68.1 \pm 3.8\%$), testosterone ($+40.6 \pm 4.4\%$) and cortisol ($+181.3 \pm 8.9\%$) secretions (Fig. 4B, C and D). ACTH was more efficient for stimulating $\Delta 4$ -androstenedione ($P=0.003$) and cortisol ($P<0.0001$) than testosterone secretion. However, the stimulatory effect of ACTH on cortisol secretion was weak in tumor cells in comparison with normal adrenocortical cells (approximately +1000%) (23). The Leydig-cell-like expression pattern of steroidogenic enzymes prompted us to investigate the involvement of LH/hCG receptors in

the control of steroidogenesis in adenoma cells. hCG (10^{-12} – 10^{-7} M) had no effect on steroid production.

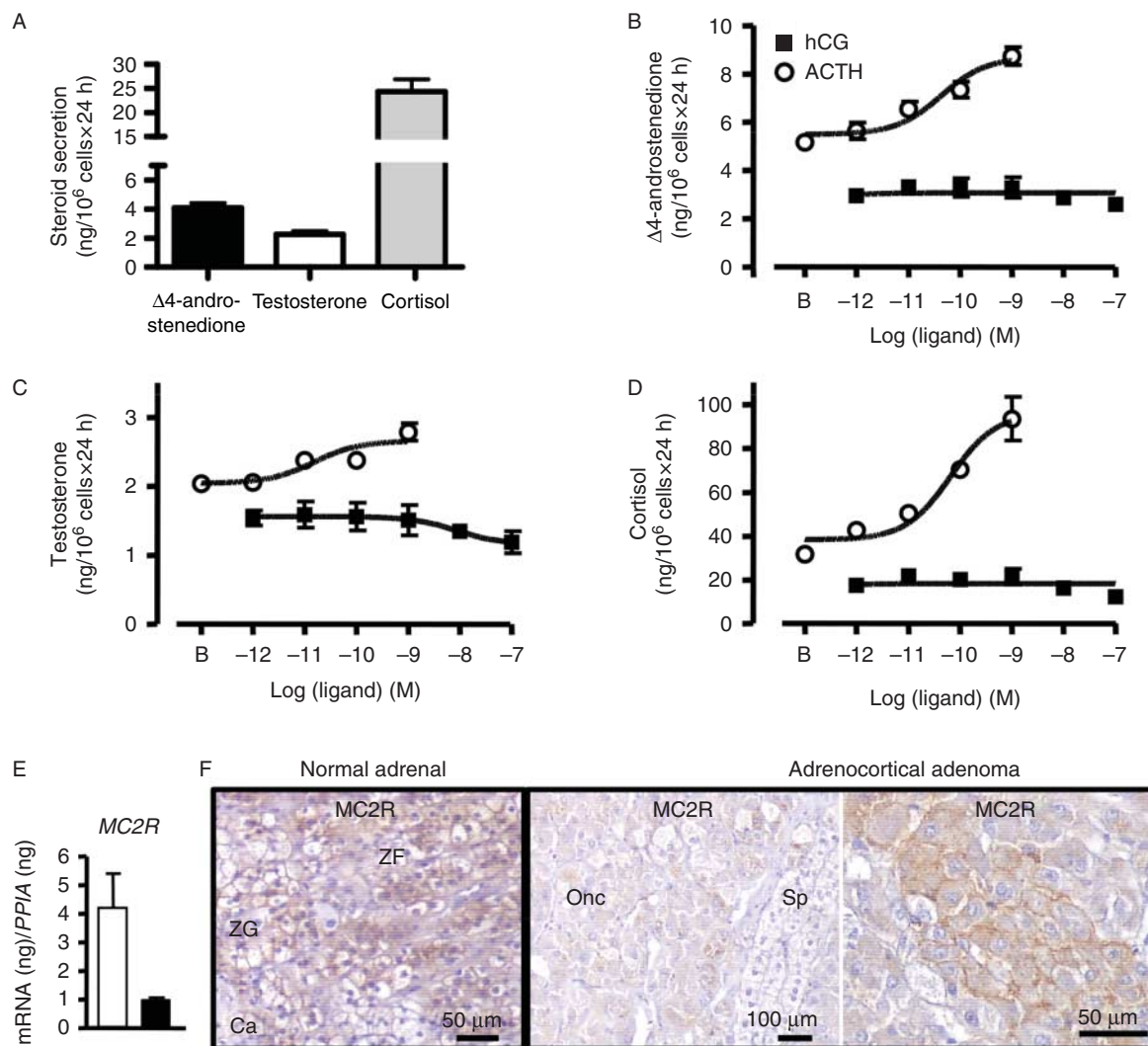
Expression of ACTH receptor

Expression level of MC2R mRNAs, encoding the MC2R selective for ACTH, in the tissue of the patient was four times lower than that detected in normal adrenals (Fig. 4E). Intense MC2R immunoreactivity was observed throughout the ZF of normal adrenals whereas weak labeling was present in clusters of oncocytic cells in the adenoma (Fig. 4F). As expected, no LH receptor-immunostaining was detected in the adenoma tissue (not shown).

**Figure 3**

Expression pattern of androgen-synthesizing enzymes in normal adrenals and the androgen-secreting oncocytoma. (A) Expression mRNA levels of *CYB5*, *AKR1C3* and *HSD17B3* normalized to *PPIA* (cyclophilin) in normal adrenals (white bars) and two samples of the adrenocortical tumor (black bars). (B and C) Immunohistochemical localization of 17 β -hydroxysteroid

dehydrogenase types 5 (17 β -HSD5; left) and 3 (17 β -HSD3; right) in normal adrenal (B) and the adrenocortical oncocytoma (C) at low (above) and high magnifications (below). Ca, capsule; ZG, zona glomerulosa; ZF, zona fasciculata; ZR, zona reticularis; Onc, oncocytic cells; Sp, spongiocytic cells.

**Figure 4**

Steroid secretion by cultured adrenocortical oncocytoma cells derived from the patient with hirsutism. (A) Spontaneous secretions of $\Delta 4$ -androstenedione, testosterone and cortisol by cultured oncocytoma cells. (B, C and D) Effects of increasing doses of ACTH (10^{-12} – 10^{-9} M; open symbols) and human chorionic gonadotropin (hCG; 10^{-12} – 10^{-7} M; filled symbols) on $\Delta 4$ -androstenedione (B), testosterone (C) and cortisol (D) secretion by cultured oncocytoma cells. (E and F) Expression of melanocortin type 2

receptor (MC2R) in normal adrenals and the androgen-secreting oncocytoma. Expression levels of mRNA for *MC2R* (E) normalized to *PPIA* (cyclophilin) in normal adrenals (white bars) and two samples of the adrenocortical tumor (black bars). Immunohistochemical localization of MC2R in normal adrenal and the adrenocortical tumor (F). Ca, capsule; ZG, zona glomerulosa; ZF, zona fasciculata; Onc, oncocytic cells; Sp, spongiocytic cells.

Discussion

Our female patient, presenting with a right adrenal incidentaloma, was referred for hirsutism associated with high plasma $\Delta 4$ -androstenedione and testosterone levels. On the basis of ovarian and adrenal vein sampling, androgen overproduction clearly originated from the right adrenal gland. This was confirmed by normalization of circulating hormone levels after right adrenalectomy

and *in vitro* production of $\Delta 4$ -androstenedione and testosterone by tumor cells in culture.

Pathological examination of the tumor revealed the presence of dense cells with eosinophilic and granular cytoplasm characteristic of oncocytic cells (21). Adrenal oncocytomas are extremely rare tumors (21). They have been reported in the majority in females, both in children and adult patients (18, 19, 20, 24). Like the majority of

adrenal oncocytomas (22, 25), the present tumor was benign as indicated by the low Lin–Weiss–Bisceglia score.

The majority of adrenal oncocytoma are non-functional tumors which are incidentally diagnosed. In a few cases, they have been associated with hirsutism and/or virilization due to testosterone and/or DHEAS production, as in the present case (18, 19, 20, 26, 27). Adrenocortical benign oncocytomas and oncocytic carcinomas represent very rare causes of primary adrenal Cushing's syndrome (20, 27, 28, 29, 30). Our patient did not exhibit clinical or biological signs of cortisol overproduction. In contrast, she presented with low cortisol and ACTH plasma concentrations at baseline, as well as a weak cortisol increase in response to i.v. infusion of ACTH. This corticotroph insufficiency could probably be ascribed to inhibition of ACTH secretion by the glucocorticoid-containing bleaching cream used by this black African patient. Interestingly, her androgen levels originating from the adrenal could have been reduced due to this cream. Despite the low cortisol levels, several lines of evidence indicate that the oncocytoma did produce glucocorticoid: i) a gradient in cortisol concentrations was observed between right and left adrenal veins; ii) immunoreactivities for 17-OH, 3 β -HSD2 and 21-OH were more intense in the adenoma than peritumoral tissue and iii) tumor cells in culture secreted cortisol. We can thus presume that, in the absence of the cortisol-secreting oncocytoma, the patient would have had more severe adrenal insufficiency.

In order to elucidate the mechanism responsible for the unusual steroid secretory profile of the adrenal oncocytoma, we have characterized the expression pattern of steroidogenic enzymes by combination of RT-PCR and immunohistochemical approaches. Intense expression of 17 α -OH and 3 β -HSD2, two enzymes involved in both glucocorticoid and androgen synthesis, concomitant with moderate expression of 21-OH and 11 β -OH, two enzymes that catalyze the final steps of cortisol formation, indicates that oncocytic cells were able to metabolize cholesterol into 17-OHP with high efficacy but were less efficient at synthesizing cortisol (Fig. 5).

CYB5 is a cofactor essential for the 17,20-lyase activity of 17 α -OH (31). In normal adrenal, co-expression of 17 α -OH and CYB5 in ZR leads to synthesis of DHEA. In oncocytic cells, additional expression of 3 β -HSD2 besides 17 α -OH and CYB5 probably accounts for by production of Δ 4-androstenedione instead of DHEA (Fig. 5). These findings are also consistent with the normal preoperative plasma concentrations of 17-OHP and 11-deoxycortisol observed both under basal conditions and after stimulation with tetracosactin, 17-OHP being actively metabolized into Δ 4-androstenedione.

It is well established that Δ 4-androstenedione can be metabolized into testosterone by different 17 β -HSD isoforms (32). Occurrence of both 17 β -HSD types 3 and 5 isoforms in the tumor at transcript and protein levels was thus consistent with testosterone synthesis. In comparison with the large distribution of 17 α -OH and 3 β -HSD2

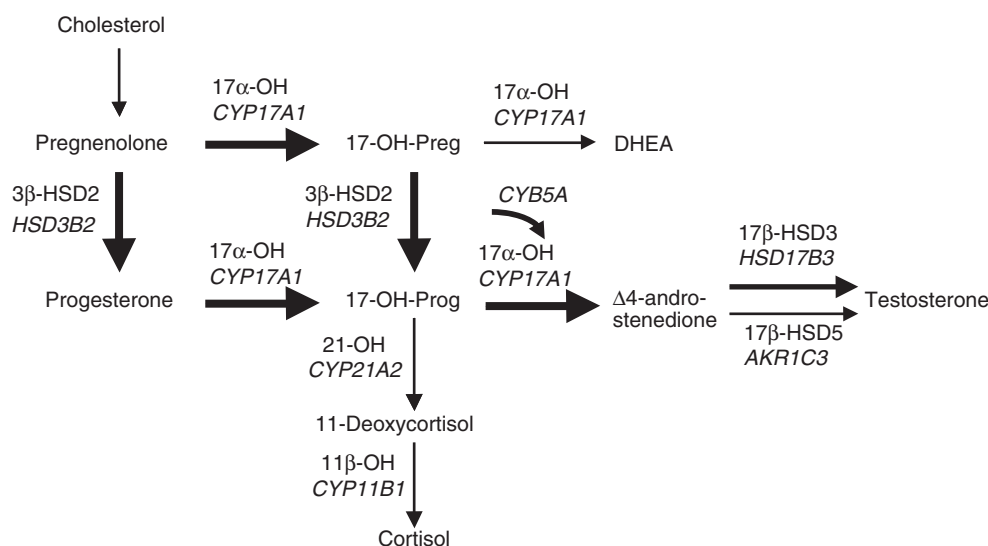


Figure 5

Genes encoding the different enzymes involved in steroidogenic pathways. Thin and thick arrows represent weak and intense enzymatic activities in the androgen-secreting oncocytoma respectively.

immunoreactivities in almost all oncocytic cells, the limited occurrence of 17 β -HSD3 and 17 β -HSD5 in only a subpopulation of tumor cells may explain the predominance Δ 4-androstenedione production over testosterone secretion, observed *in vivo* and *in vitro* (Fig. 5).

From a physiopathological point of view, the lack of *CYP19* mRNA (encoding aromatase) and LH/hCG receptor indicates that androgen production was not the result of gonadal-like differentiation of adrenal tumor cells. In contrast, the fact that the oncocytoma expressed proteins usually synthesized in adrenal ZF, such as 17 α -OH, 3 β -HSD2, 21-OH, 11 β -OH and MC2R, as well as enzymes known to be produced in ZR, including 17 α -OH, *CYB5* and 17 β -HSD3/5, indicated an intermediate adrenocortical phenotype.

In conclusion, we report a very unusual case of virilizing adrenocortical oncocytoma. The results of the study of the steroidogenic profile of the tumor tissue indicated that, in spite of their singular appearance, oncocytic adrenal cells harbor a functional adrenocortical phenotype which seems to be intermediate between those of ZF and ZR cells.

Declaration of interest

The authors declare that there is no conflict of interest that could be perceived as prejudicing the impartiality of the research reported.

Funding


This work was funded through institutional supports from Institut National de la Santé et de la Recherche Médicale (INSERM).

Acknowledgements

We are indebted to Dr Etienne D'Hubert and Hadrien-Gaël Boyer for their collaboration. We are grateful to Huguette Lemonnier for skilful technical assistance. Images were obtained on PRIMACEN, the Cell Imaging Platform of Normandy, University of Rouen.

References

- 1 Kumar A, Woods KS, Bartolucci AA & Azziz R. Prevalence of adrenal androgen excess in patients with the polycystic ovary syndrome (PCOS). *Clinical Endocrinology* 2005 **62** 644–649. (doi:10.1111/j.1365-2265.2005.02256.x)
- 2 Somani N, Harrison S & Bergfeld WF. The clinical evaluation of hirsutism. *Dermatologic Therapy* 2008 **21** 376–391. (doi:10.1111/j.1529-8019.2008.00219.x)
- 3 Bode D, Seehusen DA & Baird D. Hirsutism in women. *American Family Physician* 2012 **85** 373–380.
- 4 Rotterdam ESHRE/ASRM-Sponsored PCOS consensus workshop group. Revised 2003 consensus on diagnostic criteria and long-term health risks related to polycystic ovary syndrome (PCOS). *Human Reproduction* 2004 **19** 41–47. (doi:10.1093/humrep/deh098)
- 5 Carmina E, Rosato F, Janni A, Rizzo M & Longo RA. Extensive clinical experience: relative prevalence of different androgen excess disorders in 950 women referred because of clinical hyperandrogenism. *Journal of Clinical Endocrinology and Metabolism* 2006 **91** 2–6. (doi:10.1210/jc.2005-1457)
- 6 Unluhizarci K, Karaca Z & Kelestimur F. Hirsutism – from diagnosis to use of antiandrogens. *Frontiers of Hormone Research* 2013 **40** 103–114. (doi:10.1159/000341822)
- 7 d'Alva CB, Abiven-Lepage G, Viallon V, Groussin L, Dugue MA, Bertagna X & Bertherat J. Sex steroids in androgen-secreting adrenocortical tumors: clinical and hormonal features in comparison with non-tumoral causes of androgen excess. *European Journal of Endocrinology* 2008 **159** 641–647. (doi:10.1530/EJE-08-0324)
- 8 Pugeat M, Déchaud H, Raverot V, Denuzière A, Cohen R, Boudou P & French Endocrine Society. Recommendations for investigation of hyperandrogenism. *Annales d'Endocrinologie* 2010 **71** 2–7. (doi:10.1016/j.ando.2009.12.007)
- 9 Denny MC, Smith D, O'Shea D & McKenna TJ. Investigation of patients with atypical or severe hyperandrogenaemia including androgen-secreting ovarian teratoma. *European Journal of Endocrinology* 2010 **162** 213–220. (doi:10.1530/EJE-09-0576)
- 10 Sachdeva P, Arora R, Dubey C, Sukhija A, Daga M & Singh DK. Sertoli–Leydig cell tumor: a rare ovarian neoplasm. Case report and review of literature. *Gynecological Endocrinology* 2008 **24** 230–234. (doi:10.1080/09513590801953465)
- 11 Persechini M-L, Motton S, Leguevaque P, Donadille F, Escourrou G, Vierasu B, Hamdi S, Bennet A & Caron P. Virilizing ovarian tumour: a case associating a Sertoli–Leydig cell tumour and a Brenner tumour. *Gynecological Endocrinology* 2011 **27** 345–350. (doi:10.3109/09513590.2010.492883)
- 12 Libè R, Fratticci A & Bertherat J. Adrenocortical cancer: pathophysiology and clinical management. *Endocrine-Related Cancer* 2007 **14** 13–28. (doi:10.1677/erc.1.01130)
- 13 Goodarzi MO, Dawson DW, Li X, Lei Z, Shintaku P, Rao CV & Van Herle AJ. Virilization in bilateral macronodular adrenal hyperplasia controlled by luteinizing hormone. *Journal of Clinical Endocrinology and Metabolism* 2003 **88** 73–77. (doi:10.1210/jc.2002-021292)
- 14 Ghayee HK, Rege J, Watumull LM, Nwariaku FE, Carrick KS, Rainey WE, Miller WL & Auchus RJ. Clinical, biochemical, and molecular characterization of macronodular adrenocortical hyperplasia of the zona reticularis: a new syndrome. *Journal of Clinical Endocrinology and Metabolism* 2011 **96** E243–E250. (doi:10.1210/jc.2010-1222)
- 15 Kamenicky P, Houdoin L, Ferlicot S, Salenave S, Brailly S, Droupy S, Meduri G, Sasano H, Suzuki T, Young J *et al.* Benign cortisol-secreting adrenocortical adenomas produce small amounts of androgens. *Clinical Endocrinology* 2007 **66** 778–788. (doi:10.1111/j.1365-2265.2007.02810.x)
- 16 Hofland J, de Herder WW, Derks L, Hofland LJ, van Koetsveld PM, de Krijger RR, van Nederveen FH, Horvath A, Stratakis CA, de Jong FH *et al.* Regulation of steroidogenesis in a primary pigmented nodular adrenocortical disease-associated adenoma leading to virilization and subclinical Cushing's syndrome. *European Journal of Endocrinology* 2013 **168** 67–74. (doi:10.1530/EJE-12-0594)
- 17 Rondeau G, Nolet S, Latour M, Braschi S, Gaboury L, Lacroix A, Panzini B, Arjane P, Cohade C & Bourdeau I. Clinical and biochemical features of seven adult adrenal ganglioneuromas. *Journal of Clinical Endocrinology and Metabolism* 2010 **95** 3118–3125. (doi:10.1210/jc.2009-2775)
- 18 Lim Y-J, Lee S-M, Shin J-H, Koh H-C & Lee Y-H. Virilizing adrenocortical oncocytoma in a child: a case report. *Journal of Korean Medical Science* 2010 **25** 1077–1079. (doi:10.3346/jkms.2010.25.7.1077)
- 19 Gumy-Pause F, Bongiovanni M, Wildhaber B, Jenkins JJ, Chardot C & Ozsahin H. Adrenocortical oncocytoma in a child. *Pediatric Blood & Cancer* 2008 **50** 718–721. (doi:10.1002/pbc.21090)
- 20 Logasundaram R, Parkinson C, Donaldson P & Coode PE. Co-secretion of testosterone and cortisol by a functional adrenocortical oncocytoma.



- Histopathology* 2007 **51** 418–420. (doi:10.1111/j.1365-2559.2007.02780.x)
- 21 Mearini L, Del Sordo R, Costantini E, Nunzi E & Porena M. Adrenal oncocytic neoplasm: a systematic review. *Urologia Internationalis* 2013 **91** 125–133. (doi:10.1159/000345141)
- 22 Bisceglia M, Ludovico O, Di Mattia A, Ben-Dor D, Sandbank J, Pasquinelli G, Lau SK & Weiss LM. Adrenocortical oncocytic tumors: report of 10 cases and review of the literature. *International Journal of Surgical Pathology* 2004 **12** 231–243. (doi:10.1177/106689690401200304)
- 23 Assie G, Louiset E, Sturm N, René-Corail F, Groussin L, Bertherat J, Thomas M, Lefebvre H, Feige J-J, Clauser E et al. Systematic analysis of G protein-coupled receptor gene expression in adrenocorticotropin-independent macronodular adrenocortical hyperplasia identifies novel targets for pharmacological control of adrenal Cushing's syndrome. *Journal of Clinical Endocrinology and Metabolism* 2010 **95** E253–E262. (doi:10.1210/jc.2009-2281)
- 24 Song SY, Park S, Kim SR & Suh Y-L. Oncocytic adrenocortical carcinomas: a pathological and immunohistochemical study of four cases in comparison with conventional adrenocortical carcinomas. *Pathology International* 2004 **54** 603–610. (doi:10.1111/j.1440-1827.2004.01669.x)
- 25 Duregon E, Volante M, Cappia S, Cucurullo A, Bisceglia M, Wong DD, Spagnolo DV, Szpak-Ulczo S, Bollito E, Daffara F et al. Oncocytic adrenocortical tumors: diagnostic algorithm and mitochondrial DNA profile in 27 cases. *American Journal of Surgical Pathology* 2011 **35** 1882–1893. (doi:10.1097/PAS.0b013e31822da401)
- 26 Mwandila M, Waller H, Stott V & Mercer P. A case of a testosterone-secreting oncocytic adrenocortical carcinoma. *New Zealand Medical Journal* 2010 **123** 80–82.
- 27 Sahin SB, Yucel AF, Bedir R, Ogullar S, Ayaz T & Algun E. Testosterone- and cortisol-secreting adrenocortical oncocytoma: an unusual cause of hirsutism. *Case Reports in Endocrinology* 2014 **2014** 206890. (doi:10.1155/2014/206890)
- 28 Ali AE & Raphael SJ. Functional oncocytic adrenocortical carcinoma. *Endocrine Pathology* 2007 **18** 187–189. (doi:10.1007/s12022-007-9000-4)
- 29 Kabayegit OY, Soysal D, Oruk G, Ustaoglu B, Kosan U, Solmaz S & Avci A. Adrenocortical oncocytic neoplasm presenting with Cushing's syndrome: a case report. *Journal of Medical Case Reports* 2008 **2** 228. (doi:10.1186/1752-1947-2-228)
- 30 Pereira BD, Rios ES, Cabrera RA, Portugal J & Raimundo L. Adrenocortical oncocytoma presenting as Cushing's syndrome: an additional report of a paediatric case. *Endocrine Pathology* 2014 **25** 397–403. (doi:10.1007/s12022-014-9325-8)
- 31 Storbeck K-H, Swart AC, Goosen P & Swart P. Cytochrome b₅: novel roles in steroidogenesis. *Molecular and Cellular Endocrinology* 2013 **371** 87–99. (doi:10.1016/j.mce.2012.11.020)
- 32 Labrie F, Luu-The V, Lin SX, Simard J, Labrie C, El-Alfy M, Pelletier G & Bélanger A. Intracrinology: role of the family of 17 β -hydroxysteroid dehydrogenases in human physiology and disease. *Journal of Molecular Endocrinology* 2000 **25** 1–16. (doi:10.1677/jme.0.0250001)

Received in final form 20 March 2015

Accepted 27 April 2015

