



HAL
open science

Normotensive Incidentally Discovered Pheochromocytomas Display Specific Biochemical, Cellular, and Molecular Characteristics

Magalie Haissaguerre, Maité Courel, Sophie Denost, Laurent Yon, Christophe Dubessy, Philippe Gosse, Vincent Appavoupouille, Genevieve Belleannée, Marie-Laure Jullié, Maite Montero-Hadjadje, et al.

► To cite this version:

Magalie Haissaguerre, Maité Courel, Sophie Denost, Laurent Yon, Christophe Dubessy, et al.. Normotensive Incidentally Discovered Pheochromocytomas Display Specific Biochemical, Cellular, and Molecular Characteristics. *Journal of Clinical Endocrinology and Metabolism*, 2013, 98 (11), pp.4346-4354. 10.1210/jc.2013-1844 . hal-01706417

HAL Id: hal-01706417

<https://normandie-univ.hal.science/hal-01706417>

Submitted on 18 Jul 2018

HAL is a multi-disciplinary open access archive for the deposit and dissemination of scientific research documents, whether they are published or not. The documents may come from teaching and research institutions in France or abroad, or from public or private research centers.

L'archive ouverte pluridisciplinaire **HAL**, est destinée au dépôt et à la diffusion de documents scientifiques de niveau recherche, publiés ou non, émanant des établissements d'enseignement et de recherche français ou étrangers, des laboratoires publics ou privés.

Normotensive incidentally discovered pheochromocytomas display specific biochemical, cellular and molecular characteristics

Magalie Haissaguerre, Maïté Courel (first two equally participated), Philippe Caron, Sophie Denost, Christophe Dubessy, Philippe Gosse, Vincent Appavoupouille, Geneviève Belleannée, Marie-Laure Jullié, Maïté Montero-Hadjadje, Laurent Yon, Jean-Benoît Corcuff, Cédric Fagour, Catherine Mazerolles, Tristan Wagner, Marie-Laure Nunes, Youssef Anouar, and Antoine Tabarin

Departments of Endocrinology (M.H., SD, V.A., M-L.N., A.T.), Pathology (G.B., M-L.J.), Nuclear Medicine (J-B.C.) Endocrine Surgery (T.W.) and Cardiology (P.G.), CHU Bordeaux and University Victor Segalen –Bordeaux 2, France; INSERM Unit 982 and Laboratory of Neuronal and Neuroendocrine Communication, Institut for Research and Innovation on Biomedicine (M.C., C.D., M.M-H., L.Y., Y.A.), University of Rouen, MT-St-Aignan, France; Department of Endocrinology and Metabolic diseases, (P.C.) and Department of pathology, (C.M.), CHU of Toulouse; France; Department of Endocrinology (C.F.), CHU Ft-de-France, Martinique.

Context: A number of incidentally discovered pheochromocytomas are not associated with hy-pertension. The characteristics of normotensive incidentally discovered pheochromocytomas (NIP) are poorly known.

Objective: To assess the clinical, hormonal, histological and molecular features of NIP

Design: Retrospective cohort recruited from 2001 to 2011 in 2 tertiary-care medical departments.

Patients and Methods: Clinical, biological and radiological investigations performed in 96 con-secutive patients with sporadic unilateral pheochromocytomas were examined. 47 patients had overt pheochromocytomas responsible for hypertension. Among incidental pheochromocytomas, 28 patients had hypertension and 21 were normotensive (NIP). 62 tumors were examined for the PASS score, and 29 studied for the expression of 16 genes involved in chromaffin cell function.

Results: Tumor size and MIBG scintigraphy results were similar between hypertensive pheochro-mocytomas (HP) and NIP. NIP patients displayed reduced summed levels of urinary catecholamines and metanephrines and, more specifically, reduced levels of adrenaline and metadrenaline com-pared to HP patients ($P < 0.001$). Urinary metanephrines had 98% diagnostic sensitivity in HP patients and only 75% in NIP patients ($P < 0.01$). Tumor diameter positively correlated with total amount of urinary concentrations of metanephrines in HP patients, ($P < 0.001$) but not in NIP patients. NIP displayed a global decreased chromaffin genes expression, reaching significance for 5 of them and 2 corresponding proteins: Phenylethanolamine N-methyltransferase, secretogranin II, and a significant increase in the cellularity, mitotic activity, and presence of atypical mitosis ($P < 0.05$).

Conclusions: Normotensive incidentally discovered pheochromocytomas differ from pheochro-mocytomas responsible for hypertension and display features of altered chromaffin differentia-tion. Usual biological diagnostic tools may misdiagnose these tumors.

Pheochromocytomas are rare neuroendocrine tumors arising from chromaffin cells of the adrenal medulla that produce and release catecholamines and their metabolites. Despite major advances in the biological tools to

diagnose these tumors (1), a significant number of pheochromocytomas are undiagnosed and found incidentally during radiological abdominal investigations (2, 3). Pheochromocytomas account for up to 5% of adrenal incidentalomas in nononcologic series (4) and incidental discovery may represent up to 25% of cases in recent pheochromocytomas series (5–9). The rarity of pheochromocytomas, the nonspecificity of clinical symptoms and the widespread availability of imaging procedures may account for the increasing prevalence of incidental discovery. Lack of hemodynamic features including hypertension has been reported in 13.5% (7) to 55% (9) of incidental pheochromocytomas series and may also account for misdiagnosis. No comprehensive study examining the clinical manifestations of normotensive incidental pheochromocytomas (NIP), their relationship with *in vivo* hormonal evaluation and tumor biology is currently available. The aim of this study was to elucidate the nature of NIP by comparing their clinical, hormonal, radiological, pathological and molecular features to that of pheochromocytomas responsible for hypertension.

Materials and Methods

Patients

This retrospective study included 96 patients recruited during the 2001 to 2011 period. Seventy-six consecutive patients were recruited at the University Hospital of Bordeaux, France and 20 cases were recruited at the University Hospital of Toulouse, France. Patients enrolled in the study had apparently sporadic pheochromocytomas. Patients with bilateral pheochromocytomas, with a personal or familial history of paraganglioma or disease associated with chromaffin tumor were excluded. Genetic testing for MEN2, VHL and SDHB and D mutations was performed routinely in all patients below 50 y (10) and only patients without genetic alterations were included.

Written consent was obtained in all patients in whom molecular analysis of the pheochromocytoma was performed and in most other patients. When informed consent was not obtained, the data were collected under conditions of regular clinical care with local ethics committee approval obtained for the use of those data.

Clinical evaluation of patients included detailed inventory of clinical symptoms, at least 3 daily measurements of systolic and diastolic blood pressure (BP) for 2 d in the recumbent position for 30 min and at least 2 evaluations of BP in the upright position. Hypertension was defined as increased systolic or diastolic BP above 140 or 90 mmHg respectively or use of antihypertensive medication. The classic triad was defined by the simultaneous occurrence of headache, palpitations and sweating. Orthostatic hypotension was defined as a fall in BP one min after standing \geq 20 mmHg for SBP and \geq 10 mmHg for DBP. Resistant hypertension was defined by persistence of hypertension despite at

least 3 antihypertensive treatments or the need for at least 4 treatments to control BP.

Forty-seven patients (49%) had an overt pheochromocytoma diagnosed during the work-up of hypertension. Discovery of pheochromocytoma was incidental in 49 patients (51%). Incidental discovery was defined as unexpected detection with an imaging procedure performed for reasons a priori unrelated to adrenal dysfunction. Among patients with incidental pheochromocytomas, 28 had hypertension and 21 were strictly normotensive (NIP group). Extensive interview of NIP patients and their general practitioner failed to identify episodes of hypertension or clinically related symptoms. Compared to patients with overt pheochromocytomas, patients with incidental pheochromocytomas associated with hypertension were older (59.0 ± 2.3 yr vs 52.7 ± 2.1 yr respectively; $P < .05$) and had a reduced prevalence of the classical clinical triad (11% vs 45% respectively; $P < .01$). However, from a clinical perspective, patients with overt pheochromocytomas and patients with incidental pheochromocytomas associated with hypertension shared many features including duration of hypertension (78 ± 21 mo vs 55 ± 14 mo respectively; $P = .14$), prevalence of resistant hypertension (21% vs 18% respectively), number of antihypertensive treatments (1.5 ± 0.2 vs 1.7 ± 0.2 respectively), systolic BP levels (138 ± 2 mm Hg vs 143 ± 3 mm Hg respectively) and diastolic BP levels (80 ± 2 mm Hg vs 81 ± 2 mm Hg). Given the clinical similarities, these patients were considered as a single group (hypertensive pheochromocytomas or HP) and compared to NIP.

All patients had at least one measurement of 24 h urinary fractionated metanephrines. Additionally, 80 and 45 of them had at least one measurement of 24 h urinary free catecholamines and plasma metanephrines, respectively. All patients underwent thin-slice adrenal CT imaging. MIBG scintigraphy was performed in 49 patients with HP and 10 patients with NIP using ^{123}I - or ^{131}I -metaiodobenzylguanidine in 61% and 39% of cases respectively.

Tumors were excised by different surgical groups in and out-of our center using open or more frequently laparoscopic surgery. No death occurred. All patients were at least re-examined within 3 mo postoperatively but no specific long-term follow-up was organized. Sixty three percent of patients became normotensive following surgery and their antihypertensive medication was withdrawn while 33% of patients were improved and required a smaller dose of antihypertensive treatment to adequately control BP. Sixty-two formalin-fixed and paraffin-embedded samples of excised pheochromocytomas were retrospectively reviewed in an independent blind way by two experts to determine the Pheochromocytoma of the Adrenal gland Scale Score (PASS) (11). In case of disagreement, the samples were mutually examined to reach a consensus agreement.

Metanephrines and catecholamines measurement

Fractionated urinary metanephrines, free urinary catecholamines and free plasma metanephrines were assayed by electrochemical detection (12). Intra-assay and interassay coefficients of variations were lower than 9.5%. Analyte concentrations were expressed in their fold increase above their respective upper limits of reference interval.

RNA extraction and quantitative PCR analysis

Total RNA was extracted from frozen excised pheochromocytomas samples using the TRI Reagent® (Sigma-Aldrich) and further purified with the miRNeasy Mini Kit (Qiagen) following the manufacturer's instructions. Total RNA (0.5 µg) was reverse transcribed in triplicates with 0.5 µg random primers using the ImProm II Reverse Transcription System for RT-PCR (Promega). Q-PCR was performed using the SYBR Green I Master Mix buffer (Applied Biosystems) in 96-wells plates on a 7900 HT Fast Real-Time PCR System. Information on the primers used, including sequences, concentration, amplicon sizes, and PCR efficiencies, is given in the supplementary Table. All Q-PCRs were done in duplicates. A series of 6 housekeeping genes and the multiple stable genes comparison program geNorm (13) were used for normalization. Presented are the resulting normalized expression levels of the genes of interest.

Protein extraction and Western blot analysis

Protein recovery from TRI Reagent® was performed with the following modifications: 2.5 volumes of isopropanol were added to the phenol-ethanol supernatant, protein pellet was washed twice in 0.3 M guanidine hydrochloride-95% ethanol, and re-suspended in 200–400 µL of 10 mM DTT and 8 M Urea solution. Total protein extracts (40 µg) were resolved by SDS-PAGE on 8% polyacrylamide gels and transferred onto nitrocellulose membranes (LI-COR Biosciences). After 30 min incubation in the Odyssey® blocking buffer, membranes were incubated overnight at 4 C with rabbit polyclonal anti-PNMT (1:1000) (14) or anti-EM66 (1:1500) (15) primary antibodies in 50% Odyssey® blocking buffer plus 0.01% Tween 20 in PBS. The secondary antibody used was the IRDye® 800CW donkey antirabbit IgG (1:10000; LI-COR Biosciences). A second gel loaded in parallel with similar protein amounts was stained with Coomassie blue according to the manufacturer's instructions (Simply Blue Safestain, Invitrogen) for normalization of PNMT and EM66 expression. Immunoreactive and Coomassie blue-stained bands were visualized on the Odyssey® Infrared imaging system and protein expression evaluated by densitometry using the ImageJ software (16).

Statistical analysis

Data are presented as mean ± SEM. One way ANOVA with nonparametric Kruskal-Wallis, Mann-Whitney-Wilcoxon and χ^2 tests were used to compare results among groups. Relationships between variables were evaluated by Spearman's rank correlation coefficients. Data were explored using Prism 5 (Graph-Pad, San Diego, CA). Statistical significance was considered when $P < .05$.

Results

Clinical features (Table 1)

Age and sex ratio of NIP and HP patients were similar. Aside from marked differences in hemodynamic features, the prevalence of diabetes was increased in HP patients compared to NIP patients. Tumor size and prevalence of positive uptake at MIBG scintigraphy were similar be-

Table 1. Clinical and radiological characteristics of patients with pheochromocytomas

	HP	NIP	Level of significance
Patients (number)	75	21	
Age at diagnosis (yr)	55 ± 1.6	51 ± 3.1	$P = 0.16$
Sex ratio (H/F)	34/41	5/16	$P = 0.09$
Systolic blood pressure (mmHg)	139 ± 2	126 ± 3	$P = 0.01$
Diastolic blood pressure (mmHg)	81 ± 1	72 ± 1	$P < 0.001$
Nb of anti-hypertensive treatments	1.6 ± 0.1	0 ± 0	$P < 0.001$
Hypotension (%)	7 (9%)	1 (5%)	$P = 0.681$
Resistant hypertension (%)	15 (20%)	0 (0%)	$P < 0.04$
Classic triad (%)	24 (32%)	0 (0%)	$P < 0.001$
Diabetes (%)	33 (44%)	3 (14%)	$P = 0.02$
Tumor size (mm)	50 ± 2.8	52 ± 6.7	$P = 0.781$
Tumor side (left/right)	31/39	9/11	$P = 1,000$
Positive MIBG scintigraphy	49/54	10/10	$P = 1,000$

tween groups. No uptake outside the adrenal tumor was found.

In vivo biological features (Table 2 and 3)

The 24h total output of urinary metanephrines (sum of methyl dopamine, methyl noradrenaline (urMNAD) and methyladrenaline (urMAD)) and urinary free catecholamines (sum of free dopamine, noradrenaline and adrenaline) were significantly lower in NIP compared to HP. Dopamine and methyl dopamine excretion was similar between groups. urMNAD was decreased in NIP while a similar but nonsignificant trends was found for plasma MNAD. All parameters reflecting adrenaline secretion were dramatically decreased in NIP compared to HP with a 5 to 6 fold decrease in the levels of urMAD, plasma MAD and urinary free adrenaline.

Tumor diameter of HP was correlated with urMNAD ($r = 0.71$, $P < .0001$), urMAD ($r = 0.37$; $P < .03$), plasma MNAD ($r = 0.71$; $P < .0001$), plasma MAD ($r = 0.31$; $P = .08$) and total amount of urinary metanephrines ($r = 0.62$; $P < .0001$). No correlation was found between size and any biochemical parameter in the NIP group.

Thus, NIP exhibited a different biochemical phenotype from HP that was characterized by a global reduction of catecholamine and metanephrine secretion and, more specifically, a reduced secretion of adrenaline and metadrenaline. A detailed description of the characteristics of NIP patients is provided in Table 2. From a diagnostic per-

Table 2. Biochemical investigations in patients with pheochromocytomas

	HP	NIP	Level of significance
ur MAD+MNAD+MDA	25.8 ± 3.9	8.5 ± 1.9	$P < 0.001$
ur MAD	20.2 ± 3.6	3.5 ± 0.8	$P < 0.001$
ur MNAD	7.2 ± 1.0	3.6 ± 0.8	$P < 0.040$
ur MDA	0.8 ± 0.1	0.6 ± 0.1	$P = 0.431$
pl MAD	11.3 ± 2.3	2.2 ± 0.6	$P < 0.001$
pl MNAD	10.1 ± 2.2	5.0 ± 0.9	$P = 0.328$
ur AD+NAD+DA	12.8 ± 2.3	4.4 ± 0.6	$P < 0,003$
ur AD	10.2 ± 2.4	1.7 ± 0.3	$P < 0.001$
ur NAD	3.6 ± 0.6	2.1 ± 0.4	$P = 0.309$
ur DA	0.7 ± 0.1	0.9 ± 0.3	$P = 0.688$

Table 3. Characteristics of patients with normotensive incidentally discovered pheochromocytomas (NIP)

Patient	Age (y)	Indication for imaging study	Tumor Size/Side	MIBG	pNMAD	pMAD	uNMAD	uMAD	uMDA	uNAD	uAD	uDA
1	43	Abdominal pain	160/R	NP	0.6	NP	0.3	0.3	NP	0.3	0.7	NP
2	25	Post-partum imaging	52/R	NP	NP	NP	0.8	1.5	NP	0.3	0.4	0.6
3	39	Workup for diabetes	66/R	NP	1.1	0.7	0.8	0.5	0.3	1.1	0.5	0.7
4	61	Abdominal pain	46/R	+	3.9	12.7	2.4	22.2	1.9	0.9	9.3	0.4
5	43	Diarrhea	84/R	NP	0.8	0.7	0.4	0.2	NP	0.4	0.3	NP
6	55	Followup breast cancer	39/liter	+	NP	NP	11.4	2.1	0.6	5.9	2.6	0.6
7	57	Workup for diabetes	36/R	+	9.9	9.7	6.7	17.2	1.1	2.4	7.4	0.9
8	64	Abdominal Pain	37/liter	NP	NP	NP	1.4	1.1	NP	0.7	0.6	8.7
9	84	Diarrhea	44/liter	NP	15	0.9	4.6	0.7	0.3	2.6	0.2	0.3
10	34	Chest Pain	38/R	+	NP	NP	2.4	8.9	0.4	0.8	2.8	0.8
11	57	Diarrhea	59/liter	NP	NP	NP	0.6	6.1	0.2	0.9	1.4	0.5
12	37	Rib fracture	60/R	NP	NP	NP	2.2	9.2	NP	0.4	2.4	0.5
13	45	Chronic hyperthermia	32/R	+	1.6	1.2	0.7	1.1	NP	0.2	0.5	NP
14	58	Abdominal pain	76/R	NP	NP	NP	2	5.3	NP	1.2	3.9	0.3
15	38	Abdominal pain	25/liter	+	NP	NP	0.87	1.8	NP	0.7	1.2	NP
16	56	Workup for diabetes	35/liter	+	9.6	0.7	4.1	0.4	0.6	8.2	0.5	0.9
17	50	Asthenia	36/R	NP	3.5	3.3	1.9	5.3	0.4	1	2.9	0.6
18	55	Asthenia	28/liter	+	1	6	1	5.2	0.3	0.2	1.7	0.4
19	50	Chronic hyperthermia	65/liter	NP	5.5	0.7	6	0.4	1	3.8	0.3	1.1
20	79	Abdominal pain	53/R	+	NP	0.7	19.9	0.6	0.6	0.9	0.3	0.3
21	44	Appendicitis	30/liter	+	6	0.7	NP	NP	NP	2.7	NP	NP

spective, the combined determination of urinary metanephrines displayed 98% sensitivity in the HP group and only 75% in the NIP group ($P < .001$). The combined determination of plasma metanephrines exhibited 100% sensitivity in the HP and 81% in the NIP group ($P = .08$). The sensitivity of the combined determination of urinary free catecholamines was 88% in the HP group and 62% in the NIP group ($P < .02$).

Histopathological features

Analysis of surgical reports and examination of the gross anatomy identified one malignant case among HP presenting with local invasion of surrounding tissues, which was excluded from in vitro studies. All other patients had normal biochemistry and CT scan at the short-term postoperative evaluation.

48 HP and 14 NIP were histologically analyzed using the PASS score. Despite low absolute PASS, the mean score was increased in NIP compared to HP (5.6 ± 0.5 vs $3.9 \pm$

0.3 , $P < .01$). Among the score's items, NIP exhibited increased cellularity ($P < .01$) and number of mitosis ($P = .07$), and displayed atypical mitosis ($P < .02$) compared to HP (Figure 1).

Chromaffin cell gene and protein expression (Table 4)

29 frozen pheochromocytoma samples were available for molecular analysis (17 HP and 12 NIP). Among the 16 relevant genes analyzed, the transcript levels of 5 genes were significantly lower in NIP compared to HP i.e., phenylethanolamine N-methyltransferase (PNMT), secretogranin II (SGII), vesicular monoamine transporter type 1 (VMAT1), norepinephrine transporter (NET) and neuropeptide Y (NPY). There was also a strong but nonsignificant trend towards lower expression of tyrosine hydroxylase (TH). In fact, several transcripts appeared to be down-regulated in NIP with ~80% of the analyzed genes

(13 over 16) having lowest expression within the NIP group.

PNMT protein expression was quantified in 10 HP and

7 NIP (Figure 2A). The protein was undetectable in 71% of NIP (5 over 7) but in only 30% of HP (3 over 10). Quantification of signals confirmed the substantial ex-

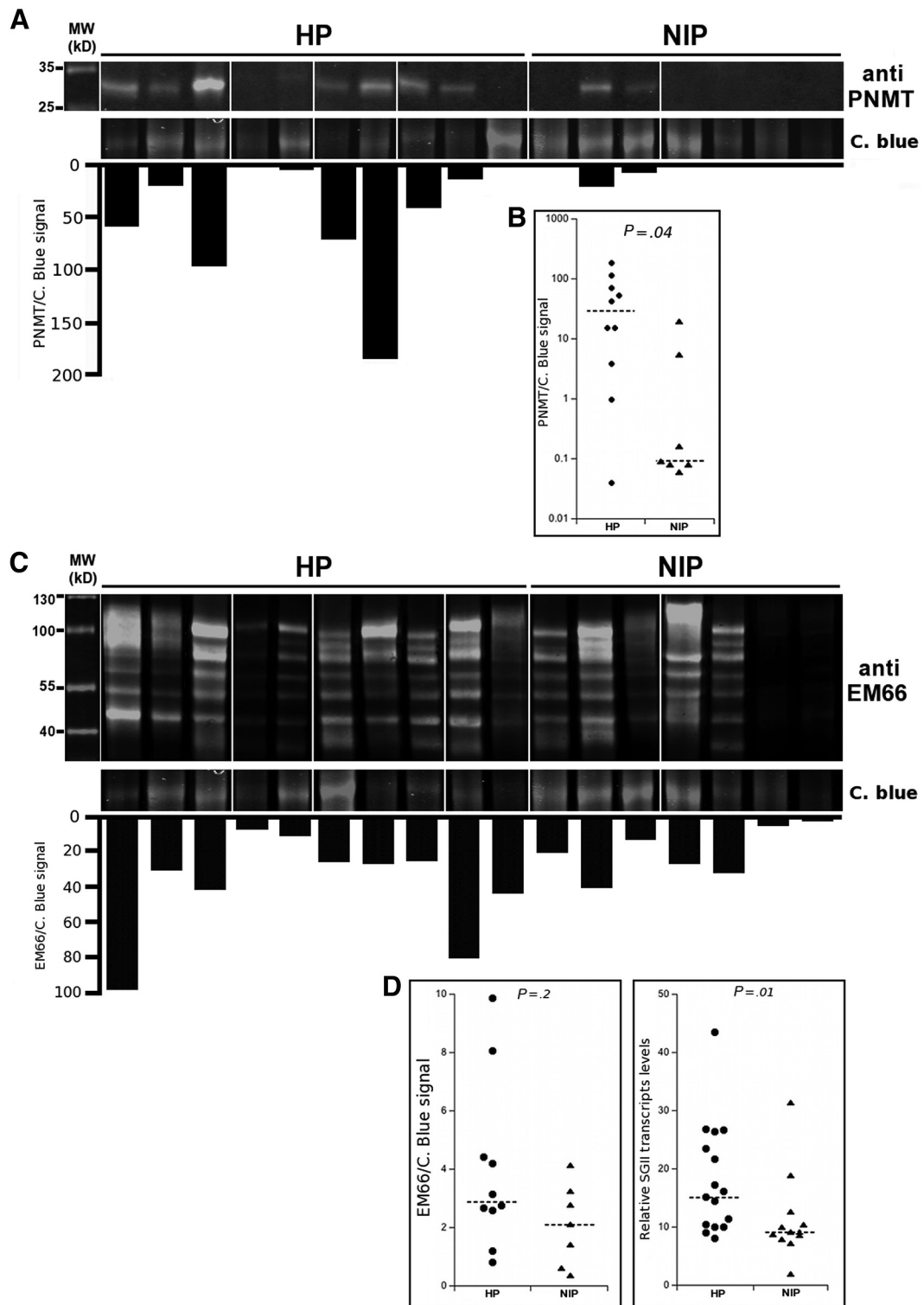


Figure 1. Analysis of PNMT and Secretogranin II protein expression in pheochromocytoma tissue samples. (2A and 2C) Western blot analysis of total protein extracts from frozen tissue samples of 10 hypertensive pheochromocytomas (HP) and 7 normotensive incidental pheochromocytomas (NIP), using an anti-PNMT antibody (2A) or an anti-EM66 antibody that recognizes all EM66 epitope-containing proteolytic processing products of SgII (2C). Coomassie blue (C. blue) staining served as a loading control. The normalized quantification of PNMT or SgII signal is displayed as an inverted histogram. (2B and 2D) PNMT protein (n = 17, 2B), SgII protein (n = 17, 2D, left panel) and mRNA (n = 28, 2D, right panel) levels were plotted as scattergrams for statistical analyses.

Table 4. Catecholamines metabolism genes expression in pheochromocytomas tissues samples

Symbol	HP (n = 16)	NIP (n = 12)	Level of Significance
Catecholamines synthesis			
DBH	22.9	22.2	$P = 0.32$
PNMT *	87.3	11.5	$P = 0.05$
TH *	10.2	6.3	$P = 0.08$
Granins			
CGA *	13.0	8.1	$P = 0.51$
CGB *	11.2	5.4	$P = 0.64$
SGII *	15.6	9.2	$P = 0.01$
Catecholamines catabolism			
COMT *	21.3	18.9	$P = 0.26$
MAOA	6.8	8.9	$P = 1.00$
Catecholamines transport			
VMAT1 *	28.2	14.7	$P = 0.04$
VMAT2 *	85.2	78.0	$P = 0.21$
NET *	20.6	8.9	$P = 0.04$
Peptides/maturation/secretion			
NPY *	87.7	33.1	$P = 0.02$
PAM *	18.6	15.0	$P = 0.35$
PC1 *	115.6	90.0	$P = 0.34$
PC2 *	12.4	6.0	$P = 0.09$
SNAP25	15.9	15.6	$P = 0.63$

pression deficiency of PNMT protein in NIP compared to HP ($P < .04$) (Figure 2B). Moreover, the positive correlation between PNMT transcript and protein levels ($r = 0.8, P < .001$) suggested that PNMT protein deficiency in NIP results from a decrease in its gene transcription. PNMT gene expression in the 28 tumor samples analyzed also correlated with the uMAD/(uMAD + uNMAD) ratio ($r = 0.6, P < .001$; figure 3B) suggesting that the reduced expression of the enzyme is responsible for a decreased conversion of noradrenaline to adrenaline that ultimately results in relatively low in vivo levels of adrenaline metabolites in NIP patients. In line with the decrease of SGII

transcripts in NIP, western blot quantification revealed a decrease in the SGII protein in NIP compared to HP ($P = .02$) (Figure 2C and D).

Discussion

The increasing occurrence of incidental pheochromocytomas is well acknowledged and represents more than 25% of pheochromocytomas recruited in medical or surgical centers during recent decades (5–9, 17). Although an accurate evaluation of BP using 24 h ambulatory recording in incidental pheochromocytomas remains to be reported, absence of hypertension has been reported in 13.5% (7), 37.5% (8), 45% (18) and 55% (9) of incidental pheochromocytoma series. Despite the frequency of this hemodynamically silent presentation, only scarce information on the characteristics of NIP is currently available.

Our retrospective study was conducted mainly in a single institution, which, by design, has inherent limitations. Since most of patients were recruited in a department of endocrinology considered locally as a tertiary care structure for the evaluation of adrenal incidentalomas, it is likely that selection bias enriched the cohort in incidental pheochromocytomas and NIP. Since germinal genetic alterations responsible for the development of pheochromocytoma may result in specific biochemical in vivo phenotypes (19–21), patients with indirect or direct evidence of a genetic disease were excluded from the study. However we cannot rule out the possibility that other rare genetic predisposition for pheochromocytomas may influence our findings (22). Patients were operated in different centers and no systematic long-term follow-up strategy was organized hampering any comparison in recurrence

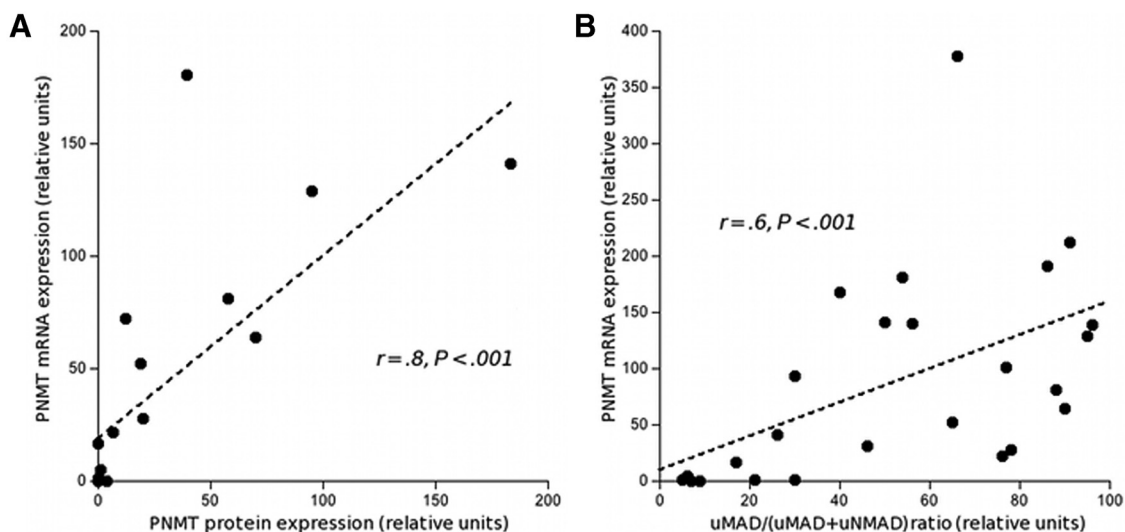


Figure 2. Correlations between PNMT gene and protein expression and catecholamine metabolism. Scatter plot and statistical analysis of the relationship between PNMT protein and mRNA levels (3A), or between PNMT mRNA levels and the uMAD/(uMAD + uNMAD) ratio (3B).

between patient groups. Despite these limitations, our study is the first to examine thoroughly the clinical, biochemical and pathological characteristics of a large series of NIP, and to link them to differences in cellular and molecular features of the tumors.

What are the reasons for the silent presentation of NIP? Molecular investigations revealed a significant down-regulation of 5 genes and 2 of the corresponding proteins involved in key processes of catecholamine metabolism in NIP compared to HP. These findings suggest that specific molecular defects in the chromaffin cellular machinery account for the peculiar biochemical and clinical phenotype of NIP. The amount and pattern of the catecholamines secreted usually account for hemodynamic features of patients with pheochromocytomas, low amounts of circulating catecholamines and intermittent release being associated with a weak clinical expression (2, 23). The reversal of hemodynamic features following tumor removal in most of HP patients of our series is also consistent with a pathophysiological relationship between tumor secretion and clinical manifestations. Thus, the reduced global output of catecholamines in NIP is likely to account, at least partly, for their clinical silence. Similar but incomplete observations have been reported in incidental pheochromocytomas for lower circulating catecholamines (5), urinary catecholamines and VMA (9) or an heterogeneous “hormone ratio” (6) without any attempt to correlate molecular data, biochemistry and clinical manifestations. The enzyme TH is rate-limiting in catecholamine synthesis and the trend towards its down-regulation in NIP may account for the lower global output of catecholamines. We did not assess differences in cosecretion of peptides that may have a reinforcing or attenuating hemodynamic impact (3). However, the relatively low expression of NPY mRNA in NIP may also be in part responsible for their silent phenotype, since NPY is a potent hypertensive peptide (2, 24). Besides, the lower prevalence of diabetes in NIP patients is consistent with a reduced hypersecretion of catecholamines (25).

Apart from the magnitude of secretion, the nature of circulating catecholamines may also explain differences in clinical symptoms. Dopamine-induced vasodilatation is unlikely to account for differences in clinical presentation since urinary excretion of dopamine was equivalent between groups. Due to the different potencies of adrenaline and noradrenaline on α - and β -adrenoceptors, patients with adrenaline-secreting pheochromocytomas present with more severe hypertension and paroxysmal hemodynamic symptoms compared to noradrenaline-secreting pheochromocytomas (19, 23, 26). NIP were characterized by plasma and urinary levels of adrenaline and metadrenaline that were 5 to 6 fold lower than those of HP. This

feature, associated to a relatively low output of noradrenaline is likely to account for the lack of hypertension in NIP patients. Urinary and plasma metanephrines have been shown to accurately reflect tumor catecholamines content (27). We found positive correlations between PNMT mRNA levels and PNMT protein on the one hand and between PNMT mRNA levels and the *in vivo* uMAD/(uMAD + uNMAD) ratio on the other hand. These findings suggest that the 7 fold reduction in PNMT mRNA levels that results in reduced PNMT protein in NIP compared to HP leads to a reduced synthesis of adrenaline and MAD. Of note, the reduced NPY gene expression found in NIP is consistent with its specific expression in adrenomedullary PNMT-expressing cells and its decrease in noradrenergic as compared to adrenergic pheochromocytomas (28). Low production of adrenaline, together with a relatively low output of noradrenaline is likely to account for the lack of hypertension in NIP patients.

The amount of catecholamines and metanephrines released by HP were positively correlated with their size, as reported previously (27). Such correlation was absent in NIP that were equivalent in size to HP. This observation suggests that NIP do not represent an early stage of development of pheochromocytomas but rather correspond to a distinct entity characterized by cellular defects in chromaffin machinery. We also found in NIP a lower expression of genes coding for NET and VMAT1 responsible for storage of catecholamines via cellular uptake and vesicular translocation, and a lower mRNA and protein expression of SGII, a component of dense-core secretory granules. These additional alterations of key determinants of chromaffin cell function suggests that, apart from impaired synthesis, catecholamine storage and release may also be altered in NIP and participate to the reduced output of metanephrines. Further studies including direct measurement of intra-tumoral catecholamines are needed to elucidate this point (19, 29)

Interestingly, detailed histological examination of NIP revealed a significant increase in the cellularity (i.e., small cytoplasm of tumoral cells), a finding that is consistent with a reduction of the cellular machinery, and also a rise in the mitotic activity as well as the presence of atypical mitosis, e.g., features that are usually associated with malignancy. Moreover, the molecular signature of NIP corresponds to a global down-regulation (~80%) of the expression of genes that represent essential features of neuroendocrine differentiation and chromaffin cell phenotype. Altogether, these observations suggest that NIP represent a distinct entity from HP corresponding to a specific molecular determinism or cellular origin (20, 30), in which the neuroendocrine attributes of adrenal pheochromocytomas are altered, resulting in lower efficiency

to produce or release catecholamines. Such altered phenotype of chromaffin cells has been reported in studies comparing subtypes of pheochromocytomas, based upon their benign or malignant status (31) and also in patients with SDHB mutations that have a propensity to become malignant (32). Examination of surgical reports and short-term postoperative evaluation did not identify any case of malignancy among NIP but in the absence of a standardized follow-up procedure, a number of our patients of this series were lost of sight after a few years. In a recent study incidental discovery was not found to be associated with an increased rate of recurrence but distinction between NIP and incidentally discovered pheochromocytomas with hypertension was not performed (5). Further studies should be undertaken to clarify this issue. An integrative genomic analysis assessing the critical genetic and molecular features of NIP would provide unique insights in the differentiation processes of chromaffin tumors (30).

The peculiar molecular and biochemical phenotype of NIP had an obvious deleterious influence on the diagnostic power of fractionated urinary or plasma free metanephrine measurement (1, 33). In contrast to the excellent performance found in hypertensive patients of our series regardless of the mode of discovery of the tumor, the sensitivity of these markers were reduced to 75% in NIP. Systematic measurement of metanephrines in each patient affected by an adrenal incidentaloma has been recommended (34–36). However, clinicians should be aware that these tools can erroneously ignore a NIP in approximately 25% of cases and it is of crucial importance to consider that pheochromocytomas may harbor the presentation of an incidentaloma with normal BP and normal values of metanephrines, a situation that has been rarely emphasized. In such instance, the CT scan characteristics of the incidentaloma should alert the clinician (37) and complementary investigations such as plasma chromogranin A measurement, MIBG scintigraphy, 18FDG-PET or alternative functional imaging procedures (1, 33, 38) should be performed to rule out a pheochromocytoma. This work-up is of paramount importance in patients scheduled for surgery of the incidentaloma in order to prevent and manage intra-operative hemodynamic instability (3, 33, 39).

In conclusion, NIP display a peculiar phenotype from clinical, biochemical, histological and molecular perspectives. Clinicians should also be aware of the peculiar presentation of NIP that is associated with a decreased diagnostic performance of metanephrine measurement. Increased medical alertness is therefore recommended during the evaluation of atypical adrenal incidentalomas despite normal BP and a negative history of paroxysms.

Further studies are needed to evaluate the long-term prognosis of operated NIP and the etiopathogeny of these peculiar pheochromocytomas.

Acknowledgments

we are indebted to the tumorothèque of the university hospital of Bordeaux for handling the tumor specimen.

Address all correspondence and requests for reprints to: Pr Antoine Tabarin, Department of Endocrinology, Haut Leveque Hospital, Avenue de Magellan, 33604 Pessac, France. E-mail: antoine.tabarin@chu-bordeaux.fr.

Disclosure Summary: The authors have nothing to disclose. This work was supported by .

References

1. Lenders JW, Eisenhofer G, Mannelli M, Pacak K. *Pheochromocytoma*. *Lancet*. 2005;366:665–675.
2. Bravo EL, Tagle R. Pheochromocytoma: state-of-the-art and future prospects. *Endocrine reviews*. 2003;24:539–553.
3. Mannelli M, Lenders JW, Pacak K, Parenti G, Eisenhofer G. Subclinical pheochromocytoma. *Best Pract Res Clin Endocrinol Metab*. 2012;26:507–515.
4. Cawood TJ, Hunt PJ, O'Shea D, Cole D, Soule S. Recommended evaluation of adrenal incidentalomas is costly, has high false-positive rates and confers a risk of fatal cancer that is similar to the risk of the adrenal lesion becoming malignant; time for a rethink? *European journal of endocrinology / European Federation of Endocrine Societies*. 2009;161:513–527.
5. Amar L, Servais A, Gimenez-Roqueplo AP, Zinzindohoue F, Chetailier G, Plouin PF. Year of diagnosis, features at presentation, and risk of recurrence in patients with pheochromocytoma or secreting paraganglioma. *The Journal of clinical endocrinology and metabolism*. 2005;90:2110–2116.
6. Guerrero MA, Schreinemakers JM, Vriens MR, Suh I, Hwang J, Shen WT, Gosnell J, Clark OH, Duh QY. Clinical spectrum of pheochromocytoma. *Journal of the American College of Surgeons*. 2009;209:727–732.
7. Kopetschke R, Slisko M, Kilisli A, Tuschy U, Wallaschofski H, Fassnacht M, Ventz M, Beuschlein F, Reincke M, Reisch N, Quinkler M. Frequent incidental discovery of pheochromocytoma: data from a German cohort of 201 pheochromocytoma. *European journal of endocrinology / European Federation of Endocrine Societies*. 2009;161:355–361.
8. Mannelli M, Ianni L, Cilotti A, Conti A. Pheochromocytoma in Italy: a multicentric retrospective study. *European journal of endocrinology / European Federation of Endocrine Societies*. 1999;141:619–624.
9. Noshiro T, Shimizu K, Watanabe T, Akama H, Shibukawa S, Miura W, Ito S, Miura Y. Changes in clinical features and long-term prognosis in patients with pheochromocytoma. *American journal of hypertension*. 2000;13:35–43.
10. Pigny P, Cardot-Bauters C, Do Cao C, Vantyghe MC, Carnaille B, Pattou F, Caron P, Wemeau JL, Porchet N. Should genetic testing be performed in each patient with sporadic pheochromocytoma at presentation? *European journal of endocrinology / European Federation of Endocrine Societies*. 2009;160:227–231.
11. Thompson LD. Pheochromocytoma of the Adrenal gland Scaled Score (PASS) to separate benign from malignant neoplasms: a clin-

- icopathologic and immunophenotypic study of 100 cases. *The American journal of surgical pathology*. 2002;26:551–566.
12. Gardet V, Gatta B, Simonnet G, Tabarin A, Chene G, Ducassou D, Corcuff JB. Lessons from an unpleasant surprise: a biochemical strategy for the diagnosis of pheochromocytoma. *Journal of hypertension*. 2001;19:1029–1035.
 13. Vandesompele J, De Preter K, Pattyn F, Poppe B, Van Roy N, De Paepe A, Speleman F. Accurate normalization of real-time quantitative RT-PCR data by geometric averaging of multiple internal control genes. *Genome Biol*. 2002;3:RESEARCH0034.
 14. Tillet Y. Adrenergic neurons in sheep brain demonstrated by immunohistochemistry with antibodies to phenylethanolamine N-methyltransferase (PNMT) and dopamine-beta-hydroxylase (DBH): absence of the C1 cell group in the sheep brain. *Neurosci Lett*. 1988;95:107–112.
 15. Anouar Y, Yon L, Desmoucelles C, Leprince J, Breault L, Gallo-Payet N, Vaudry H. Identification of a novel secretogranin II-derived peptide in the adult and fetal human adrenal gland. *Endocr Res*. 1998;24:731–736.
 16. Abramoff MD, Magelhaes PJ, Ram SJ. Image Processing with ImageJ. *Biophotonics International*. 2004;11:36–42.
 17. Lee JA, Zarnegar R, Shen WT, Kebebew E, Clark OH, Duh QY. Adrenal incidentaloma, borderline elevations of urine or plasma metanephrine levels, and the “subclinical” pheochromocytoma. *Arch Surg*. 2007;142:870–873; discussion 873–874.
 18. Mantero F, Terzolo M, Arnaldi G, Osella G, Masini AM, Ali A, Giovagnetti M, Opocher G, Angeli A. A survey on adrenal incidentaloma in Italy. Study Group on Adrenal Tumors of the Italian Society of Endocrinology. *The Journal of clinical endocrinology and metabolism*. 2000;85:637–644.
 19. Eisenhofer G, Huynh TT, Elkhoulou A, Morris JC, Bratslavsky G, Linehan WM, Zhuang Z, Balgley BM, Lee CS, Mannelli M, Lenders JW, Bornstein SR, Pacak K. Differential expression of the regulated catecholamine secretory pathway in different hereditary forms of pheochromocytoma. *Am J Physiol Endocrinol Metab*. 2008;295:E1223–E1233.
 20. Eisenhofer G, Pacak K, Huynh TT, Qin N, Bratslavsky G, Linehan WM, Mannelli M, Friberg P, Grebe SK, Timmers HJ, Bornstein SR, Lenders JW. Catecholamine metabolomic and secretory phenotypes in pheochromocytoma. *Endocrine-related cancer*. 2011;18:97–111.
 21. Eisenhofer G, Walther MM, Huynh TT, Li ST, Bornstein SR, Vortmeyer A, Mannelli M, Goldstein DS, Linehan WM, Lenders JW, Pacak K. Pheochromocytomas in von Hippel-Lindau syndrome and multiple endocrine neoplasia type 2 display distinct biochemical and clinical phenotypes. *J Clin Endocrinol Metab*. 2001;86:1999–2008.
 22. Gimenez-Roqueplo AP, Dahia PL, Robledo M. An update on the genetics of paraganglioma, pheochromocytoma, and associated hereditary syndromes. *Hormone and metabolic research = Hormon- und Stoffwechselforschung = Hormones et metabolisme*. 2012;44:328–333.
 23. Zuber SM, Kantorovich V, Pacak K. Hypertension in pheochromocytoma: characteristics and treatment. *Endocrinol Metab Clin North Am*. 2011;40:295–311.
 24. Tabarin A, Minot AP, Dallochio M, Roger P, Ducassou D. Plasma concentration of neuropeptide Y in patients with adrenal hypertension. *Regulatory peptides*. 1992;42:51–61.
 25. Stenstrom G, Sjostrom L, Smith U. Diabetes mellitus in pheochromocytoma. Fasting blood glucose levels before and after surgery in 60 patients with pheochromocytoma. *Acta endocrinologica*. 1984;106:511–515.
 26. Ito Y, Fujimoto Y, Obara T. The role of epinephrine, norepinephrine, and dopamine in blood pressure disturbances in patients with pheochromocytoma. *World J Surg*. 1992;16:759–764.
 27. Eisenhofer G, Lenders JW, Goldstein DS, Mannelli M, Csako G, Walther MM, Brouwers FM, Pacak K. Pheochromocytoma catecholamine phenotypes and prediction of tumor size and location by use of plasma free metanephrines. *Clinical chemistry*. 2005;51:735–744.
 28. Cleary S, Phillips JK, Huynh TT, Pacak K, Elkhoulou AG, Barb J, Worrell RA, Goldstein DS, Eisenhofer G. Neuropeptide Y expression in pheochromocytomas: relative absence in tumours from patients with von Hippel-Lindau syndrome. *J Endocrinol*. 2007;193:225–233.
 29. Huynh TT, Pacak K, Brouwers FM, Abu-Asab MS, Worrell RA, Walther MM, Elkhoulou AG, Goldstein DS, Cleary S, Eisenhofer G. Different expression of catecholamine transporters in pheochromocytomas from patients with von Hippel-Lindau syndrome and multiple endocrine neoplasia type 2. *Eur J Endocrinol*. 2005;153:551–563.
 30. Burnichon N, Vescovo L, Amar L, Libe R, de Reynies A, Venisse A, Jouanno E, Laurendeau I, Parfait B, Bertherat J, Plouin PF, Jeunemaitre X, Favier J, Gimenez-Roqueplo AP. Integrative genomic analysis reveals somatic mutations in pheochromocytoma and paraganglioma. *Human molecular genetics*. 2011;20:3974–3985.
 31. Thouennon E, Elkhoulou AG, Guillemot J, Gimenez-Roqueplo AP, Bertherat J, Pierre A, Ghzili H, Grumolato L, Muresan M, Klein M, Lefebvre H, Ouafik L, Vaudry H, Plouin PF, Yon L, Anouar Y. Identification of potential gene markers and insights into the pathophysiology of pheochromocytoma malignancy. *J Clin Endocrinol Metab*. 2007;92:4865–4872.
 32. Timmers HJ, Kozupa A, Eisenhofer G, Raygada M, Adams KT, Solis D, Lenders JW, Pacak K. Clinical presentations, biochemical phenotypes, and genotype-phenotype correlations in patients with succinate dehydrogenase subunit B-associated pheochromocytomas and paragangliomas. *The Journal of clinical endocrinology and metabolism*. 2007;92:779–786.
 33. Pacak K, Eisenhofer G, Ahlman H, Bornstein SR, Gimenez-Roqueplo AP, Grossman AB, Kimura N, Mannelli M, McNicol AM, Tischler AS. Pheochromocytoma: recommendations for clinical practice from the First International Symposium. October 2005. *Nature clinical practice Endocrinology, metabolism*. 2007;3:92–102.
 34. Grumbach MM, Biller BM, Braunstein GD, Campbell KK, Carney JA, Godley PA, Harris EL, Lee JK, Oertel YC, Posner MC, Schlechte JA, Wieand HS. Management of the clinically inapparent adrenal mass (“incidentaloma”). *Annals of internal medicine*. 2003;138:424–429.
 35. Tabarin A, Bardet S, Bertherat J, Dupas B, Chabre O, Hamoir E, Laurent F, Tenenbaum F, Cazalda M, Lefebvre H, Valli N, Rohmer V. Exploration and management of adrenal incidentalomas. French Society of Endocrinology Consensus. *Annales d'endocrinologie*. 2008;69:487–500.
 36. Terzolo M, Stigliano A, Chiodini I, Loli P, Furlani L, Arnaldi G, Reimondo G, Pia A, Toscano V, Zini M, Borretta G, Papini E, Garofalo P, Allolio B, Dupas B, Mantero F, Tabarin A. AME position statement on adrenal incidentaloma. *European journal of endocrinology / European Federation of Endocrine Societies*. 2011;164:851–870.
 37. Motta-Ramirez GA, Remer EM, Herts BR, Gill IS, Hamrahian AH. Comparison of CT findings in symptomatic and incidentally discovered pheochromocytomas. *AJR American journal of roentgenology*. 2005;185:684–688.
 38. Taieb D, Timmers HJ, Hindie E, Guillet BA, Neumann HP, Walz MK, Opocher G, de Herder WW, Boedeker CC, de Krijger RR, Chiti A, Al-Nahhas A, Pacak K, Rubello D. EANM 2012 guidelines for radionuclide imaging of pheochromocytoma and paraganglioma. *European journal of nuclear medicine and molecular imaging*. 2012;39:1977–1995.
 39. Shao Y, Chen R, Shen ZJ, Teng Y, Huang P, Rui WB, Xie X, Zhou WL. Preoperative alpha blockade for normotensive pheochromocytoma: is it necessary? *Journal of hypertension*. 2011;29:2429–2432.